
**ALVEOLA STORAGE FOR BUILDING OF DENTAL IMPLANTS WITH RESORBA®
DENTAL**

Biljana DodevskaPHI Clinical Hospital Stip, R. Macedonia, bdodevskaya@hotmail.com

Abstract: In this case report, the preservation of alveola before the implantation is used the product of Parasorb® Cone, a soft, stable collagen sponge for local hemostasis from RESORBA® Dental, and is a very clean preparation with the highest safety profiles. It can be used in almost all surgical disciplines for local haemostasis when bleeding from capillaries and organs, as well as in support of other methods of haemostasis. Due to the affordable price in terms of the standard of living of patients and the characteristics of the product itself, which is pleasant and suitable for manipulation, it was used in the preservation of the alveol before the implantation of dental implants in our patient. The preservation intervention, or complete preparation of the dental alveolate after extraction, was performed using Parasorb® Cone, from the Resorba® Dental, in a patient at the age of 46 years in 2015 by the D-r. Trajkovski A., Specialist in oral surgery, in Private Health Dental Institution "D-r. Aleksandar Trajkovski" - Skopje, R. Macedonia. In addition, with the incorporation of RESORBA® Detal Cone, it was possible to accelerate the wound healing after extraction of the existing part of the tooth. Also, the bone resorption of the ridge was also prevented, since the height and width of the alveolar ridge are important factors for further implantation. We used RESORBA® Dental to protect it from further loss, which is of particular importance in the subsequent implantation process of dental implants. For a short time after, the satisfaction of both, the patient and the surgeon as well, was ensured the stabilization of blood coagulum, at the shortest normal prothrombin time (the time for which the blood coagulum is formed). This collagen sponge with its preparation and structure, offers antibiotic protection of the alveolus, even in high-risk groups of patients (diabetics, smokers, and others). After completing the entire procedure, the implantation and use of the Parasorb® Cone product, we can conclude that the success of the future design is long-term and predictable.

Keywords: preservation, dental implants, Resorba® Dental.

1. INTRODUCTION

For the preservation of the alveol before the implantation of dental implants, in this case, the resin collagen sponge Parasorb® Cone from the manufacturer Resorba® Dental is used. It has a particular role in accelerating haemostasis and strengthening the coagulum, then preserving the dental ridge, as well as antibacterial properties. Available for use in almost all social categories of patients, but also in those in the group with high health disorders (diabetics, smokers, other ailments).

2. CASE REPORT

The intervention of the preservation of the alveol for implanting dental implants in a 46-year-old patient was performed by D-r. Specialist in oral surgery Aleksandar Trajkovski, in the premises of Private Dental Health Office "Aleksandar Trajkovski" - Skopje. After a very short time of tooth extraction, the proximal alveolar edge of adjacent teeth starts to lick and teeth tilt to the empty space. In this way, the height of the alveolus decreases, resulting in a reduction of the ridge. Preservation of the height and width of the alveolar ridge is of particular importance in the further procedure of dental implantation, for which the material of Resorba® Dental was used.

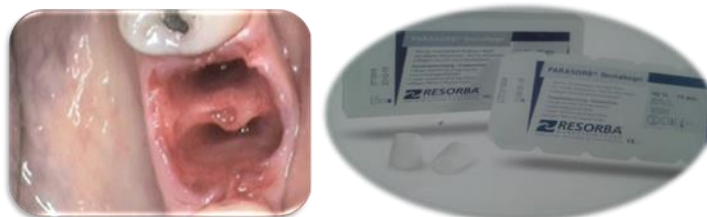

Fig. 1. Tooth extraction and use of Resorba® Dental for the preservation of the dental crest

This aloplastic material possesses extraordinarily good qualities, providing rapid hemostasis, prescribing atrophy and bone regeneration of the alveolar ridge. In doing so, it stabilizes blood coagulum and with its antibiotic protection prevents the risk of re-bleeding, even in high-risk patients (immunosuppressive therapy, diabetes,

smokers, COPD, etc.). Reduction of the atrophy of the alveolar ridge and the support of the vestibular lamina provide stabilization of the alveol and alveolar process, which ensures the preservation of aesthetic and functional results from a long-term perspective.^[1,2,6]

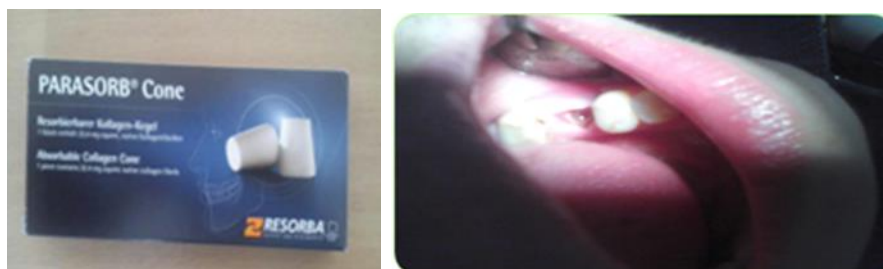

Fig. 2. Preservation of alveol with Parasorb® Cone

Subsequent interventions in the implant procedure, which are associated with an increase in the volume and height of the alveolar bone, are expensive and time-consuming, but not completely risky. Therefore, the simplicity of using Parasorb® Cone, as well as the acceptable price by patients, can be seen in subsequent surgical manipulation when successful bone regeneration ensures long-term success in the installation of dental implants.

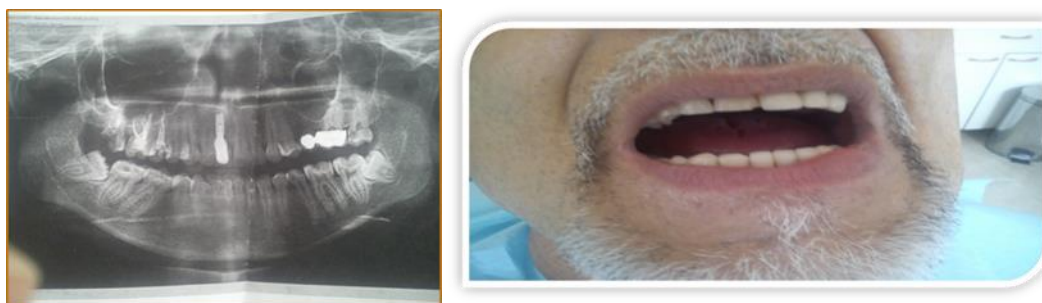


Fig. 3. Embedded dental implants

As for the subsequent post-extraction complications, in this case they were not recorded, and the height and width of the ridge were at a satisfactory level, and consequently the successful setting of enossal implants was followed.^[1,3,4,5]

3. CONCLUSION

With incorporating a RESORBA® Dental, the bone resorption of the ridge (its loss) is prevented, the ejection site rapidly heals, the stabilization of the blood coagulum (no bleeding), the predictable long-term success of the future construction, or the implantation of dental implants.

4. REFERENCES

- [1] Pilliar RM, Deporter DA, Watson PA, Valiquette N. Dental implant design--effect on bone remodeling. *J Biomed Mater Res.* 1991 Apr. 25(4):467-83.
- [2] Reese JA, Valega TM. *Restorative dental materials: an overview.* London: Quintessence Publishing; 1985.
- [3] Norton MR, Gamble C. Bone classification: an objective scale of bone density using the computerized tomography scan. *Clin Oral Implants Res.* 2001 Feb. 12(1):79-84.
- [4] Jacobs R, Quirynen M. Dental cone beam computed tomography: justification for use in planning oral implant placement. *Periodontology 2000.* 2014;66:203-13.
- [5] Jacobs R. Dental cone beam CT and its justified use in oral health care. *JBR-BTR.* 2011 Sep-Oct. 94(5):254-65.
- [6] Quereshy FA, Barnum G, Demko C, Horan M, Palomo JM, Baur DA. Use of cone beam computed tomography to volumetrically assess alveolar cleft defects--preliminary results. *J Oral Maxillofac Surg.* 2012 Jan. 70(1):188-91.