

IMPLANT WITH SIMULTANEOUS SINUS GRAFT

Female

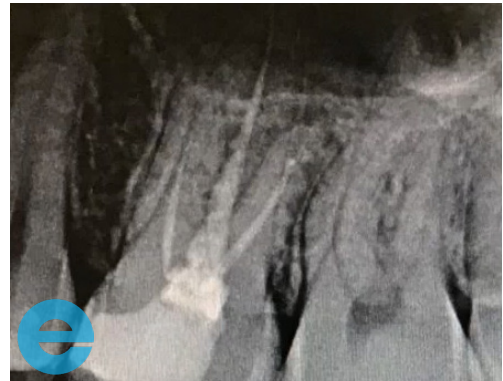34 years old

Persistent pain and buccal swelling UL6, issue with previous root canal treatment

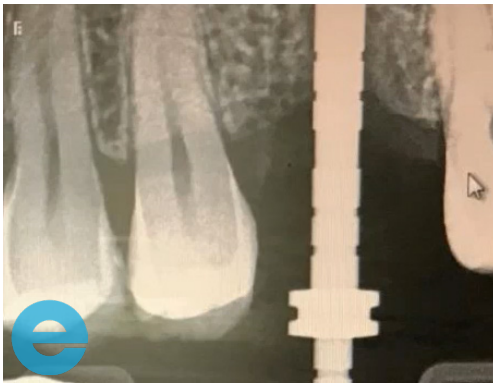MH clear, SH nil

Generally healthy dentition

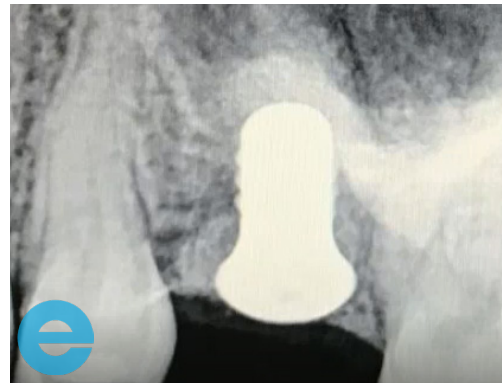
Case from Dr Andrew Fish, Jersey Channel Islands



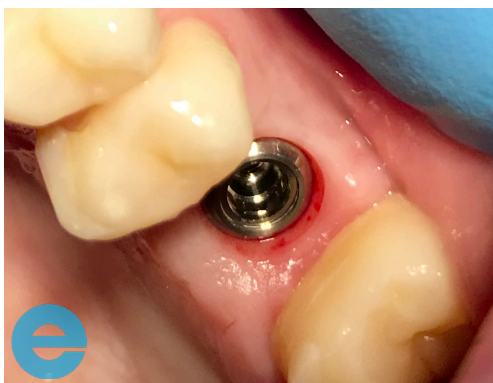1. Initial situation - issue with previous root canal treatment



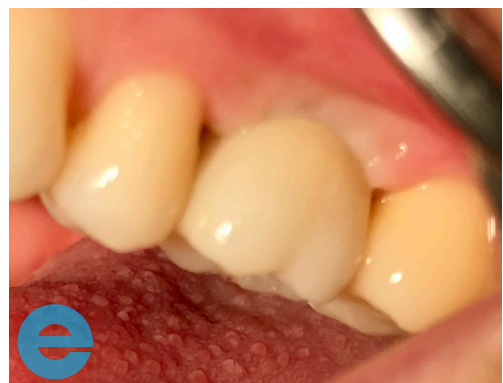2. 3 months following extraction



3. Implant placement with simultaneous closed sinus lift

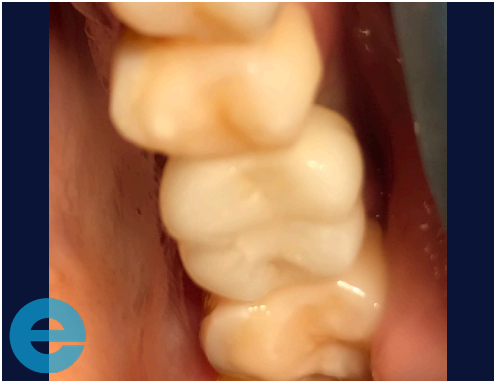

4. Loading at 12 weeks

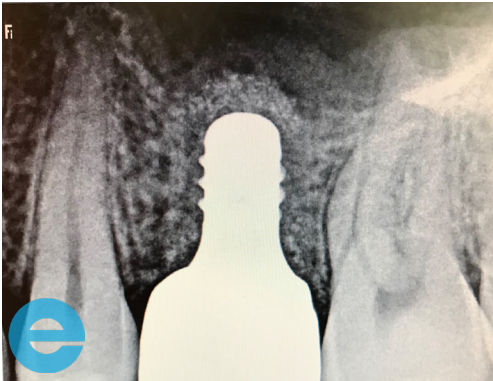

5. Loading at 12 weeks

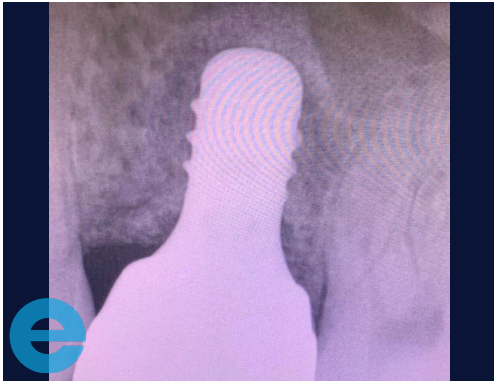IMPLANT WITH SIMULTANEOUS SINUS GRAFT



6. 6 months loaded



7. 6 months loaded



8. 3 years loaded



GROW STRONGER

USEFUL RESOURCES

RECOMMENDED CLINICAL PROTOCOL

Clinical study showcasing recommended clinical protocol for EthOss

Download

SURGICAL GUIDELINES

The official recommended guide on how to use EthOss

Download

HOW TO MIX ETHOSS

Explainer video

Watch