

PATIENT MEDICAL HISTORY

Female
47 years old

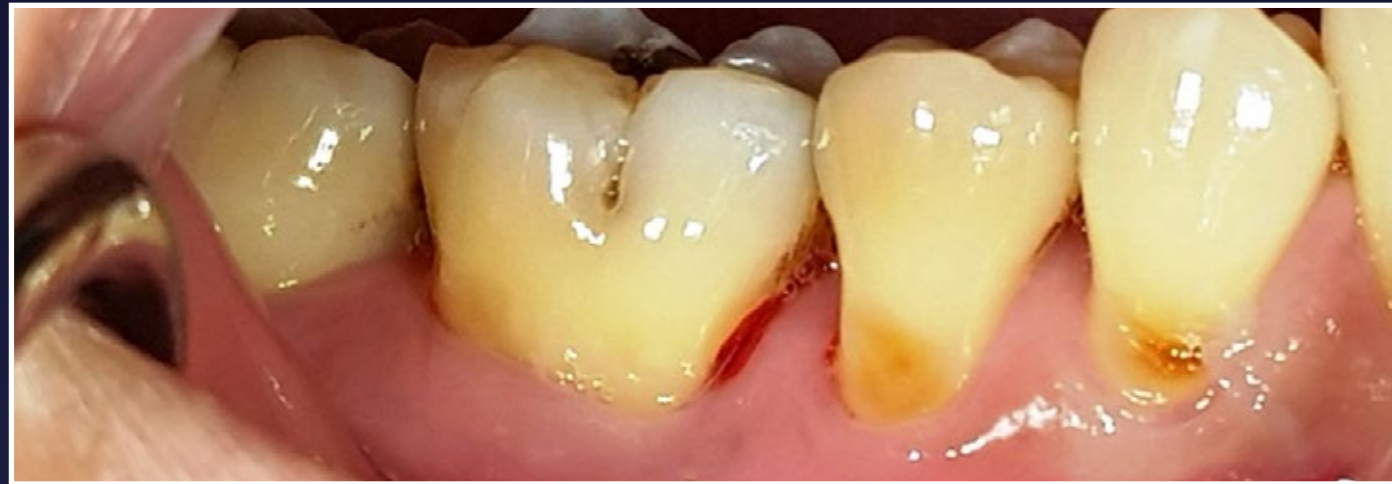Successfully undergone non-surgical periodontal therapy

6mm probing pocket depth on mesial of tooth LR6

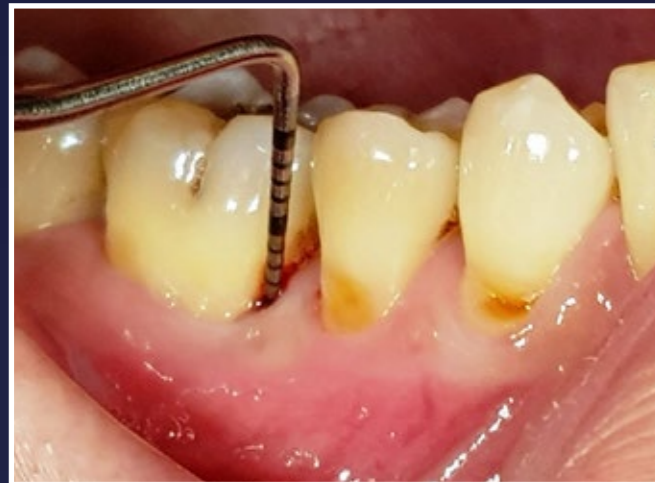Case from Dr Renukanth Raman, Malaysia



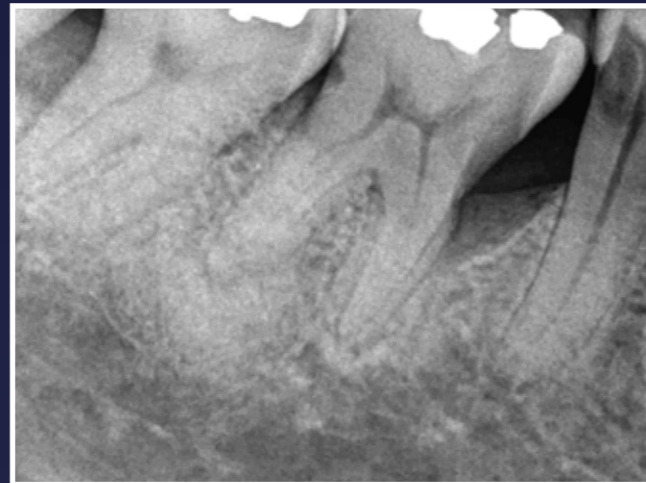 Dr Renukanth Raman



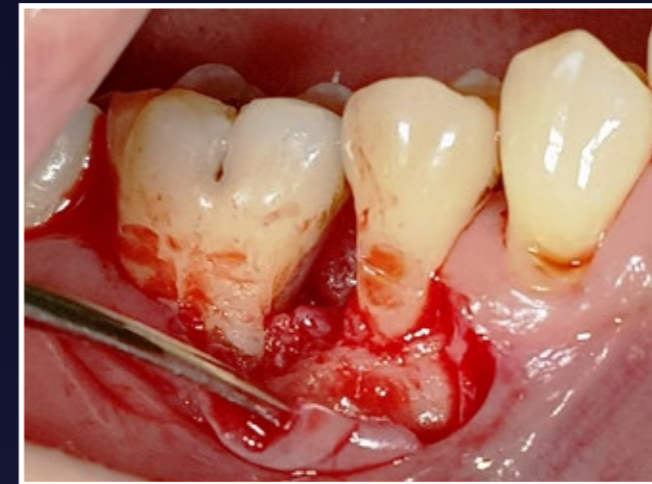
1. Initial situation



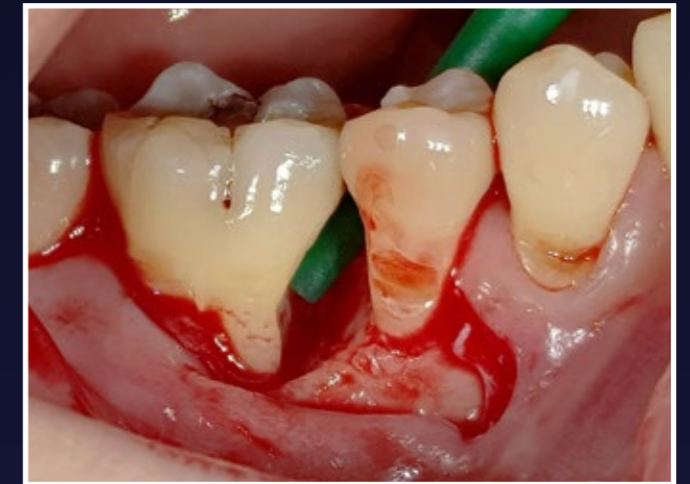2. Initial situation - 6mm PPD



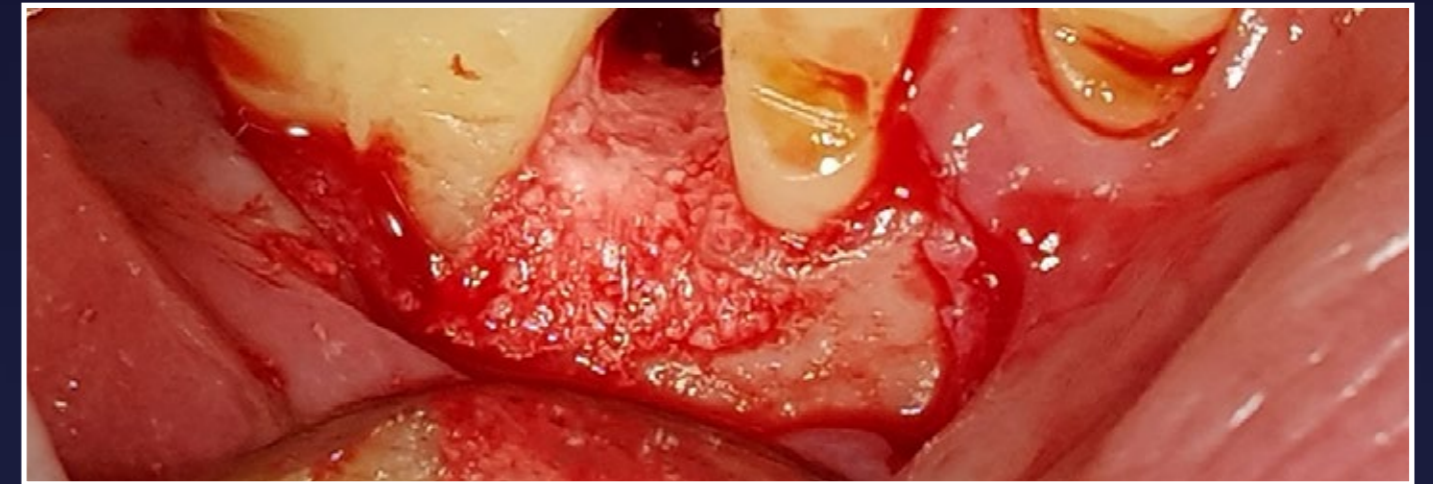
3. Initial situation - radiograph



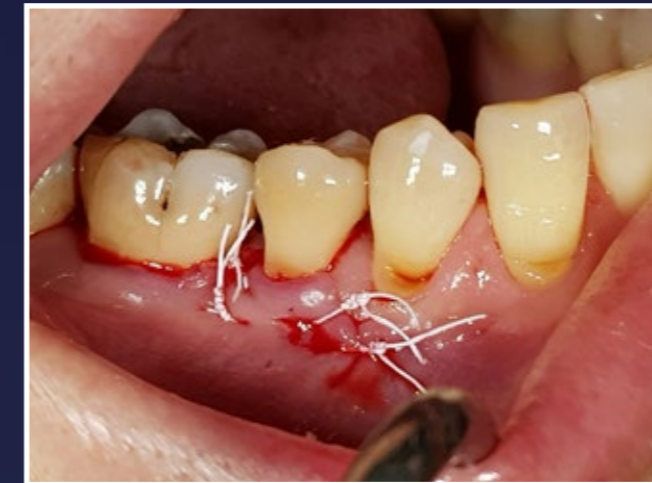4. Localised flap on buccal aspect



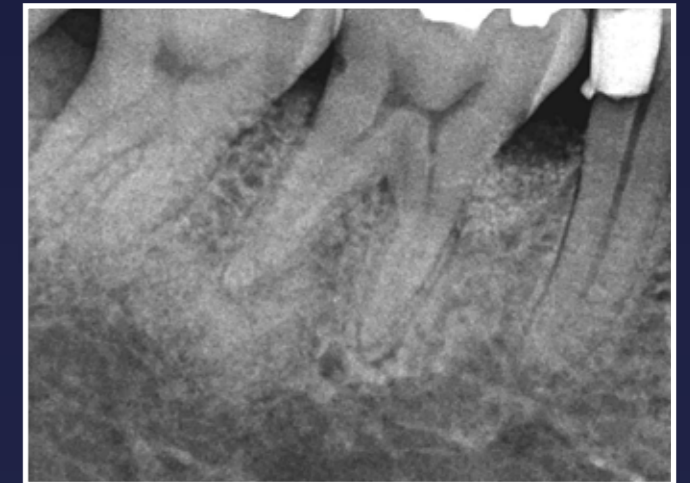5. Following cleaning defect is visible - apically 2 walled, coronally 1 walled



6. Grafted with EthOss, moulded to shape and dried

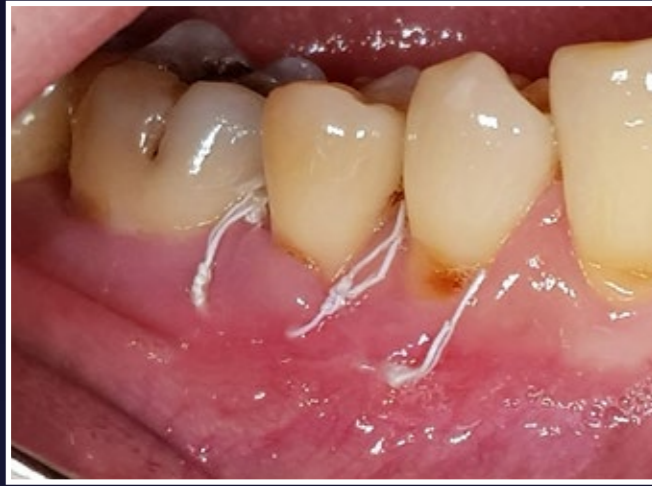

7. Passive closure

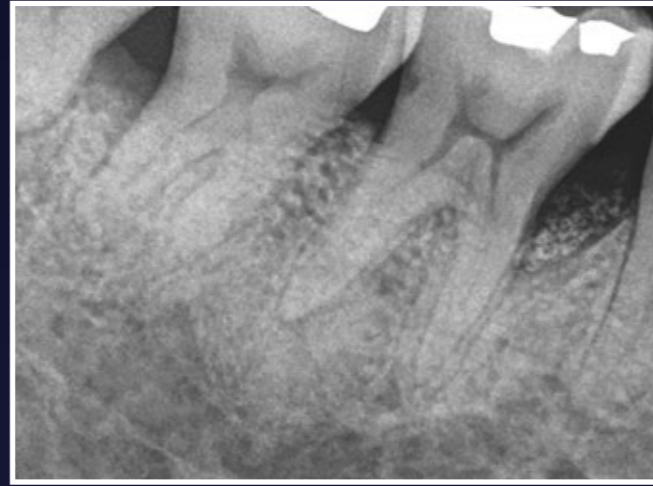

8. Radiograph immediately post-op

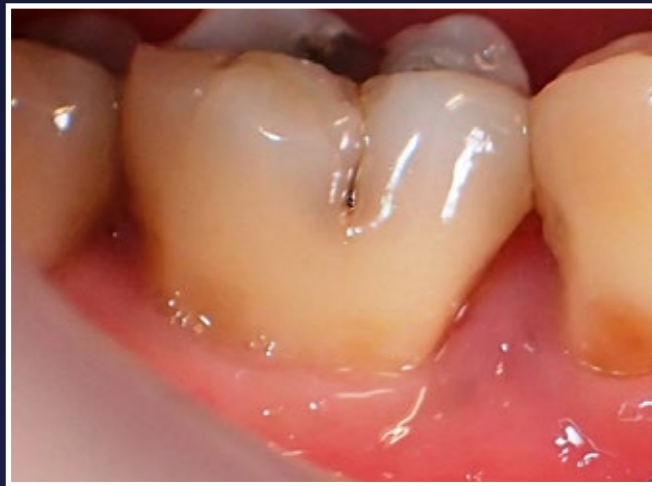RESULTS



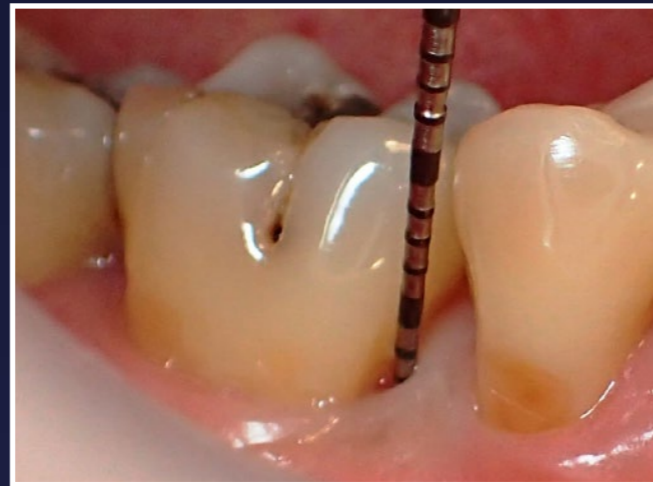9. 1 week healing post-op



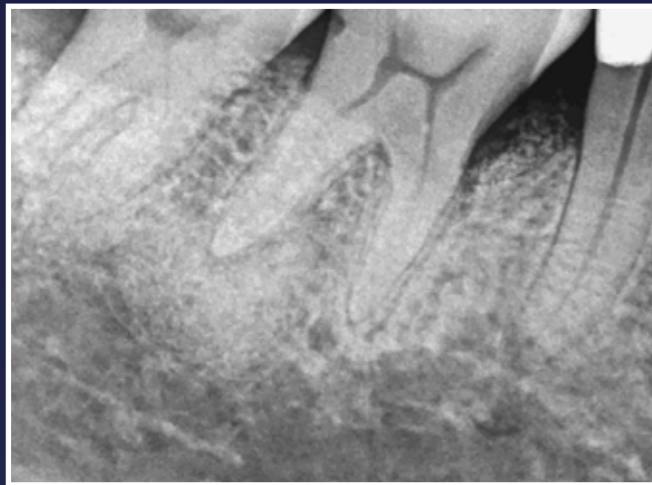10. Radiograph at 1 month note post-op. Slight radiopacity to be expected as the Calcium Sulphate resorbs



11. 6 months post-op, good maintenance of interproximal tissues



12. 6 month post-op, 3mm PPD



13. Result at 6 months, expect further improvements over time

GROW
SAFER