

PATIENT MEDICAL HISTORY

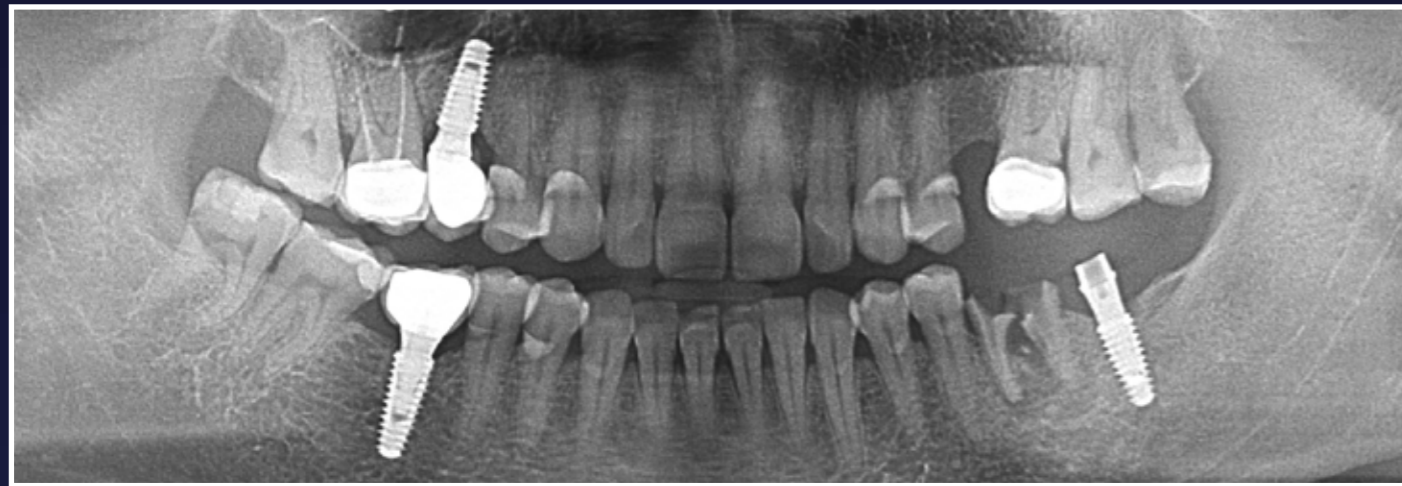Female
50 years old
Diabetic, non-smoker

Long-term draining abscess with multiple previous apicectomies

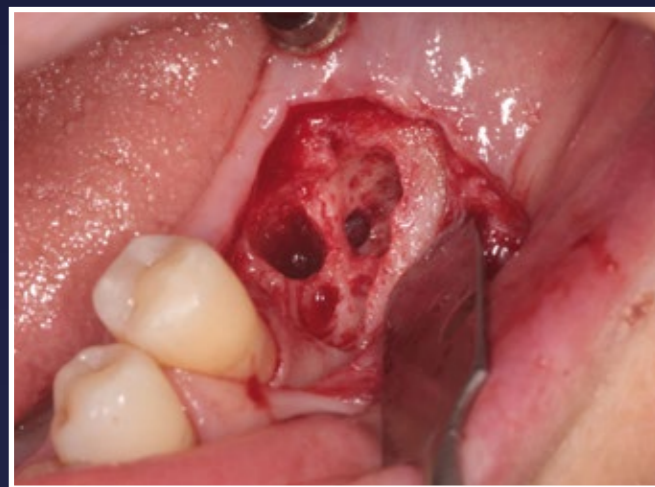Case from Dr Ștefan Anca, Romania



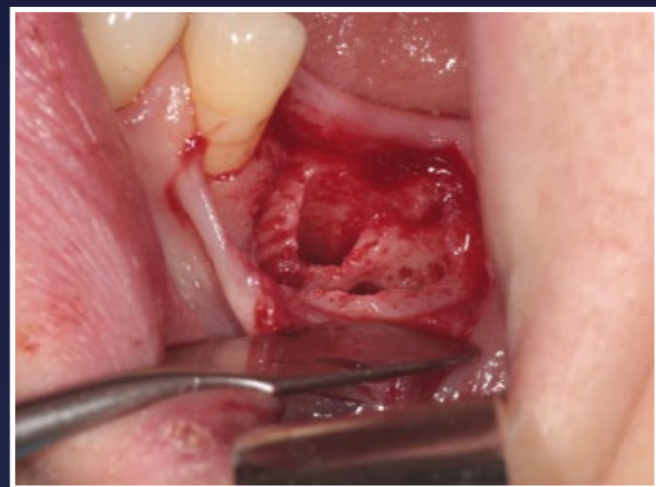Dr Ștefan Anca



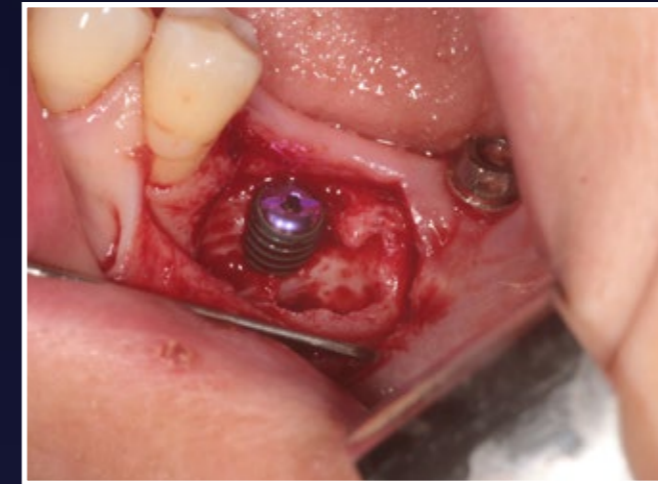1. Panoramic radiographic - initial LL6 (36) is lost



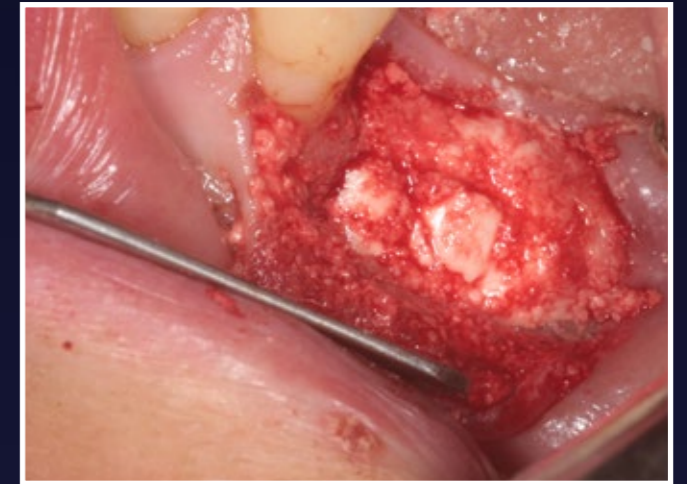
2. Two and a half months post extraction of LL6



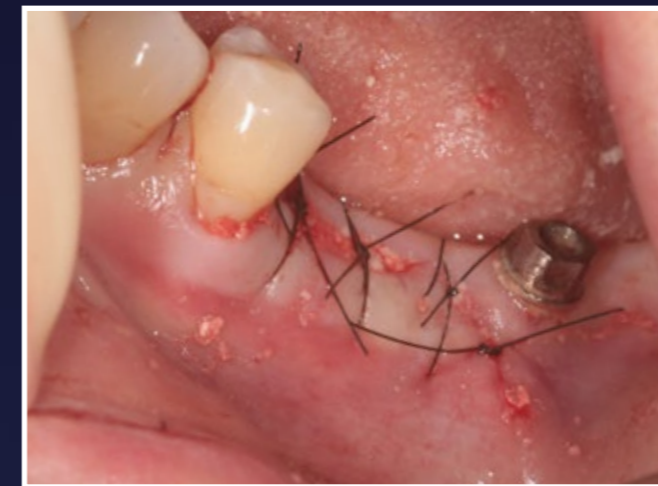3. Large defect in bone, bad healing



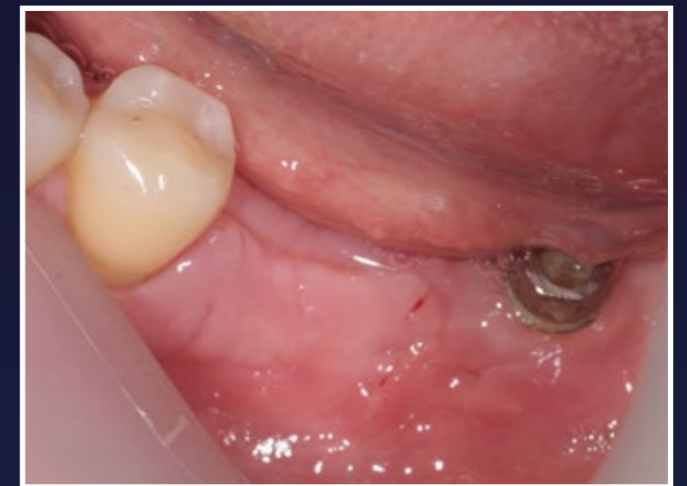4. Implant placed



5. Grafted with EthOss bone graft material

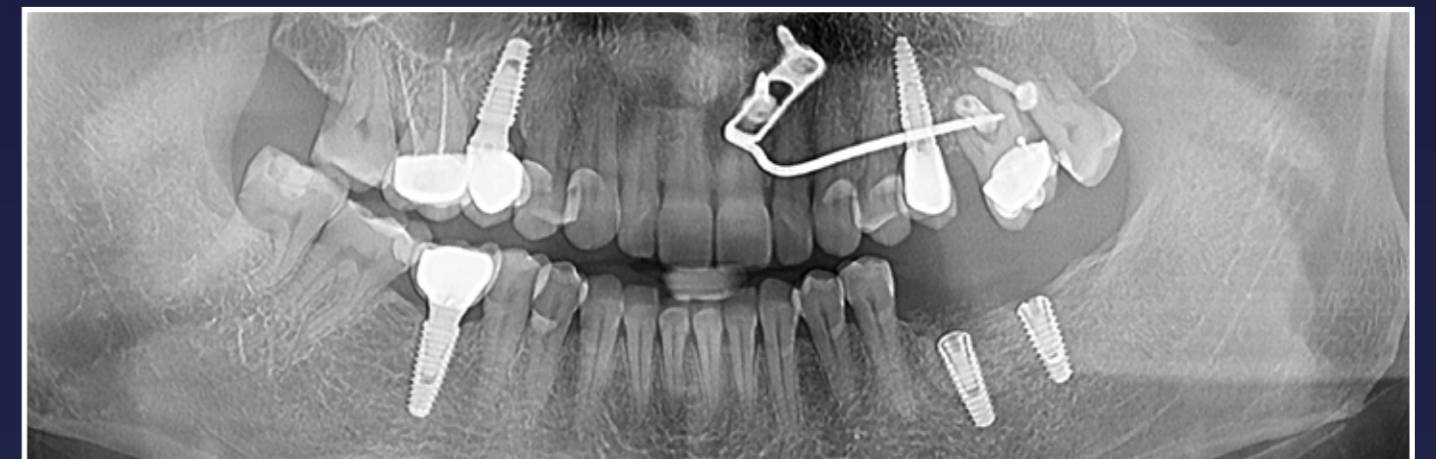

6. Sutured shut



7. 11 days post op shows excellent healing

RESULTS



8. Panoramic radiograph at 1 year and 2 months