

PATIENT MEDICAL HISTORY

Female
79 years old
Healthy, non-smoker

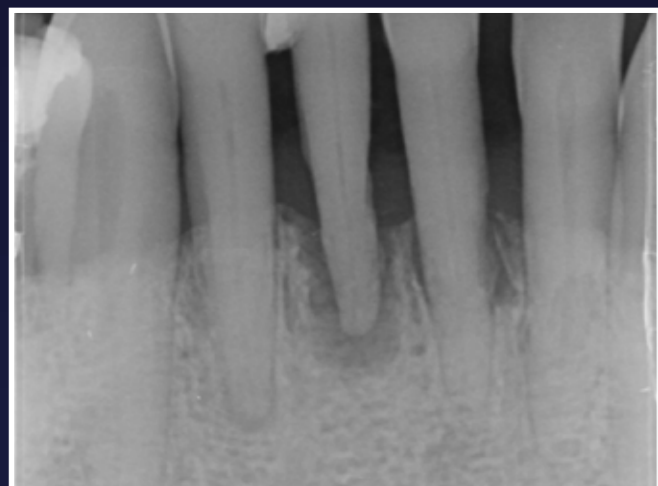
Patient suffered from localised periodontitis affecting all lower incisors with severe bone loss

Case from Dr Jonathan Cochrane, Bristol, UK

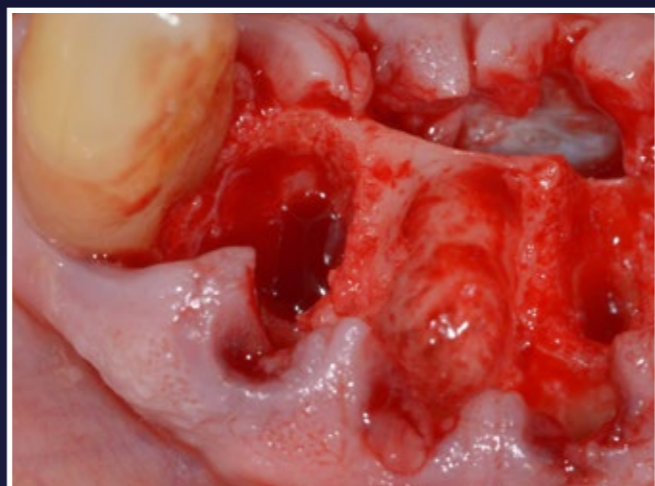
First published in the EDI journal, Issue 2/20



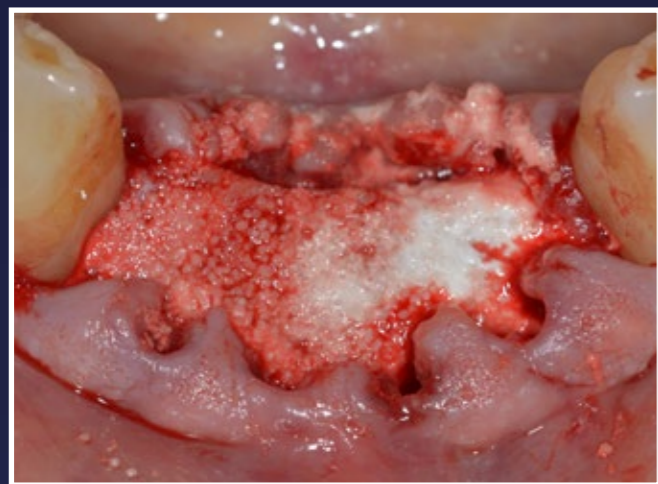🇬🇧 Dr Jonathan Cochrane



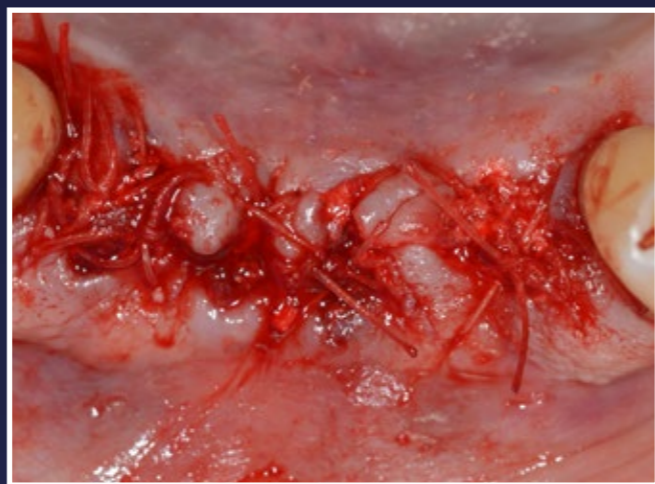1. Initial periapical radiograph



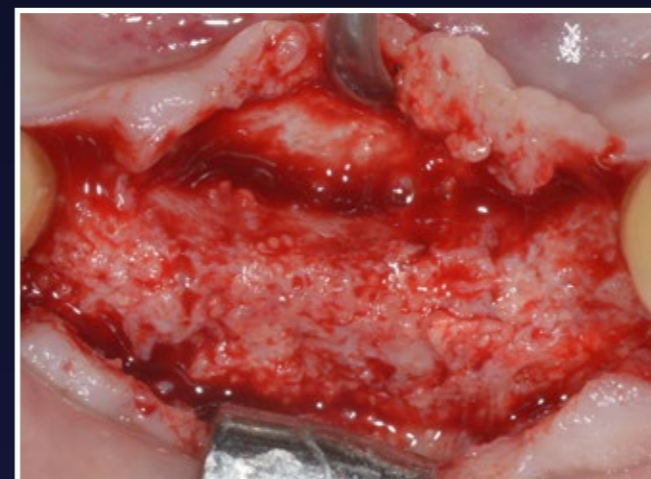2. Clinical view immediately after extractions and socket curettage, flap raised and released lingually and buccally



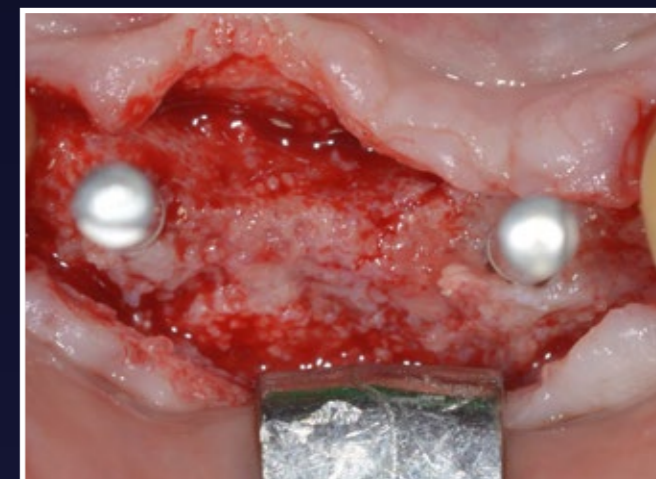3. Intraoperative situation after the application and setting of EthOss in situ



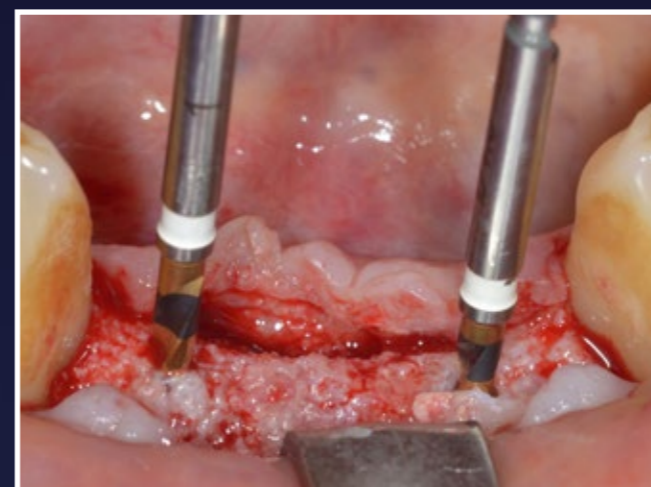4. Surgical wound sutured with Vicryl Rapide - primary closure almost achieved



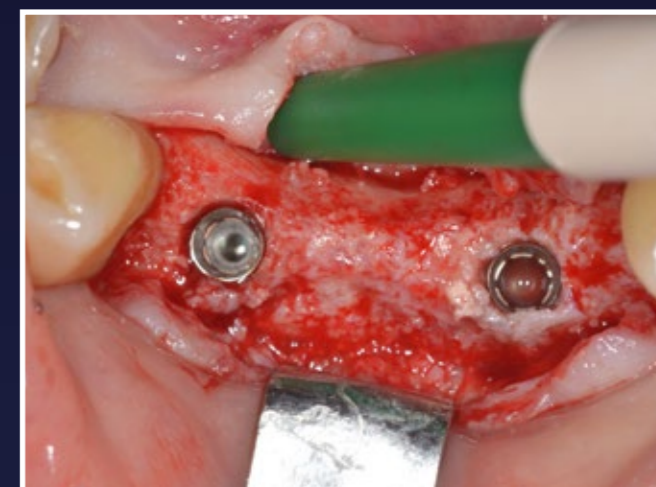5. Re-entry 10 weeks later, single crestal incision made



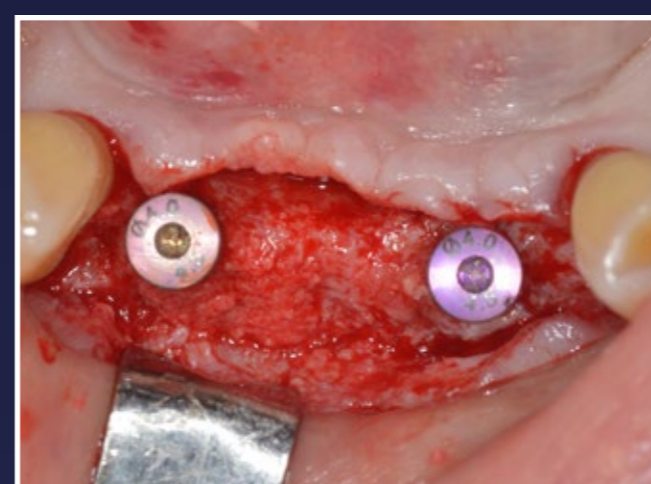6. Freehand placements with the initial twist drills in the lateral positions - occlusal view



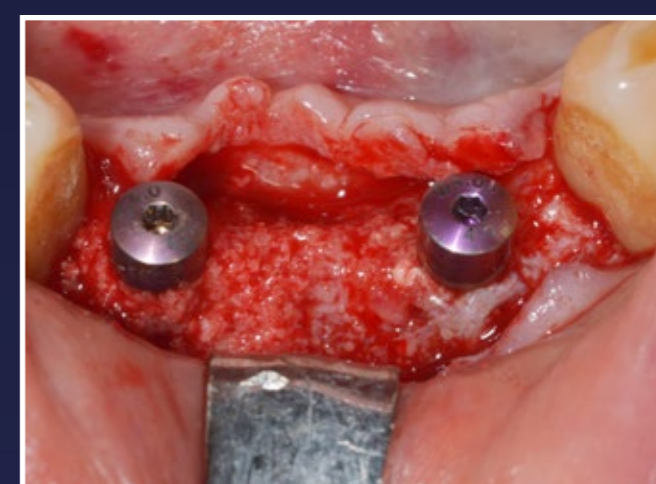7. Buccal view



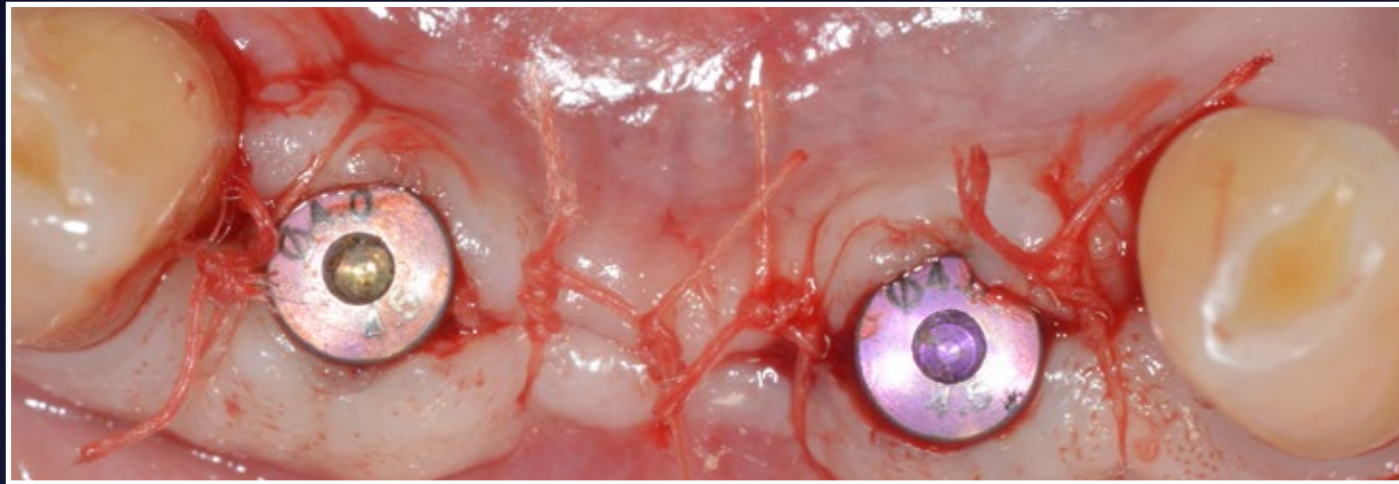
8. Immediately after placing the implants in the optimal three dimensional position - occlusal view



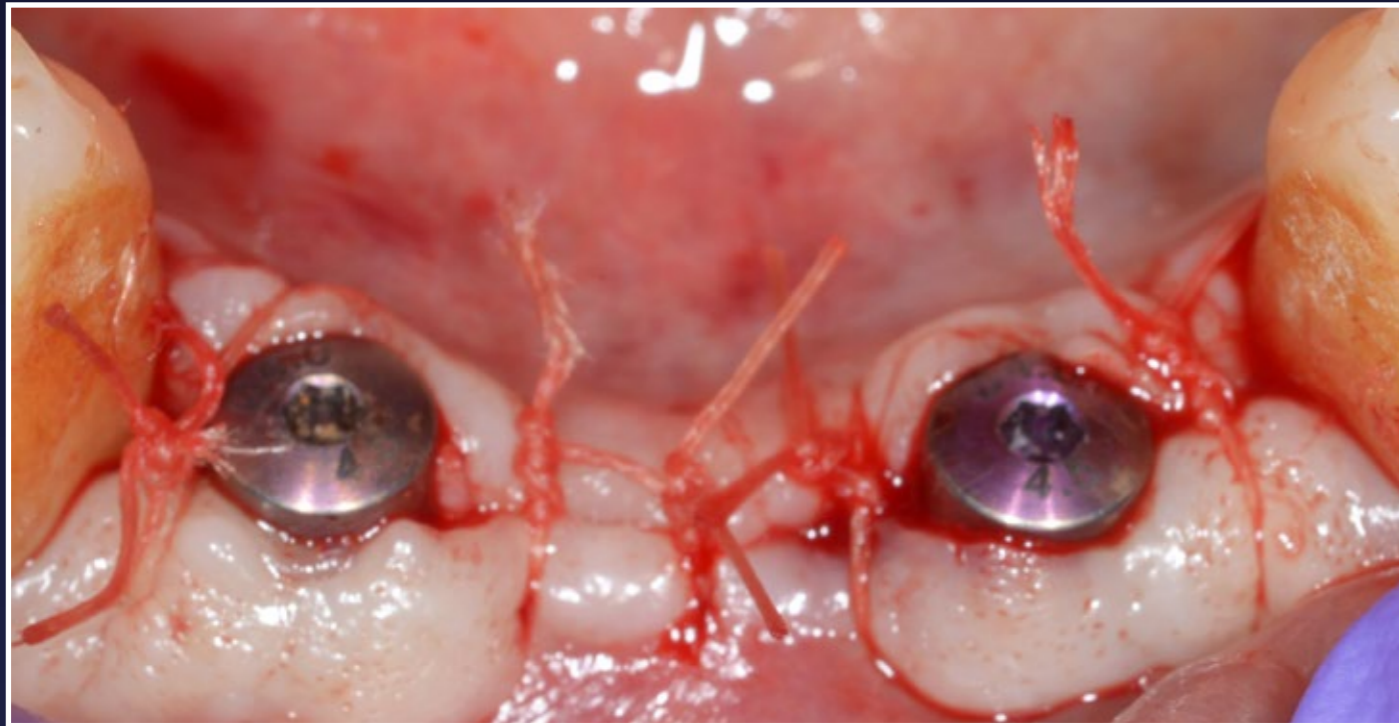
9. Healing abutments placed - occlusal view



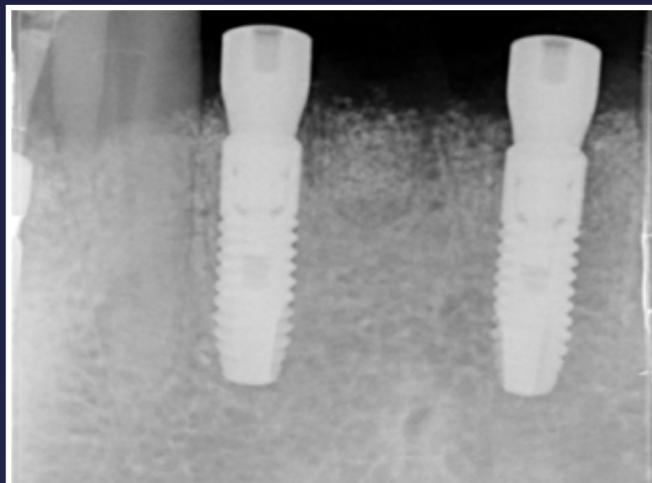
10. Buccal view



11. Surgical site closed - occlusal view

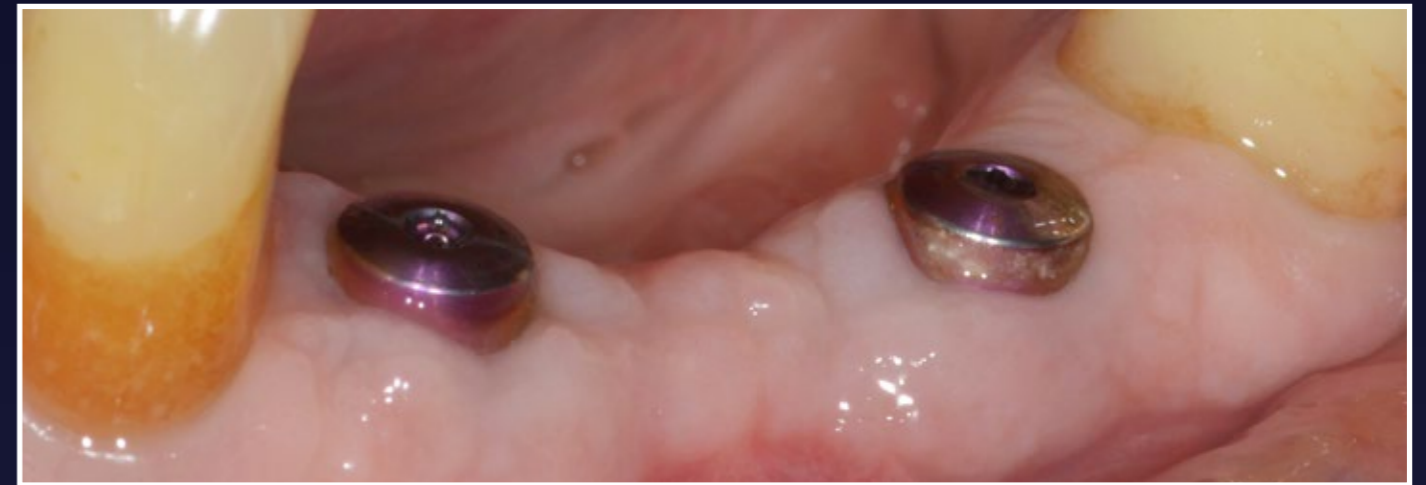

12. Buccal view

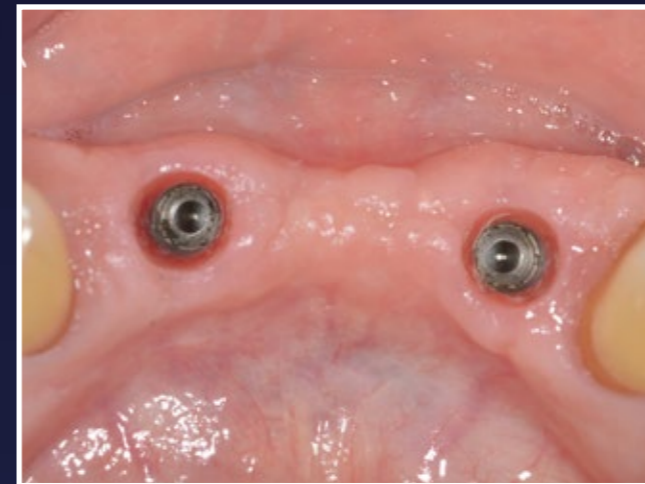


13. Periapical radiograph immediately post-op

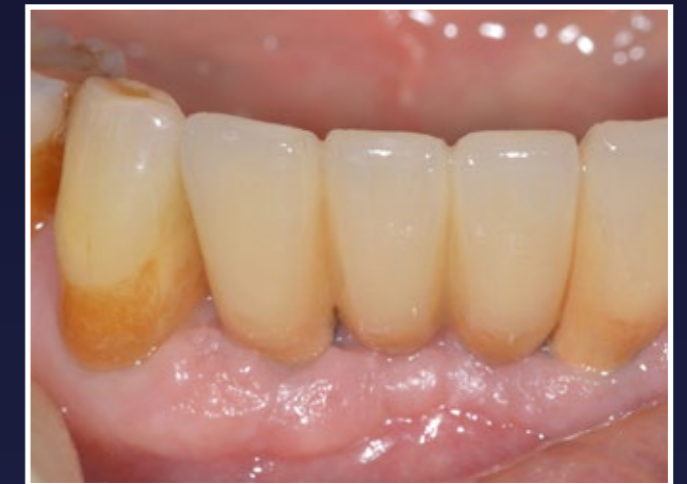RESULTS



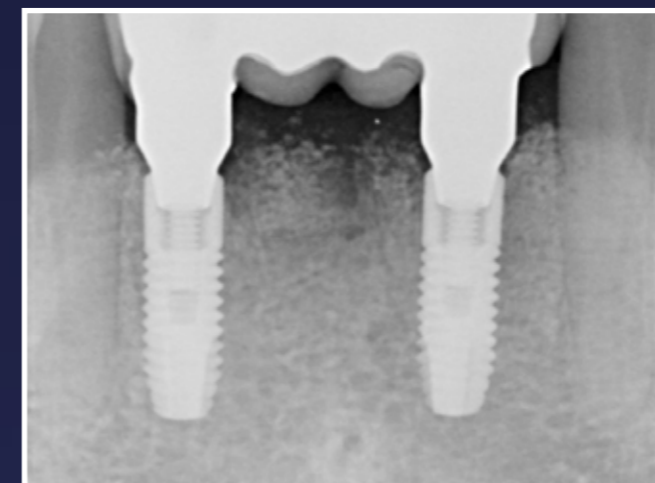
14. Restoration phase, 10 weeks later, showing nicely healed, regenerated keratinised soft tissues



15. Occlusal view of implants and peri-implant soft tissues immediately prior to fit of the final implant bridge



16. Final implant bridge immediately after fitting - buccal view



17. Periapical radiograph after fitting the final implant bridge. The grafting material is turning over, being gradually replaced by newly formed bone. The loading of implants will lead to further consolidation and remodelling of the regenerated bony tissue