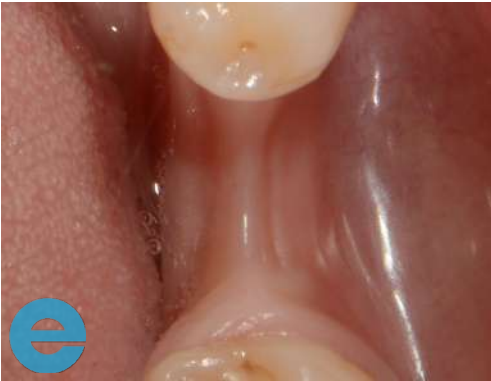
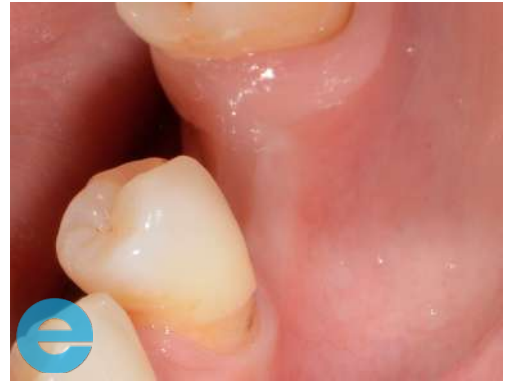
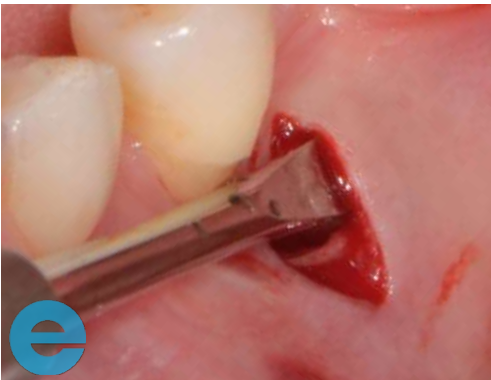TUNNEL GRAFT CASE STUDY



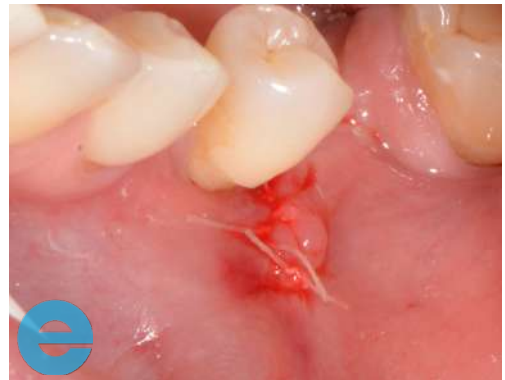1. Narrow ridge due to modelling.



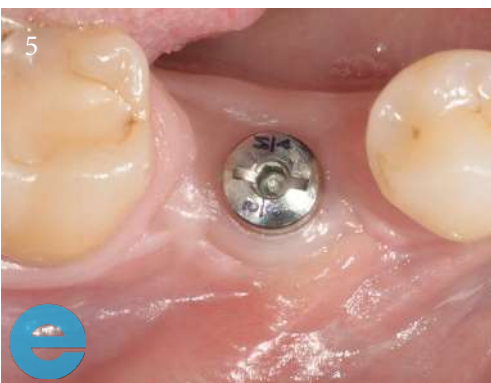2. Narrow ridge and reduced keratinized gingiva.



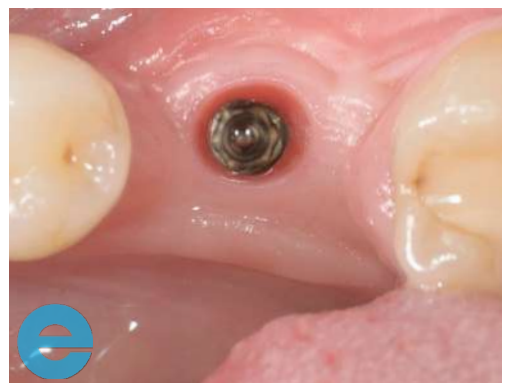3. Incision distal to 5, periosteum lifted.



4. EthOss® placed with graft gun and sutured closed.

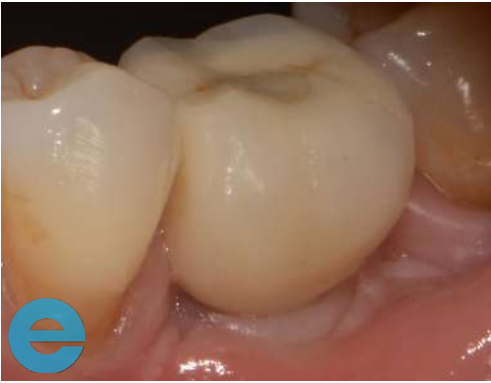

5. Implant placed at 10 weeks following graft. Image shows healing at 10 weeks following implant placement

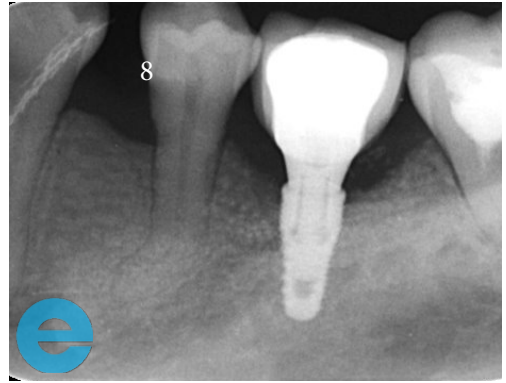


6. Also 10 week following implant placement, cap removed to take impression, there was no soft tissue grafting. 75 ISQ reading

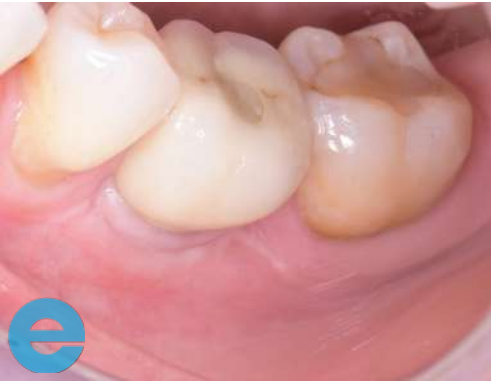TUNNEL GRAFT CASE STUDY



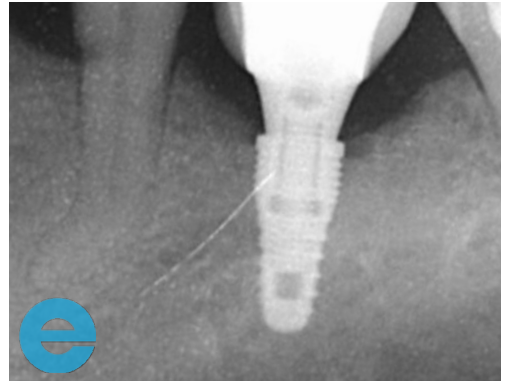
7. Loaded 9 months



8. Loaded 9 months



9. Loaded 3 years



10. Loaded 3 years



GROW STRONGER

USEFUL RESOURCES

RECOMMENDED CLINICAL PROTOCOL

Clinical study showcasing recommended clinical protocol for EthOss

Download

SURGICAL GUIDELINES

The official recommended guide on how to use EthOss

Download

HOW TO MIX ETHOSS

Explainer video

Watch