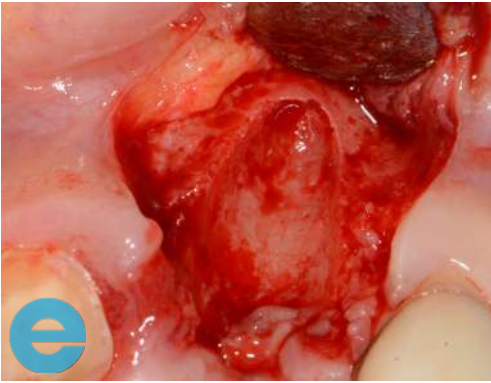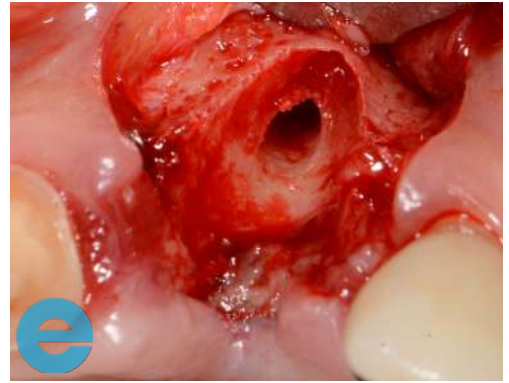


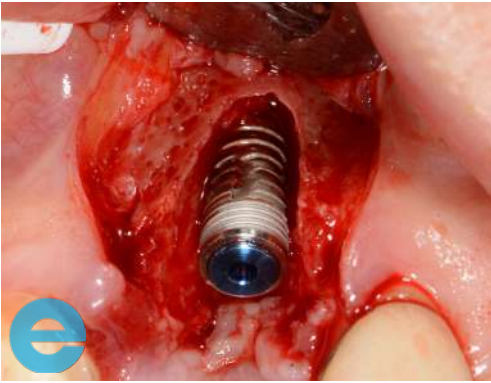
UPPER LEFT CENTRAL CASE STUDY



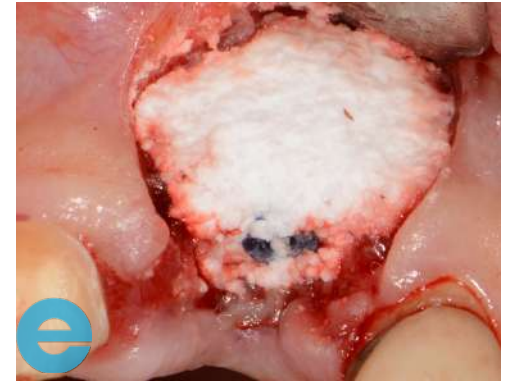1. Small flap raised to show buccal defect.



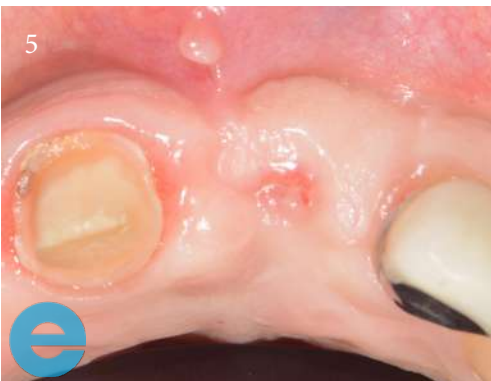2. Osteotomy in the ideal restorative position, not too palatal.



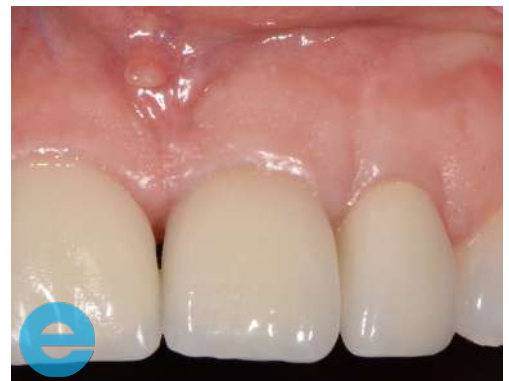3. Placement of 4.5 by 10 implant.



4. Graft with EthOss®.

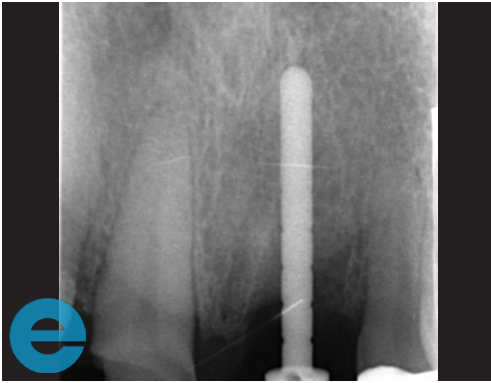


5. Ready to load at 12 weeks.

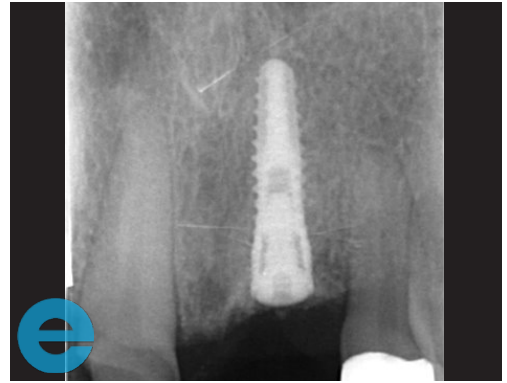


6. Loaded at 9 months.

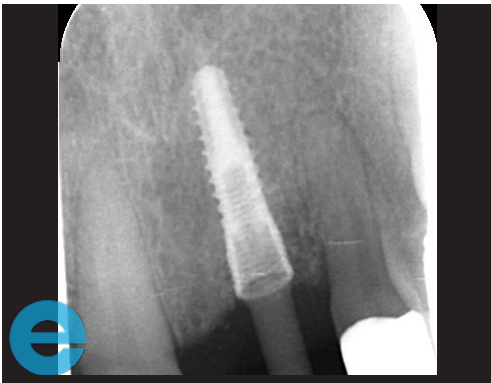UPPER LEFT CENTRAL CASE STUDY



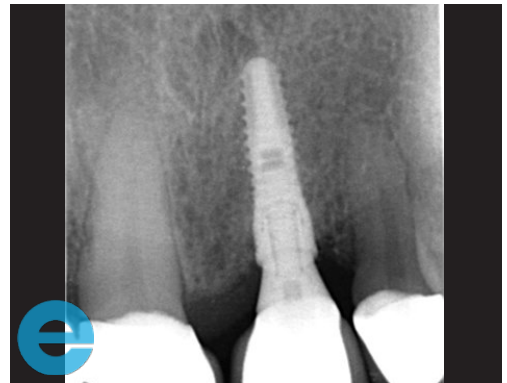
7. Measuring tool to assess height.



8. Site grafted with EthOss®.



9. Osstell peg, 75 ISQ.



10. Loaded 9 months.



GROW STRONGER

USEFUL RESOURCES

RECOMMENDED CLINICAL PROTOCOL

Clinical study showcasing recommended clinical protocol for EthOss

Download

SURGICAL GUIDELINES

The official recommended guide on how to use EthOss

Download

HOW TO MIX ETHOSS

Explainer video

Watch