

PATIENT MEDICAL HISTORY

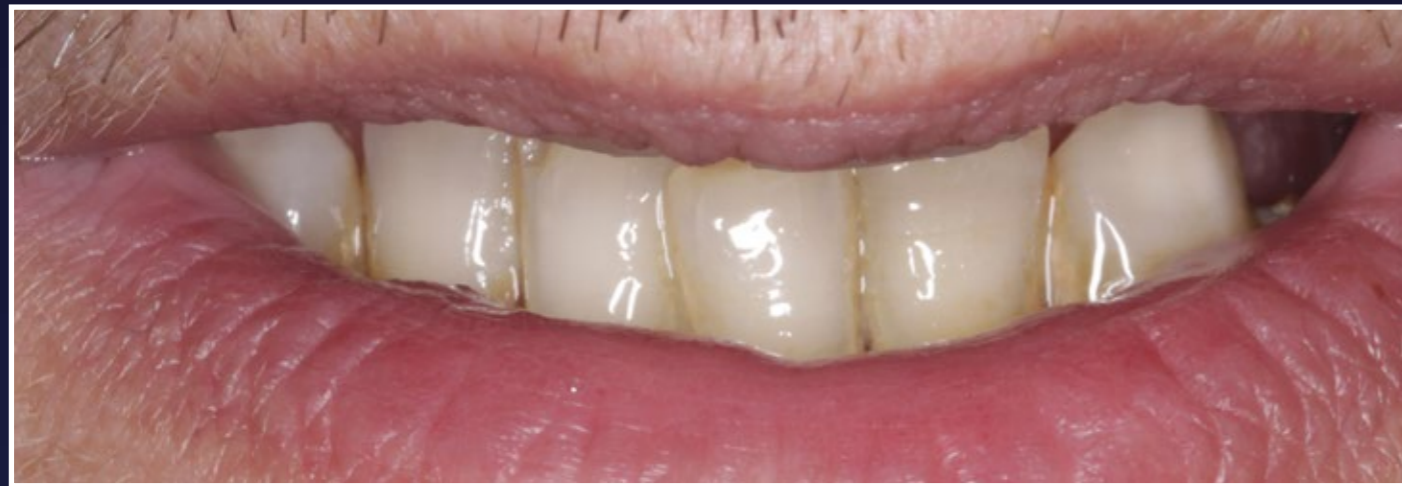Male  
37 years old  
Healthy, non-smoker

Patient suffers from unrestorable upper and lower dentition

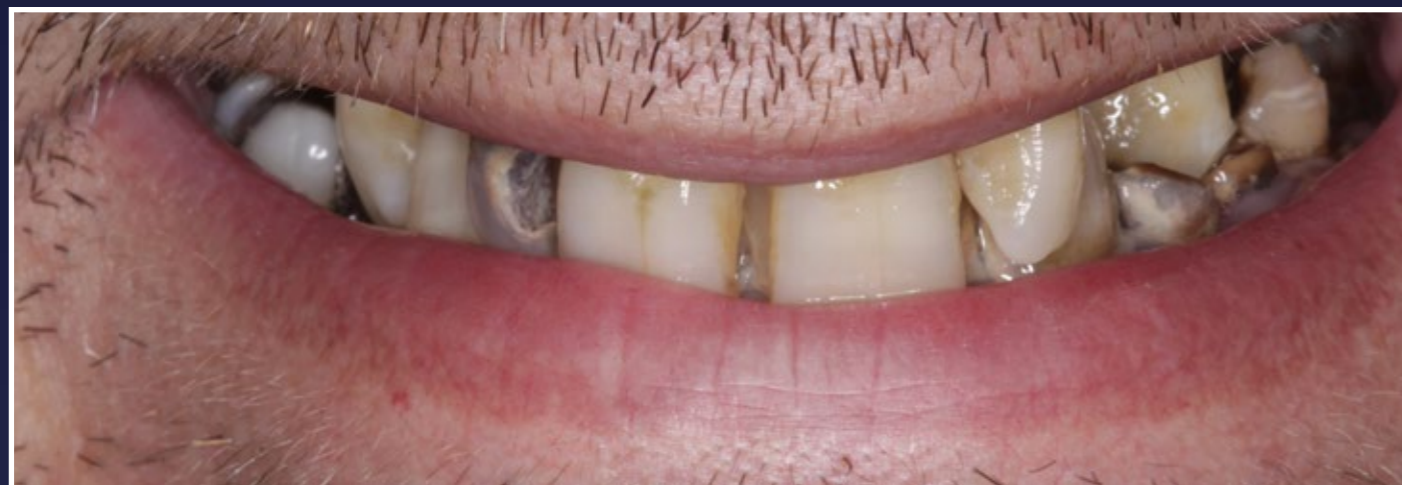Case from Dr Adeel Ali,  
London, UK



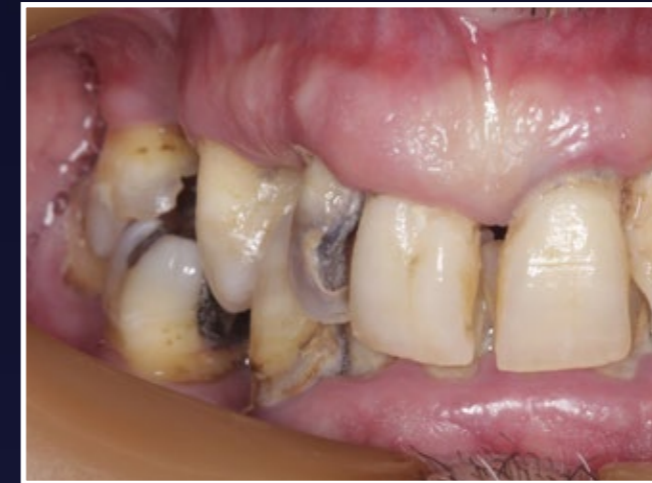🇬🇧 Dr Adeel Ali



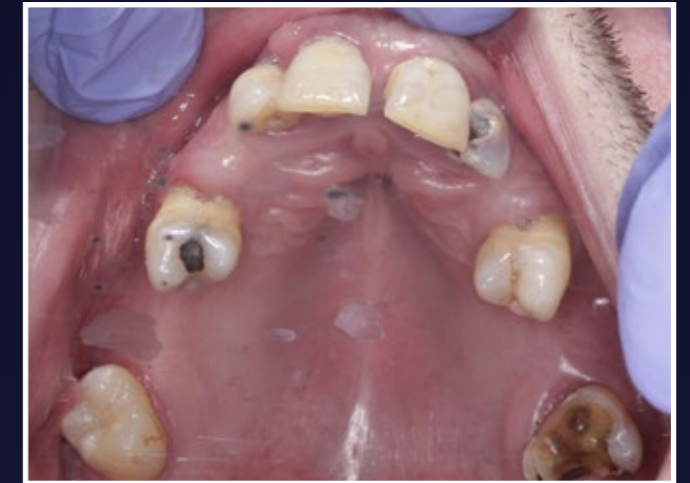1. Lips at rest view



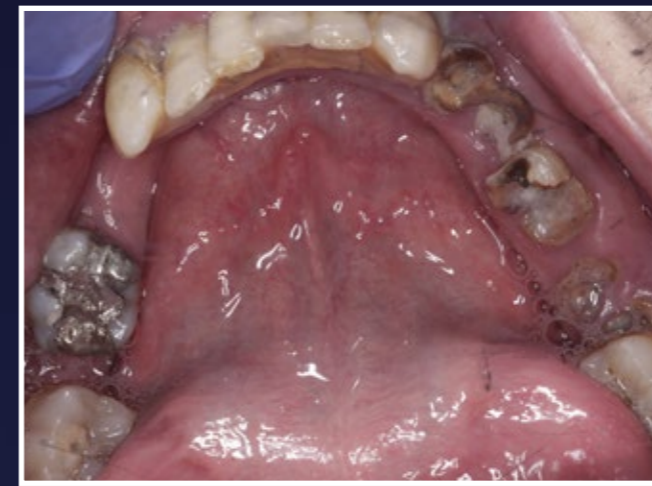2. Pre-op view



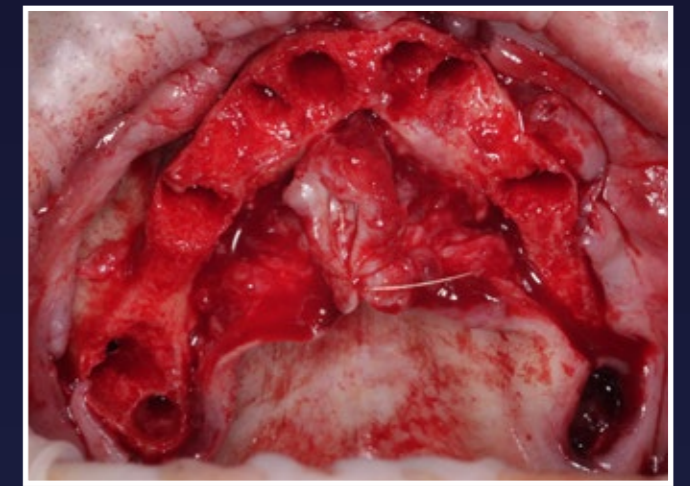
3. Retracted view



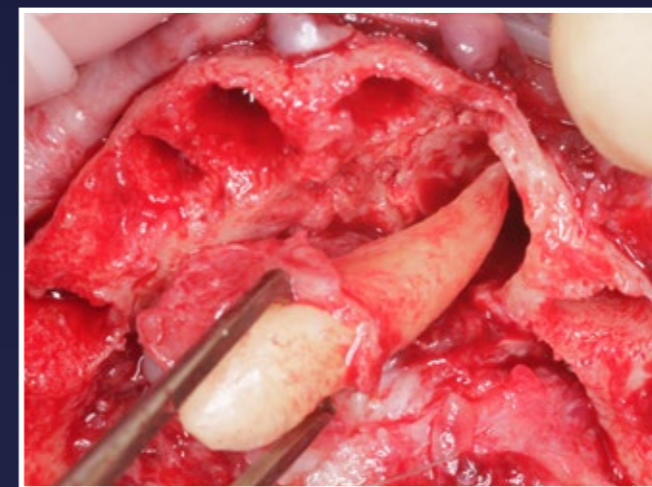
4. Upper arch



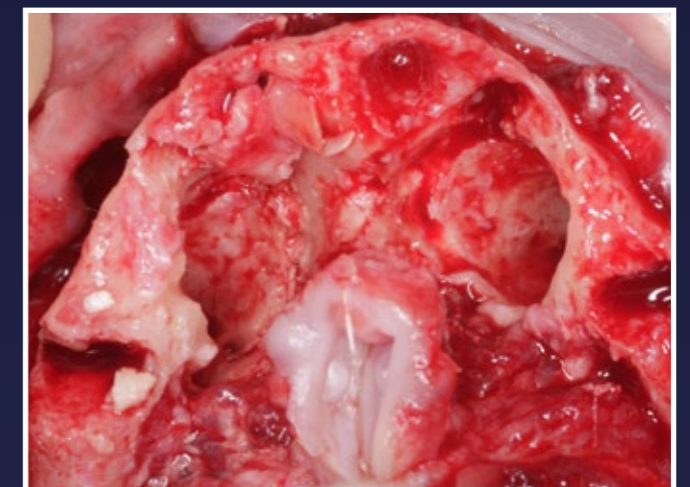5. Lower arch



6. Flap raised shows minimal ridge thickness in premaxilla

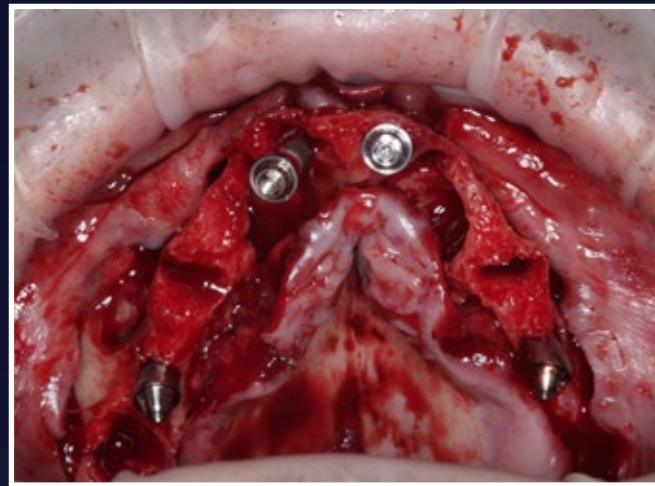


7. Impacted canine removed

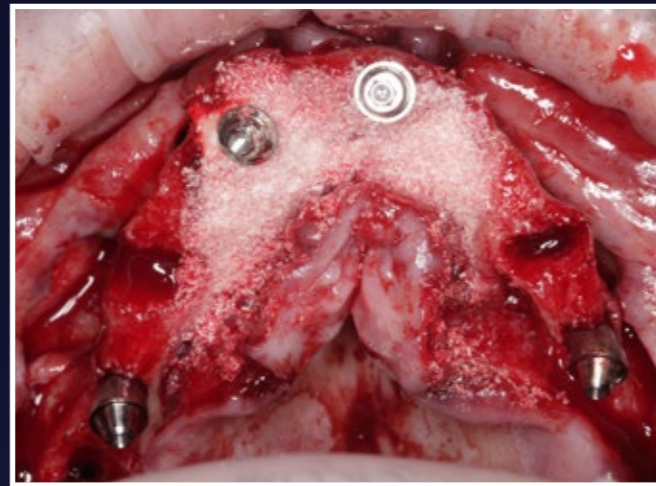


8. Defects left by removal of impacted canines

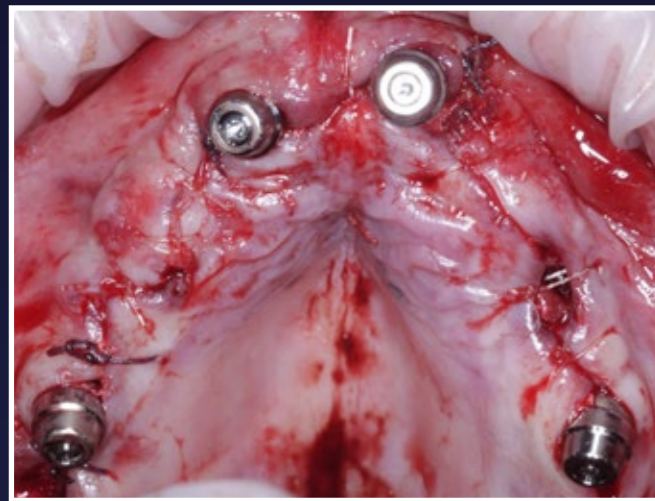




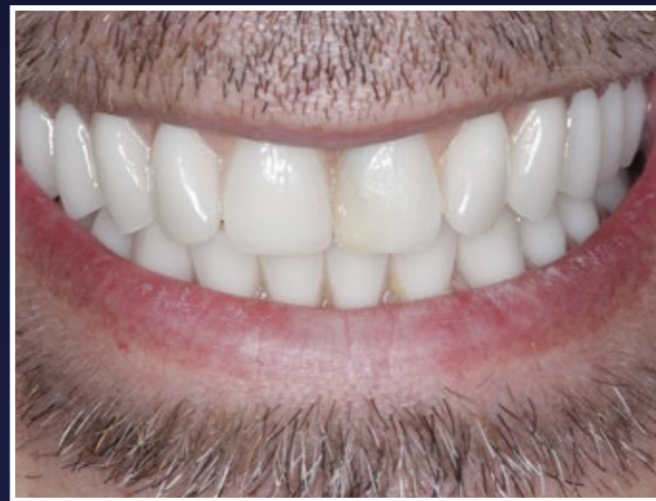9. Neodent GM implants placed



10. Grafted with EthOss

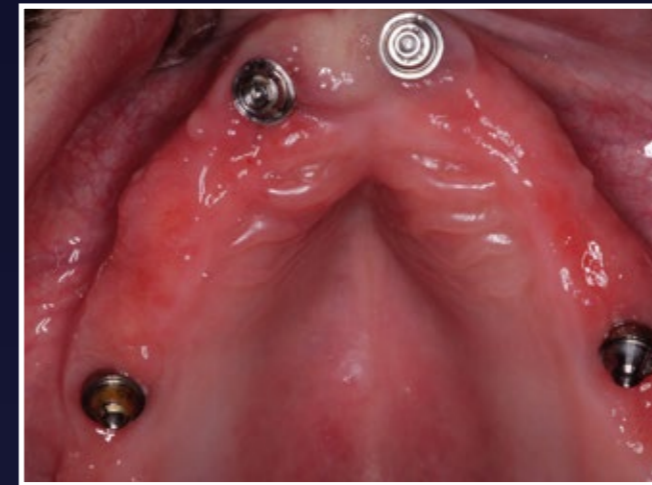

11. Sutured closed

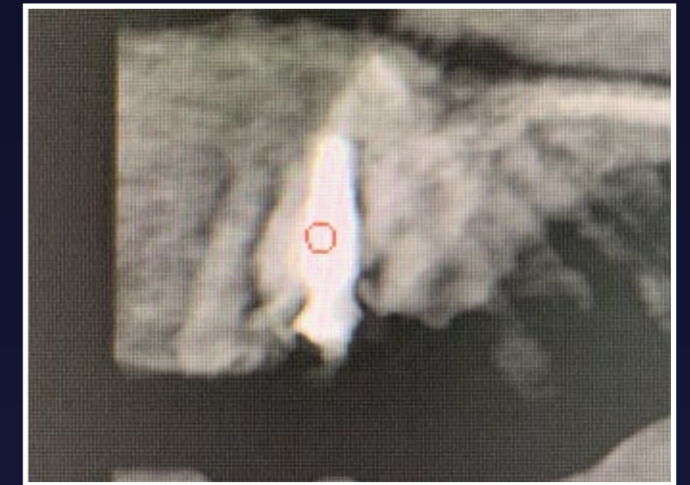

12. Immediate post-op

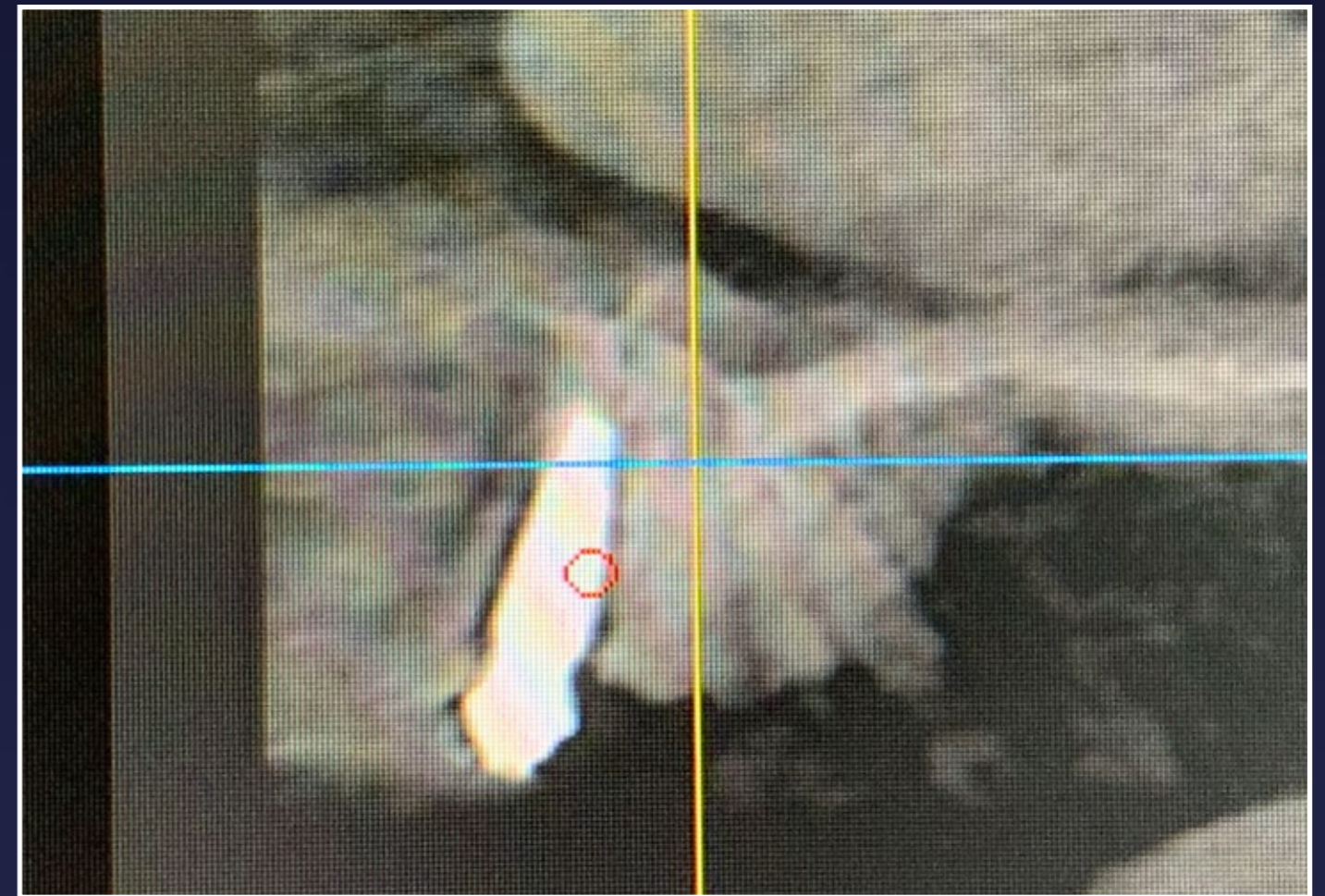
RESULTS



13. Upper arch - 10 months post-op



14. Post-op CBCT shows maturation of EthOss graft



15. Post-op CBCT shows maturation of EthOss graft