

PATIENT MEDICAL HISTORY

Female  
41 years old

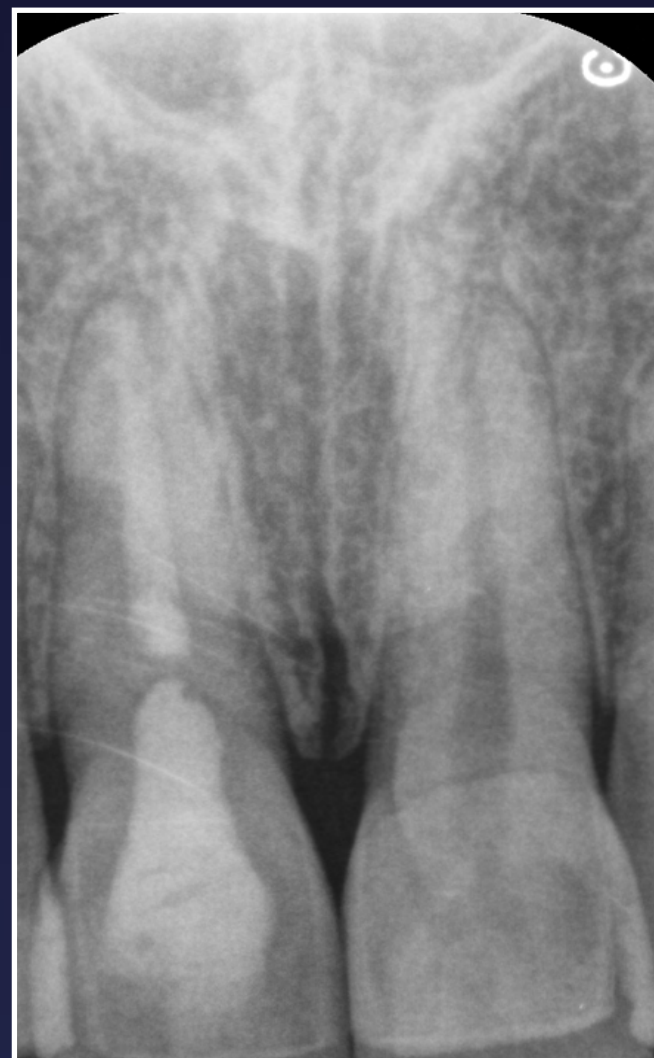Failed root canal therapy UR1

Endodontic retreatment carried out twice by specialist endodontist to no avail

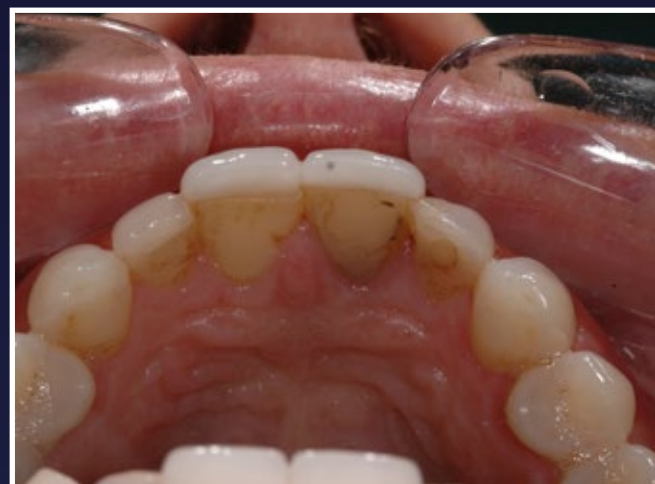Dr Mark Worthing,  
Hereford, UK



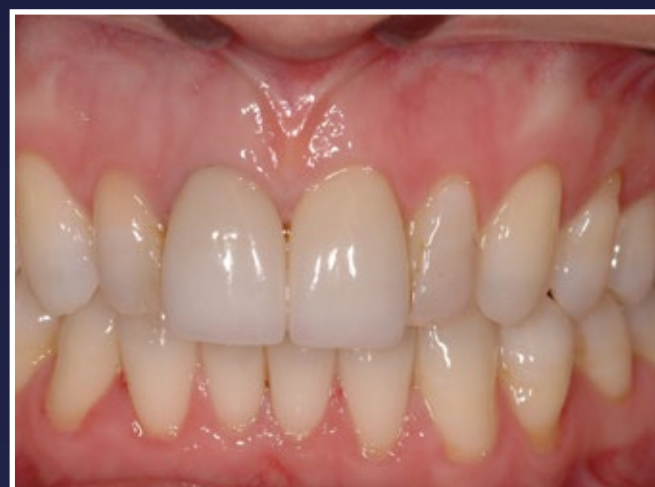🇬🇧 Dr Mark Worthing



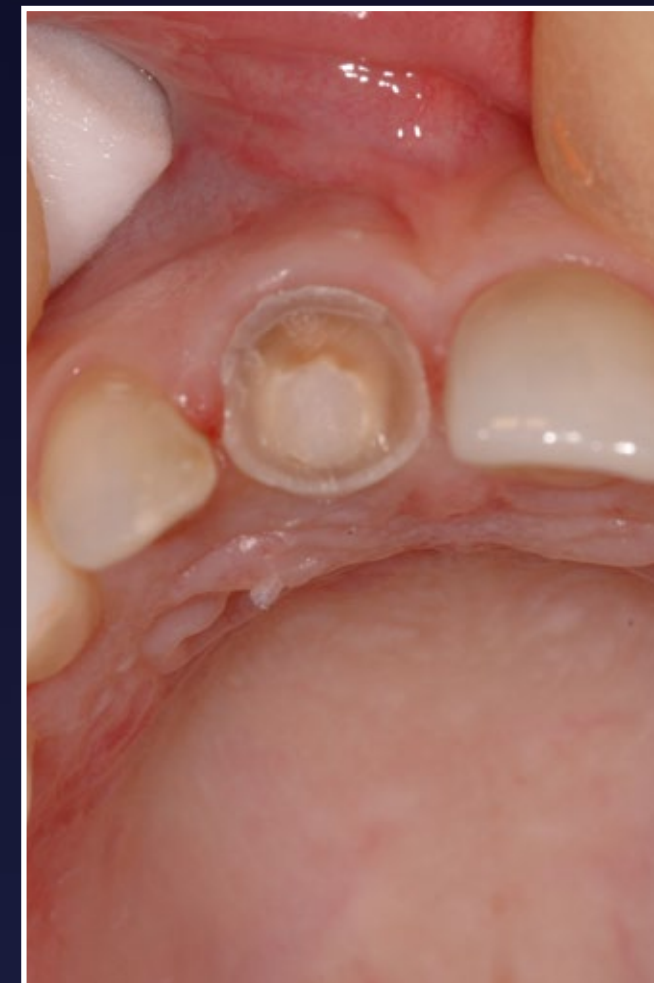1. Pre-op



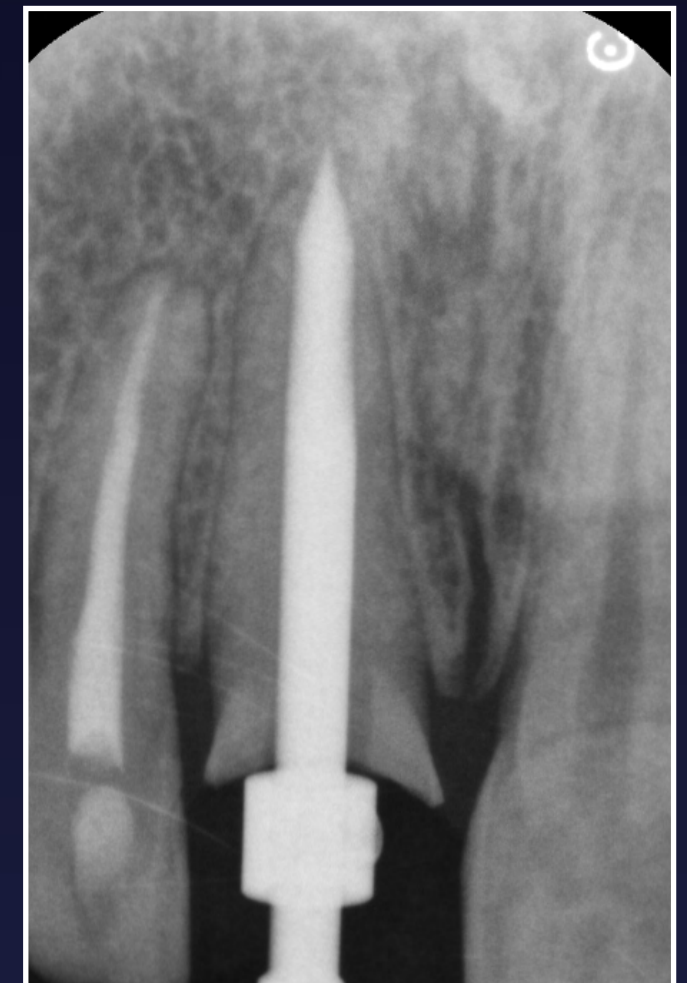2. Pre-op occlusal view



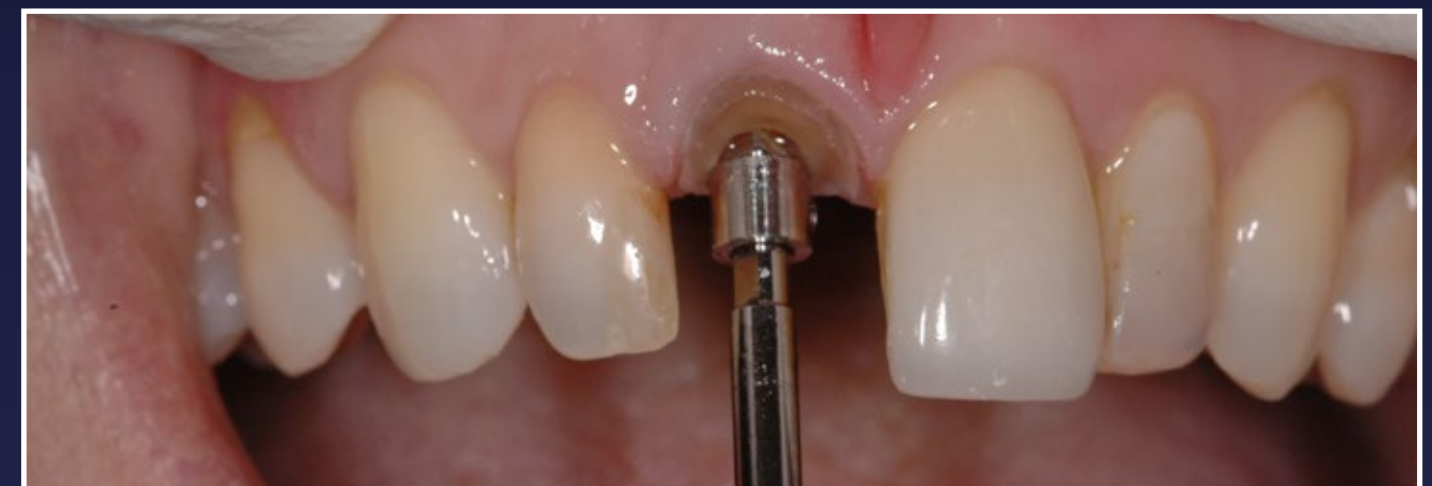3. Pre-op



4. Decoronation

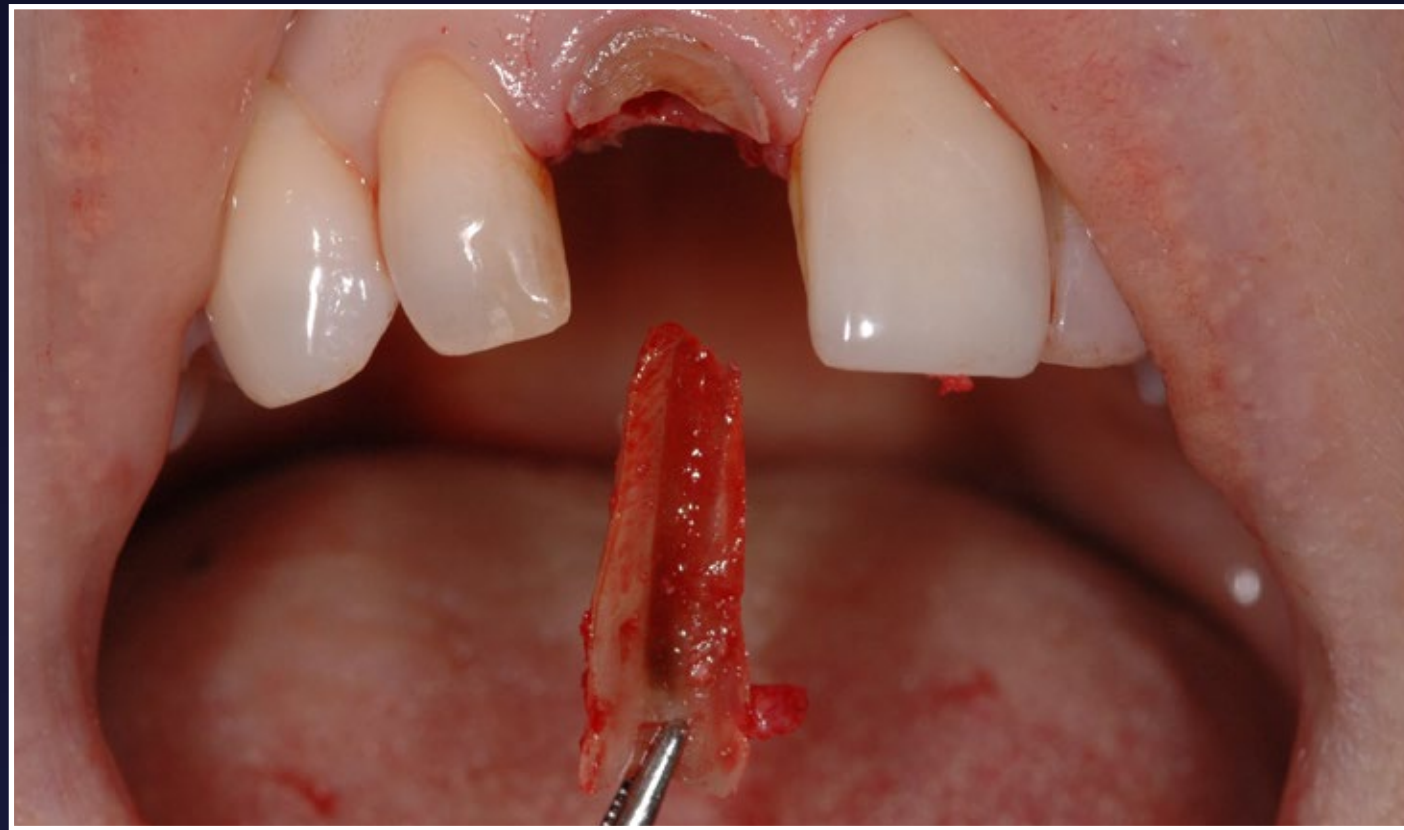


5. Check radiograph for partial extraction therapy

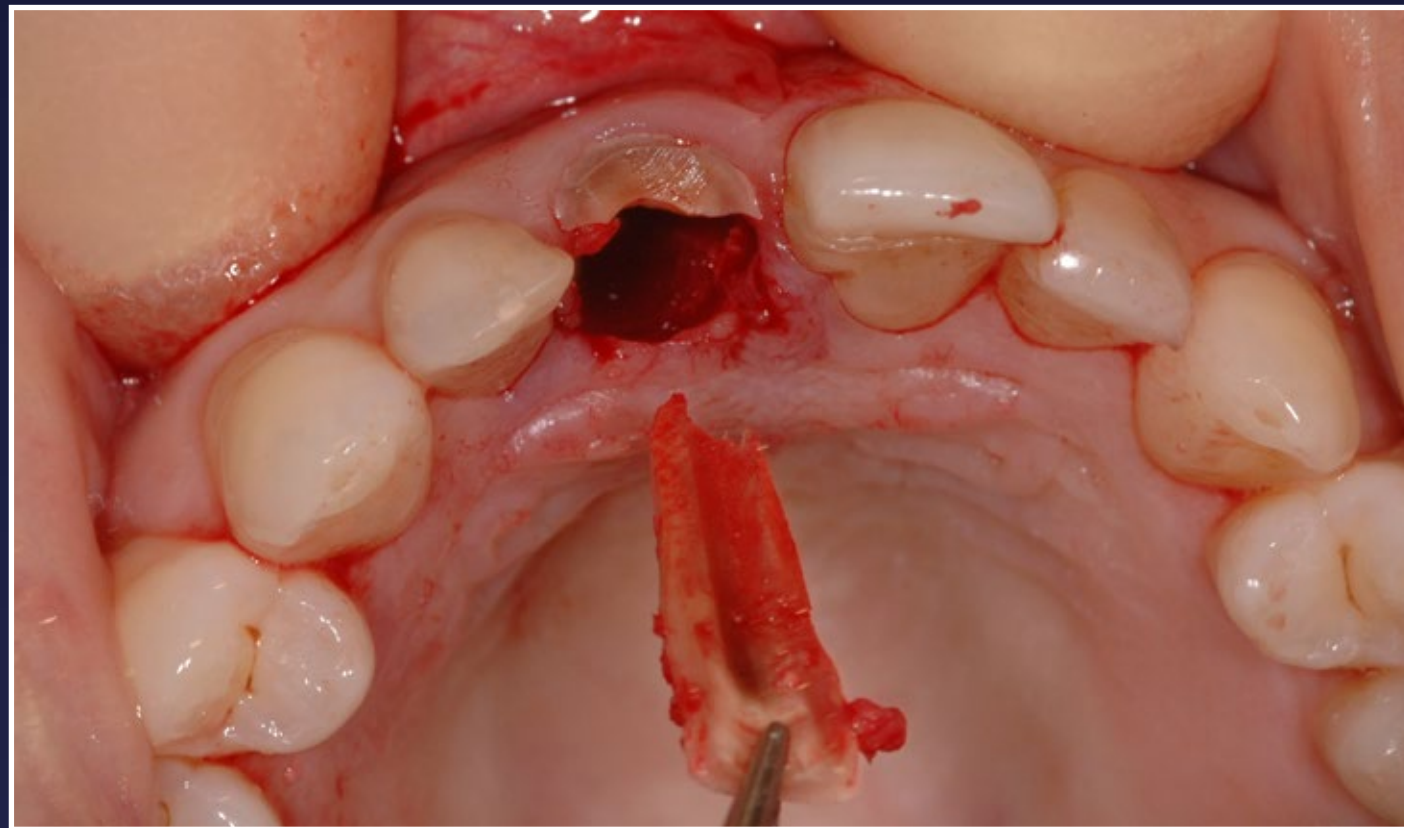


6. Partial extraction therapy preparation

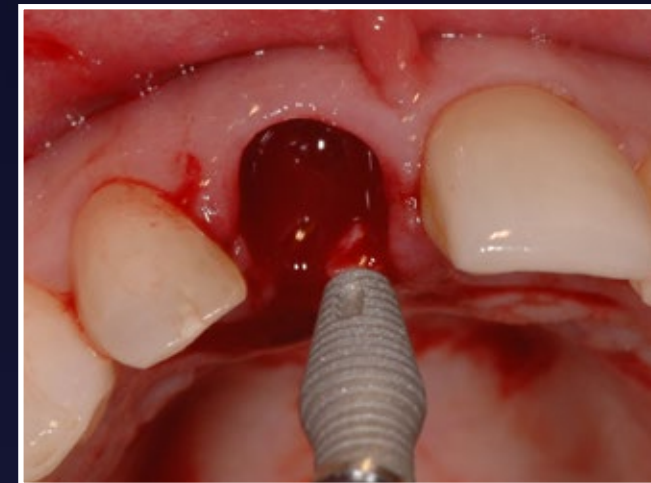




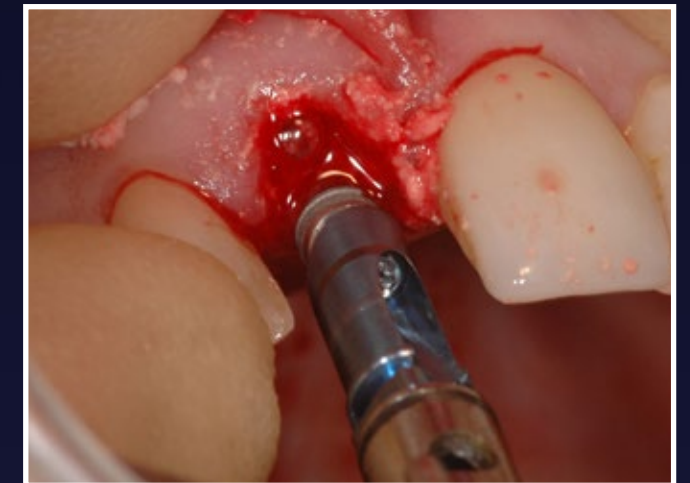7. Partial extraction therapy



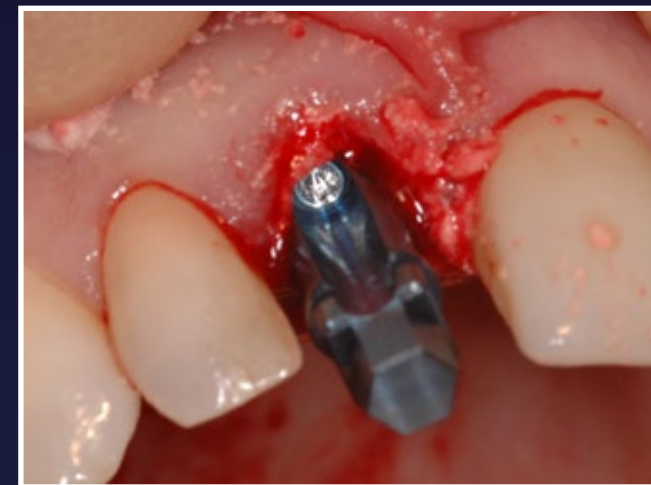
8. Partial extraction therapy



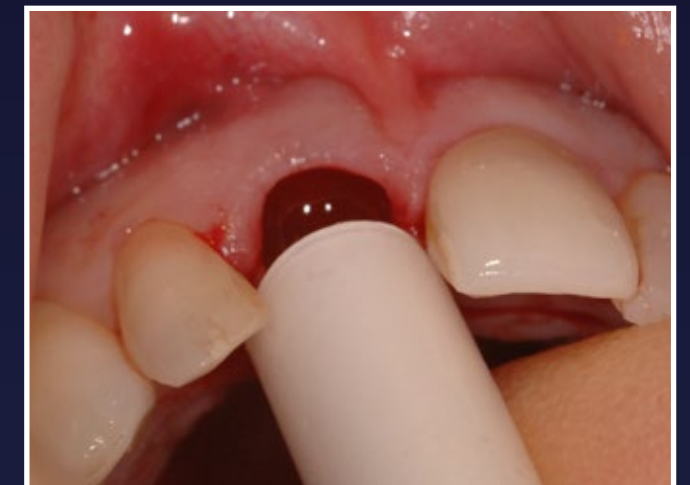9. Fixture placement INVERTA by Southern Implants



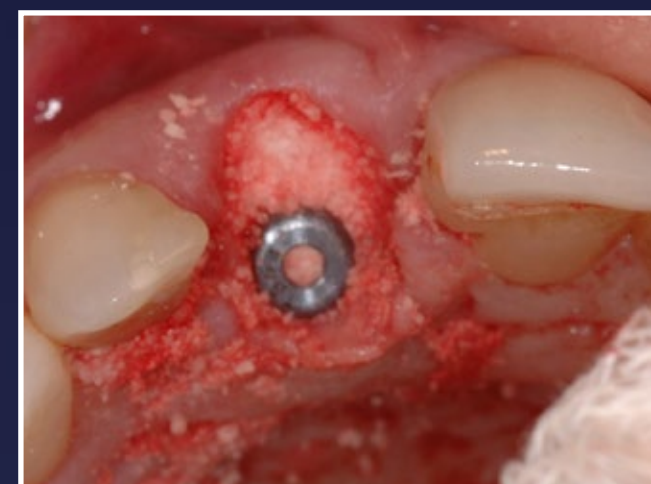10. Fixture placement INVERTA by Southern Implants



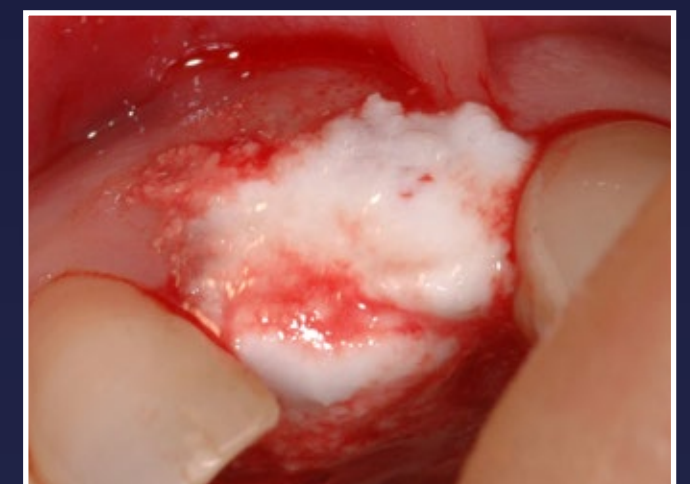11. Fixture placement INVERTA by Southern Implants



12. EthOss in jump gap

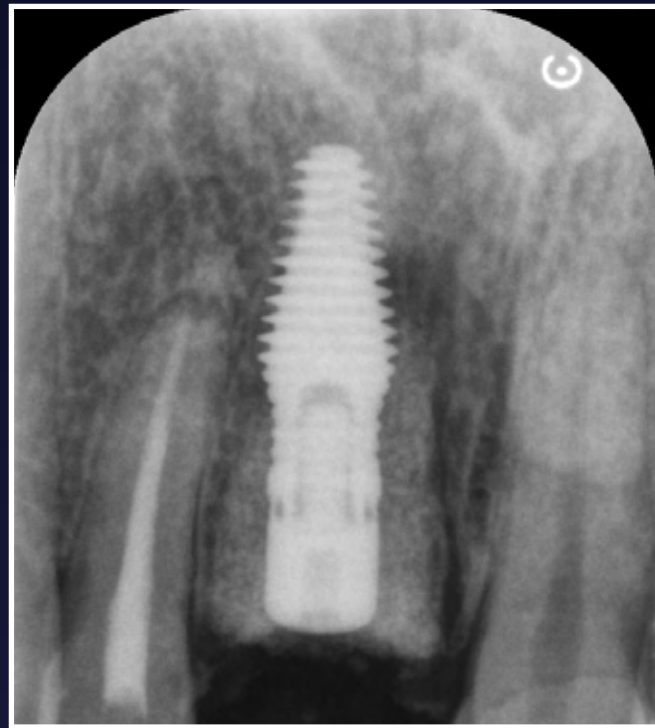


13. EthOss is placed

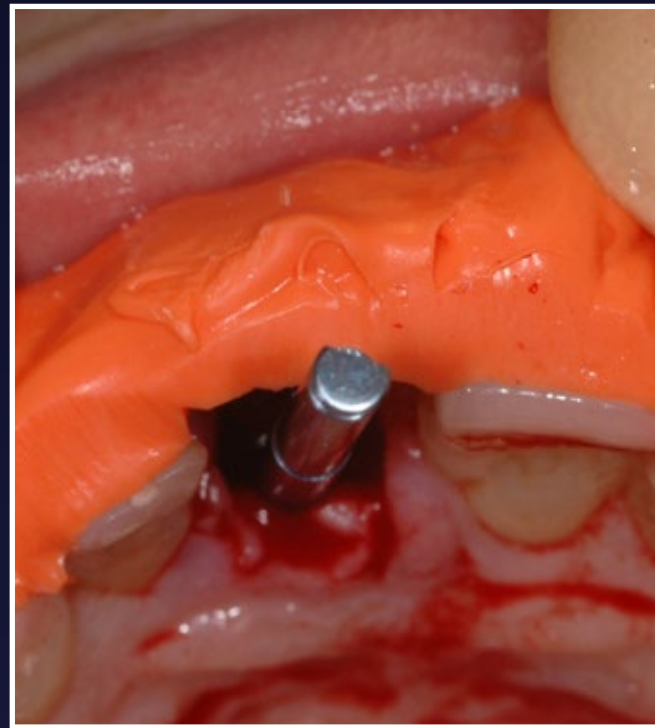


14. Additional EthOss is placed

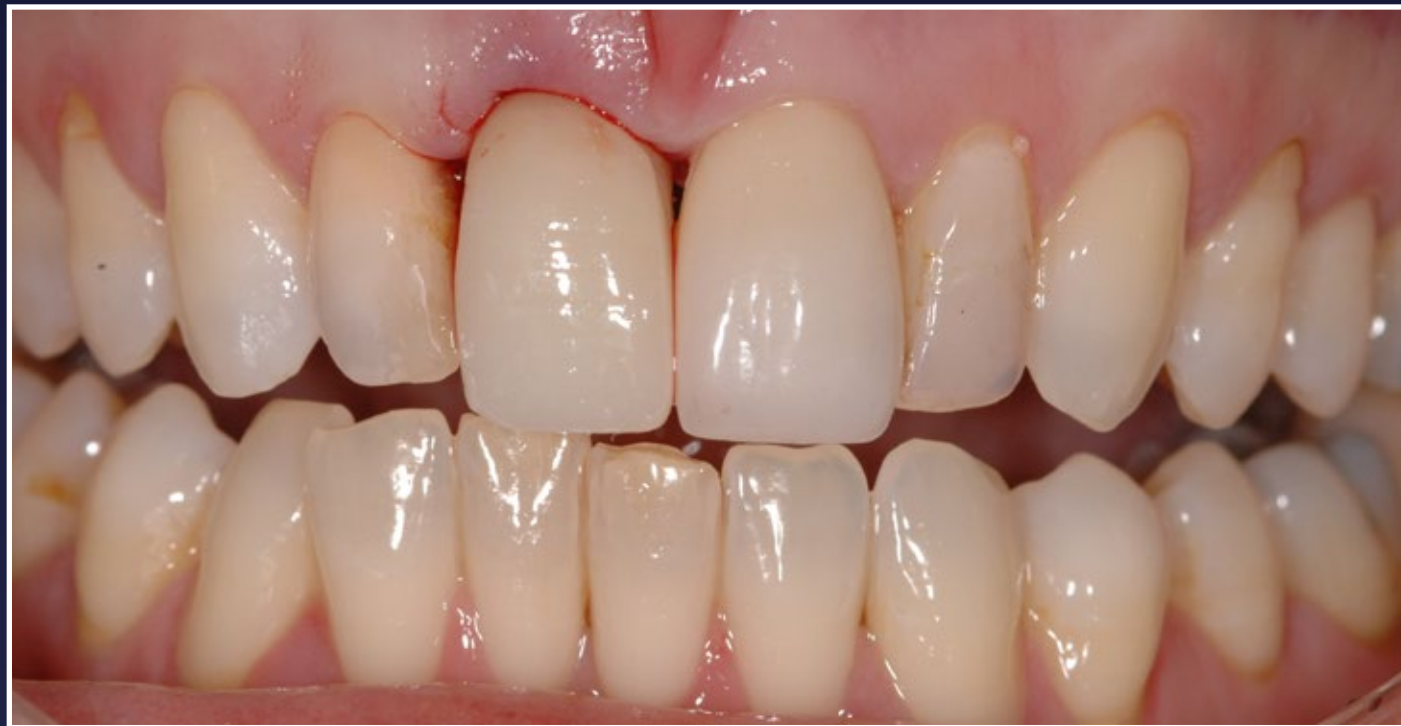



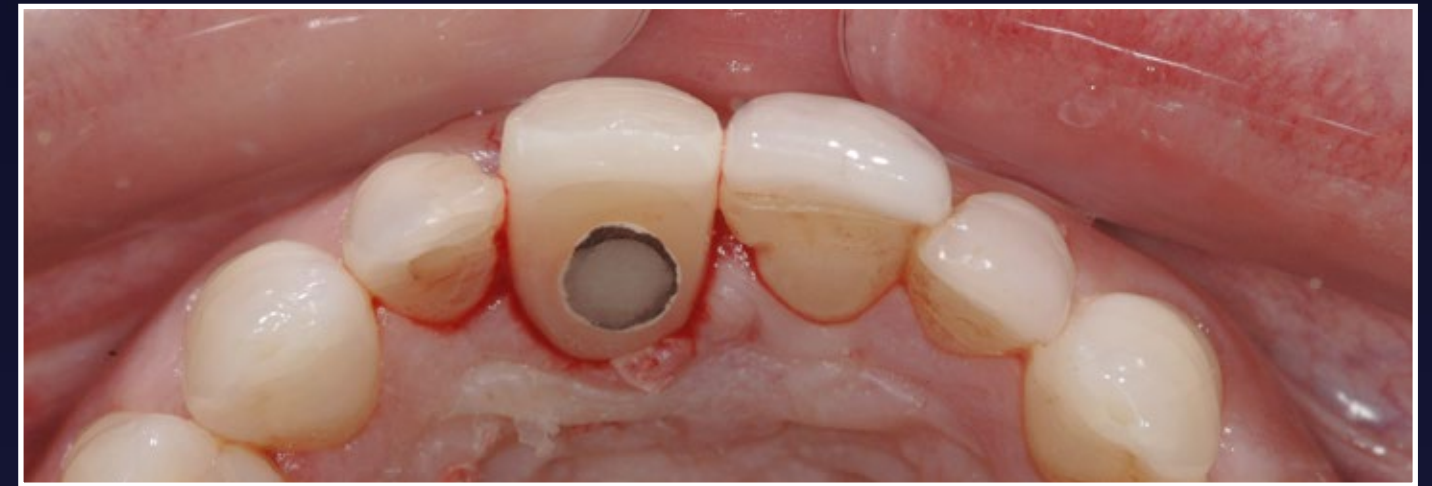15. Fixture placement INVERTA by Southern Implants



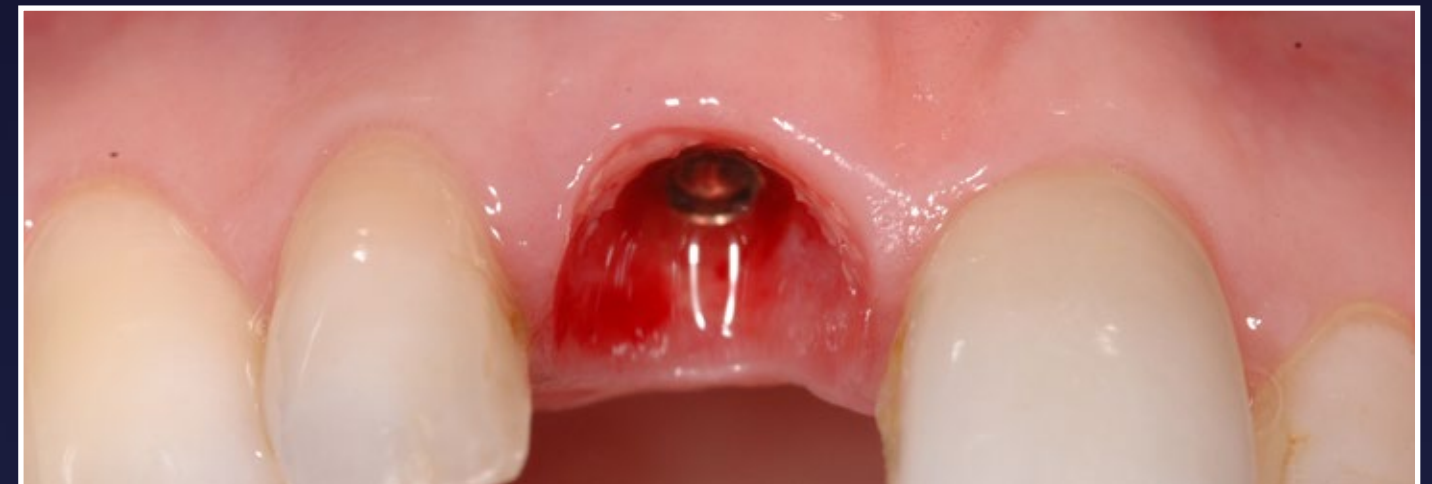16. Silicone key to assess for screw emergence



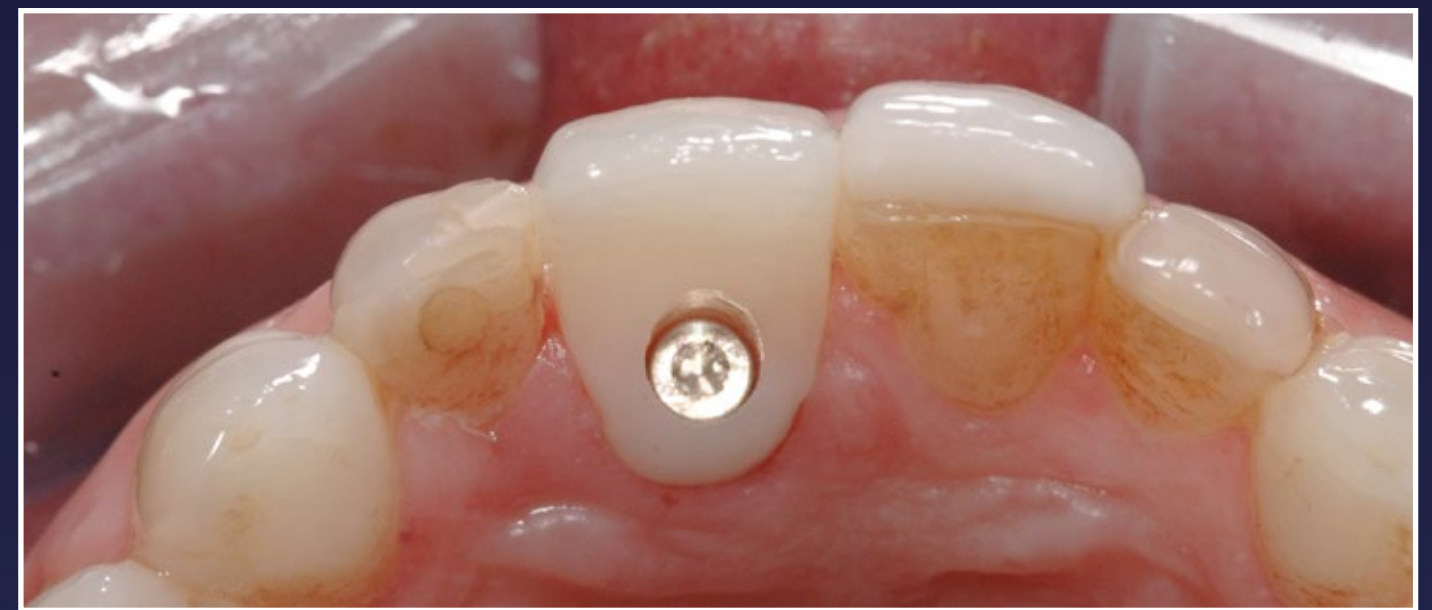17. Immediate restoration



18. Immediate restoration



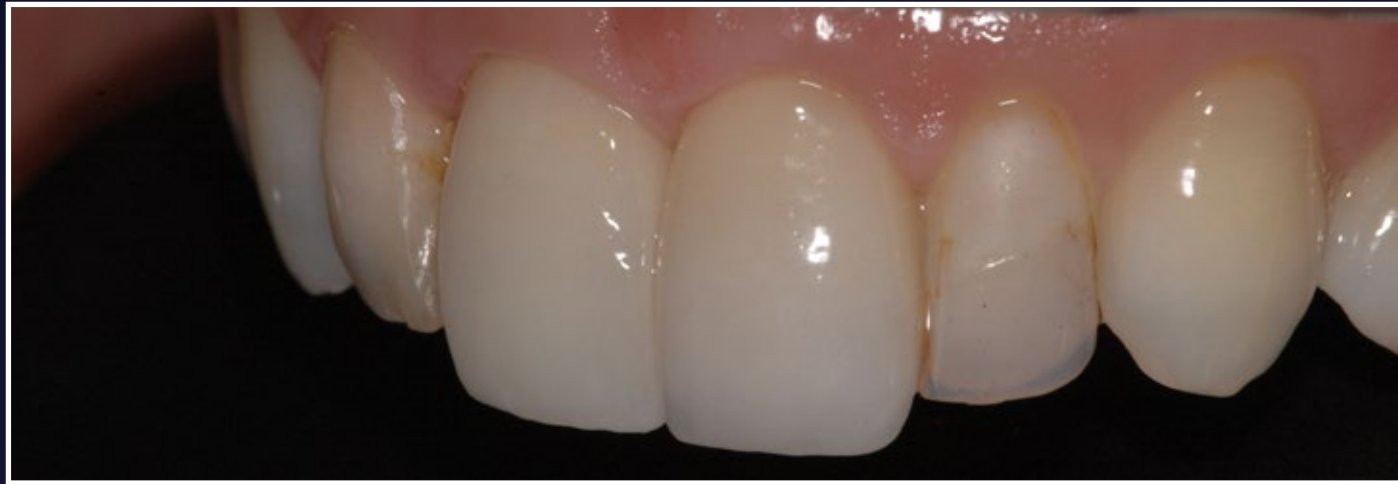19. Immediate restoration



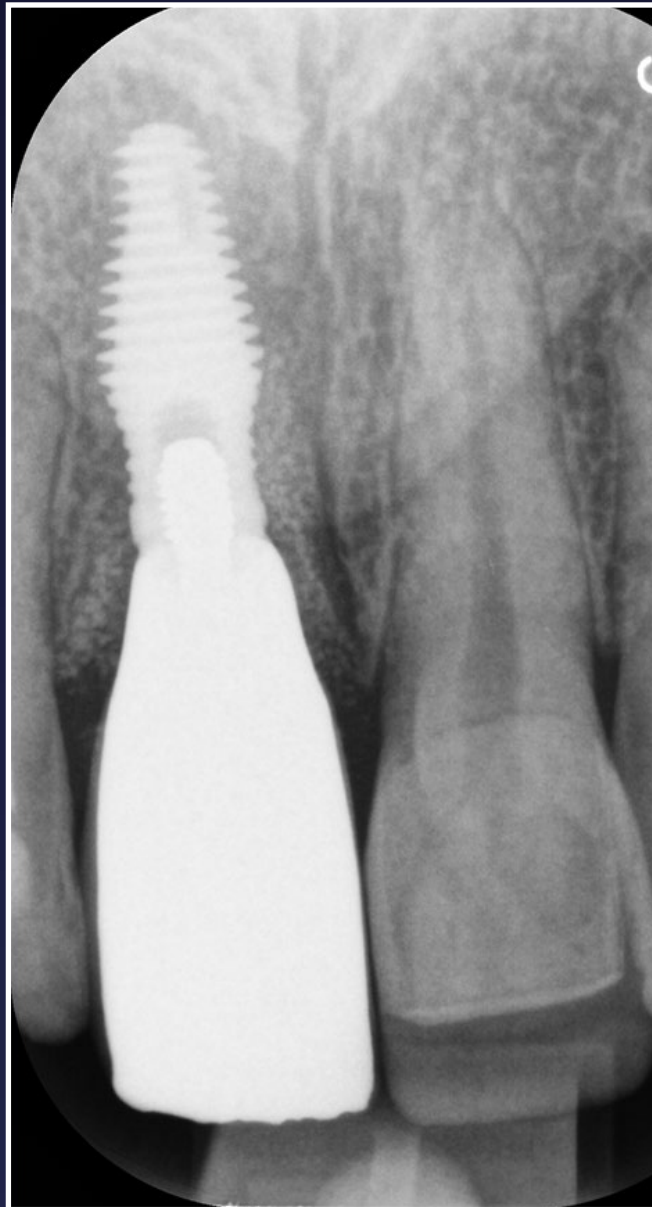
20. Final crown



# GROW YOUR UNDERSTANDING



21. Final crown



22. Restored