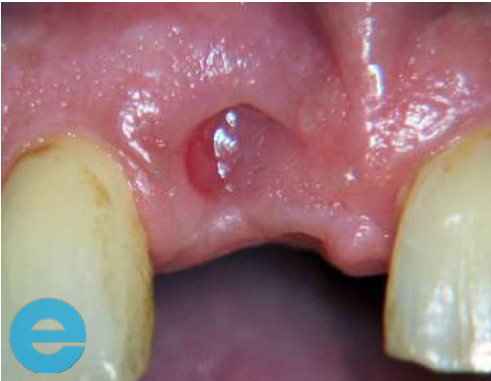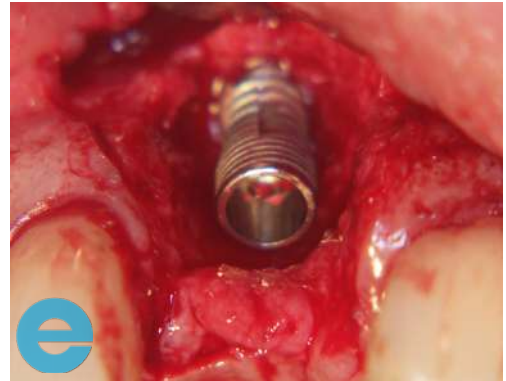


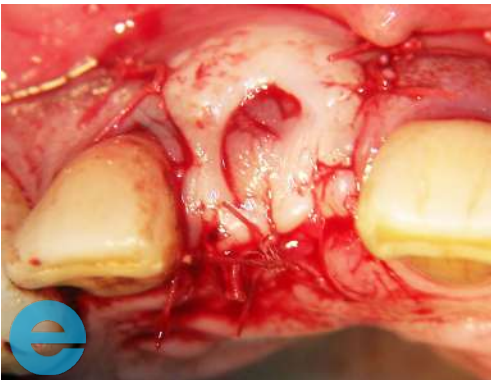# LONG TERM BUCCAL GRAFT



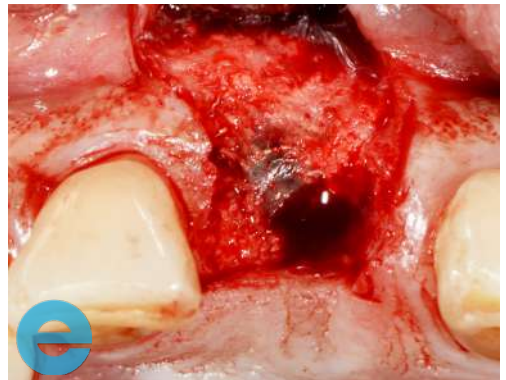1. 4 weeks post extraction, loss of profile



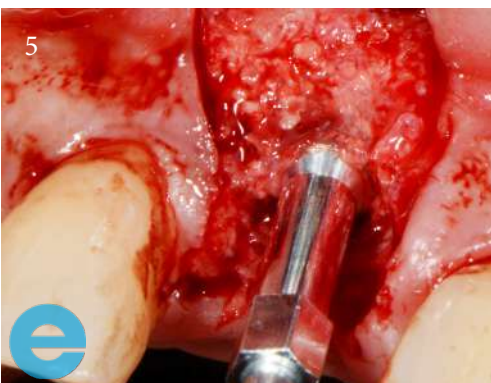2. Placement of implant, site specific flap



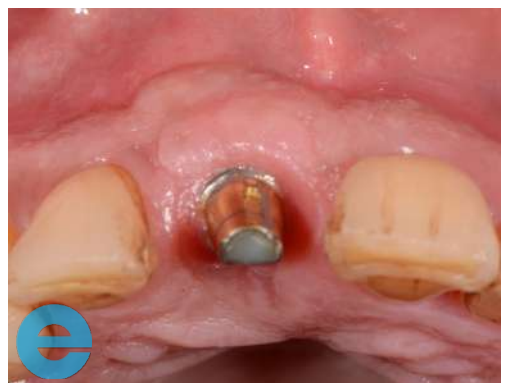3. Sutured closed after grafting with EthOss®



4. Flap raised at 12 weeks to show new host bone (very little remnant graft)

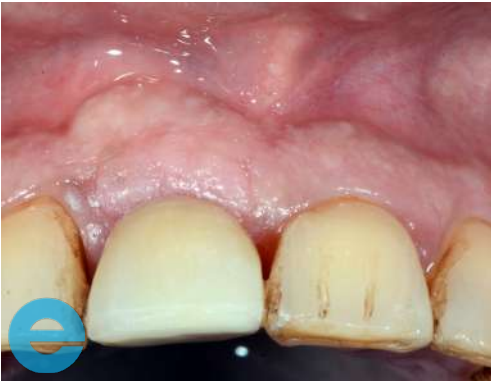

5. Osstell reading 76 ISQ

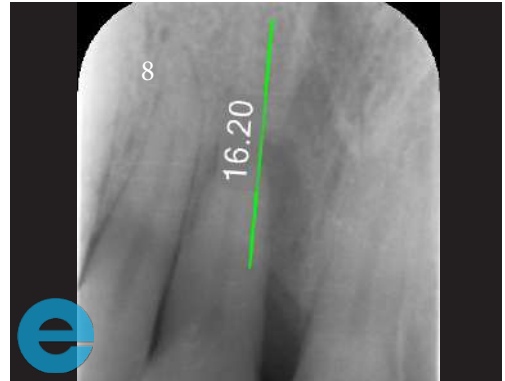


6. Re-cemented at 4 years loaded, showing retained profile

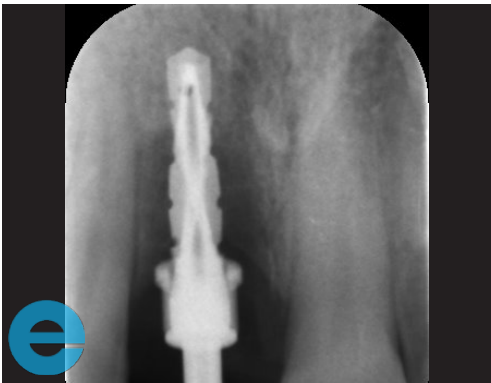
# LONG TERM BUCCAL GRAFT



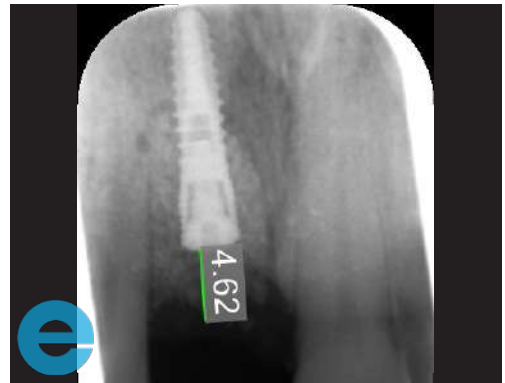7. Good longer term profile retention



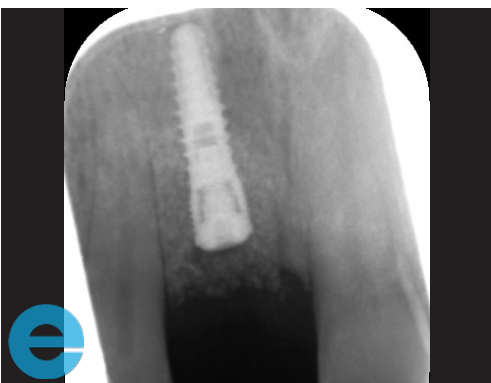8. Tooth to be extracted with bone loss



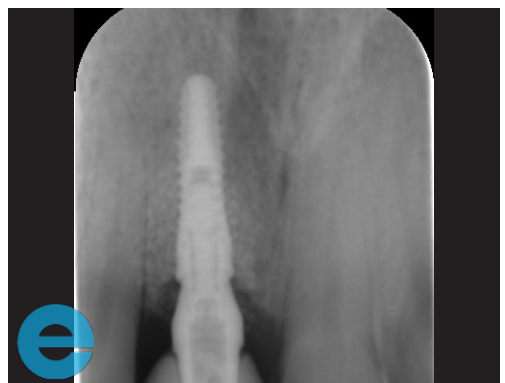9. Pilot measurement



10. Radiograph showing implant placed into 2mm host bone and EthOss® graft



11. Implant ready to load at 7 weeks



12. Radiograph at 4 years showing stable bone



# GROW STRONGER

## USEFUL RESOURCES

### RECOMMENDED CLINICAL PROTOCOL

*Clinical study showcasing recommended clinical protocol for EthOss*

Download

### SURGICAL GUIDELINES

*The official recommended guide on how to use EthOss*

Download

### HOW TO MIX ETHOSS

*Explainer video*

Watch