

PATIENT MEDICAL HISTORY

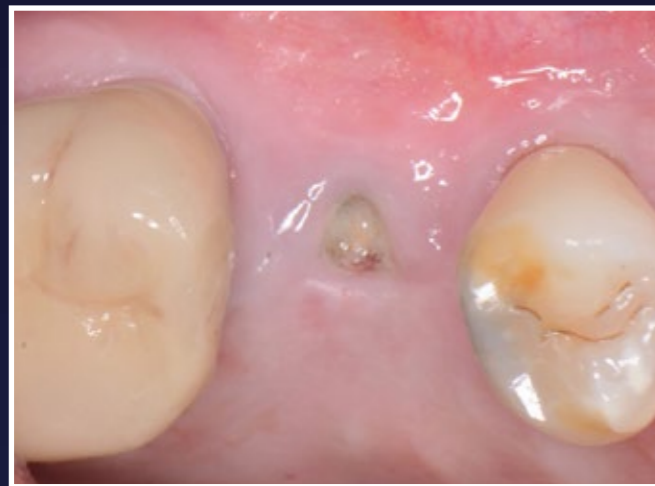Male  
61 years old

Referred from dentist to remove fractured screw and restore, but was unable to remove the screw and due to Peri-implantitis it was decided to remove the implant as well.

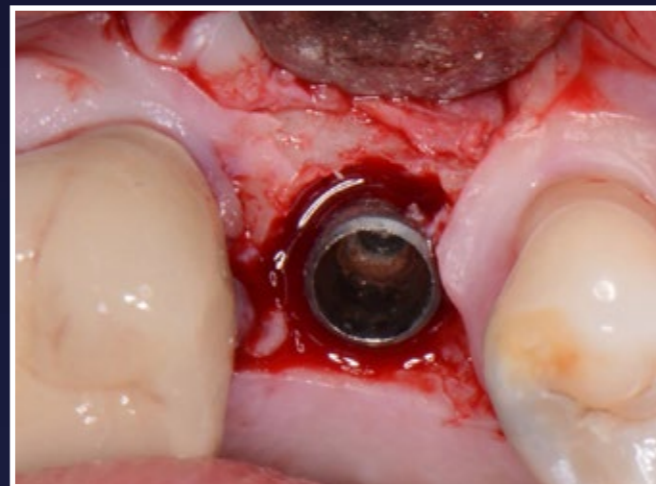
Case from Dr Peter Fairbairn,  
London, UK



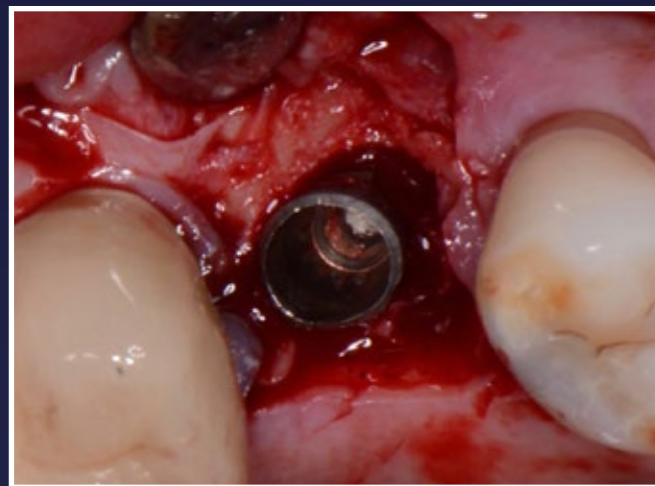
🇬🇧 Dr Peter Fairbairn



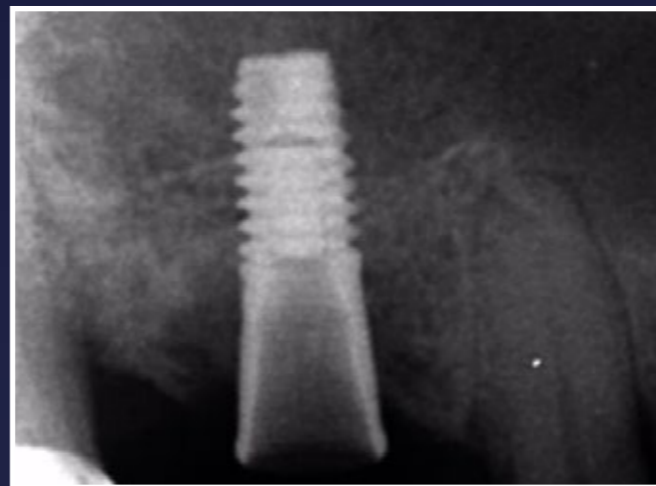1. Fractured screw, implant could not be removed



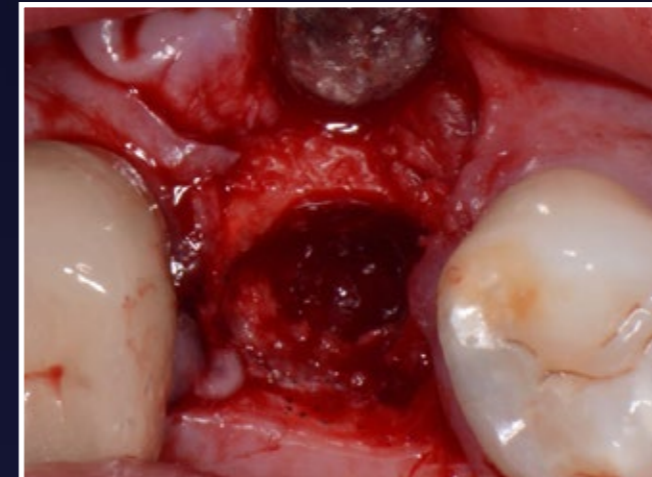
2. Peri-implantitis bone loss is visible



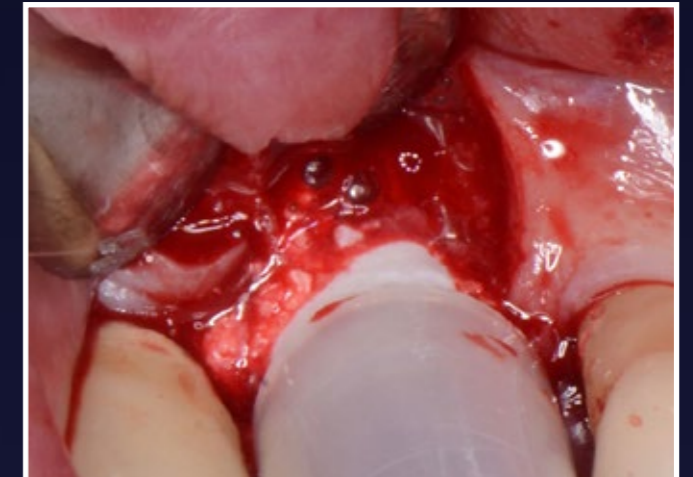
3. Reasonable bone loss is visible so need to remove rather than save



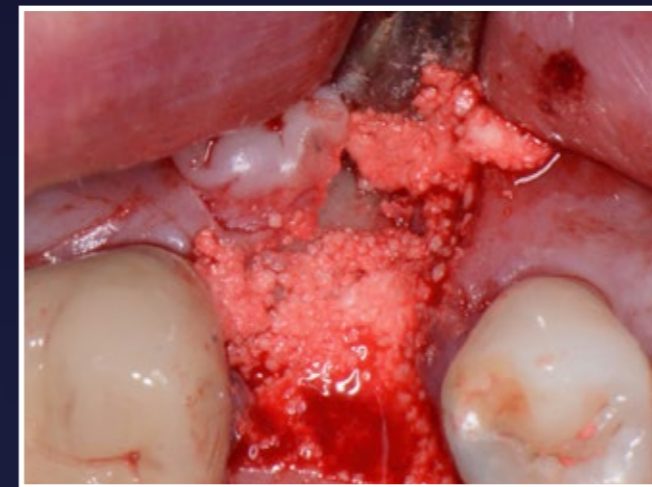4. Radiograph confirms need to removed



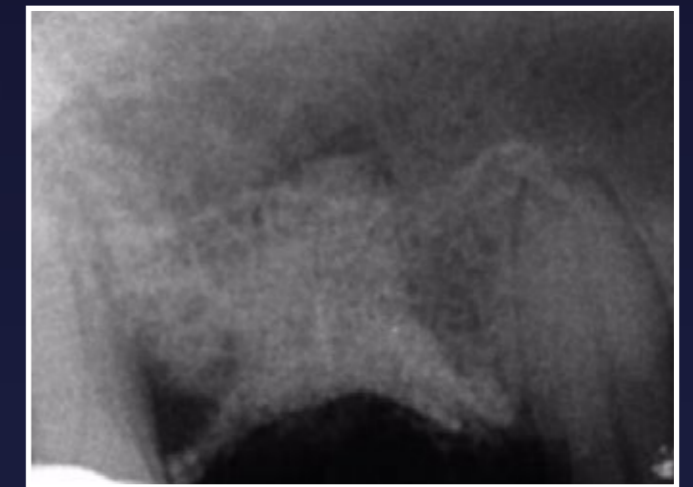5. Resultant defect, slight OA so decided to graft



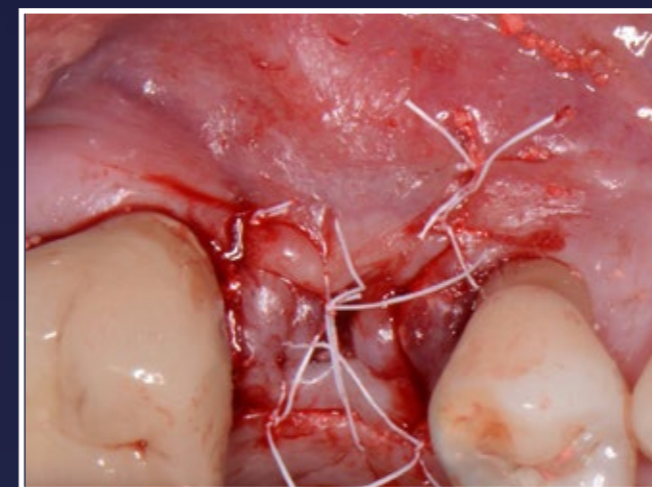
6. EthOss bone graft placed



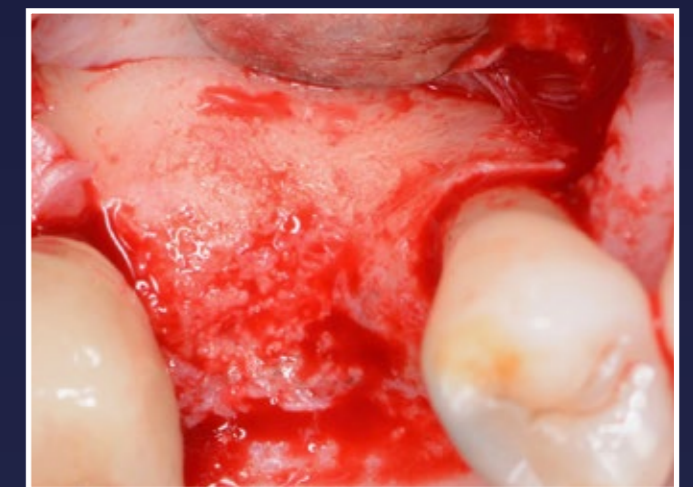7. EthOss in place - stabilise with gauze



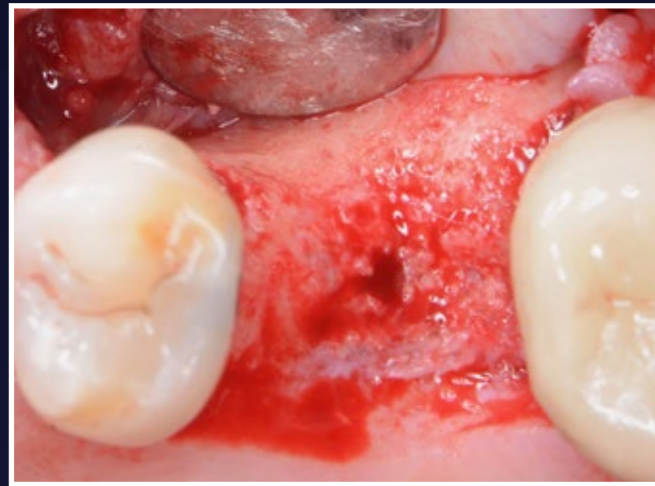8. Radiograph showing stable material - did not push too hard as small OA tear



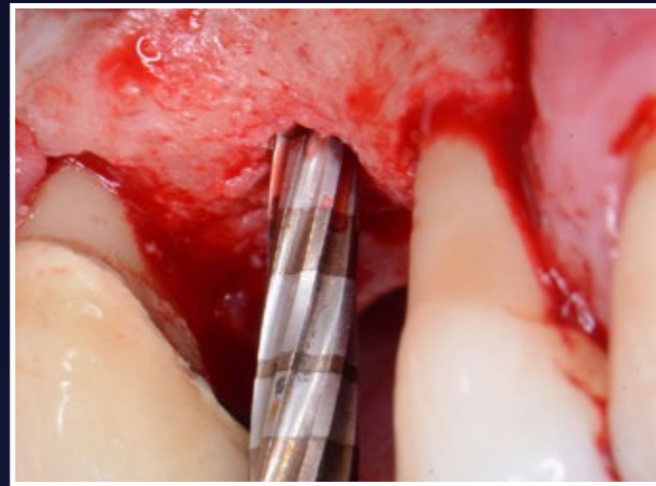
9. Sutured closed



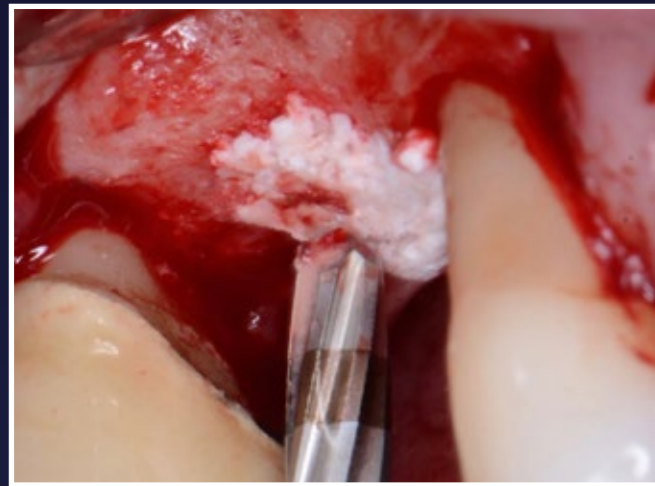
10. 10 weeks post-op - excellent new host regenerated bone



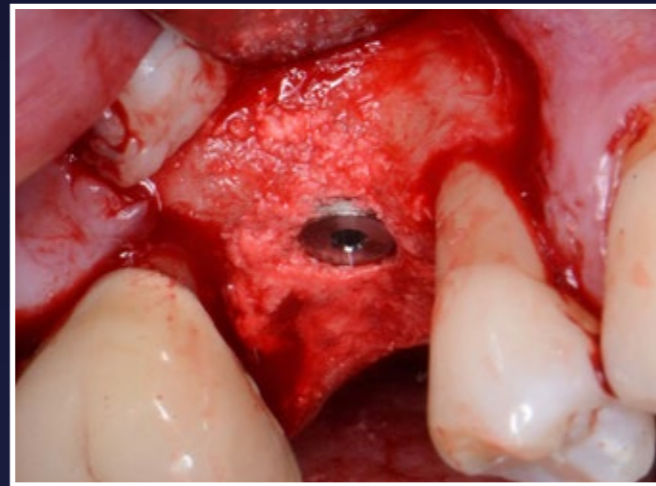
11. Site regeneration



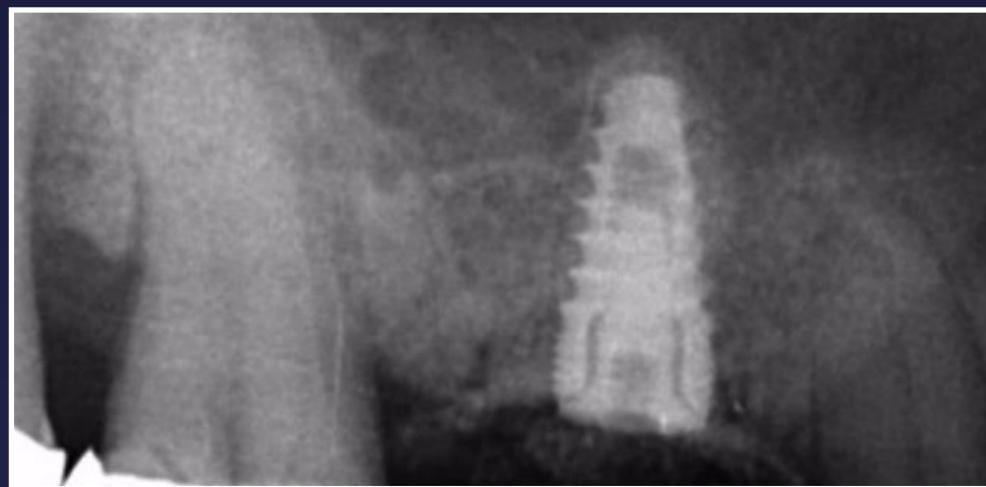12. Versah Drill to help with Internal lift



13. Place drier mix of EthOss into the sinus site

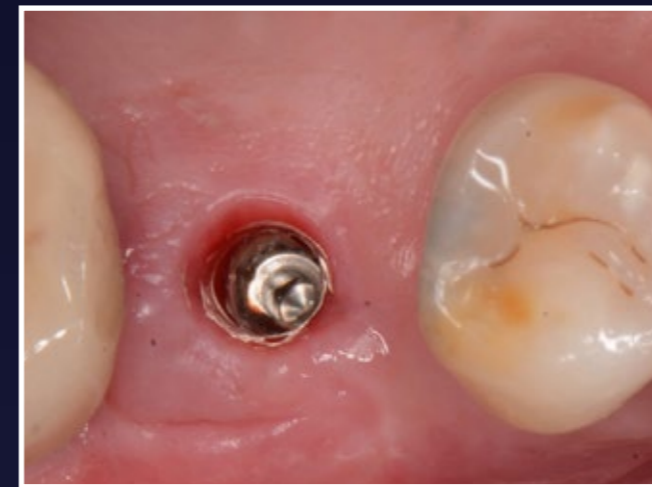

14. Paltop Dynamic implant placed

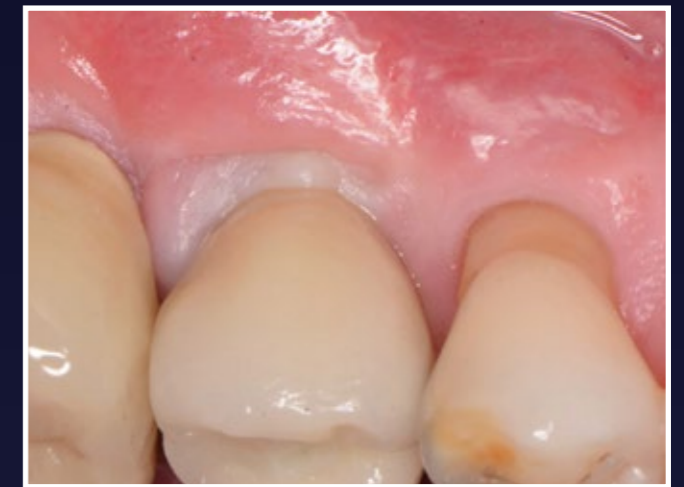

15. Radiograph shows small lift with Versah

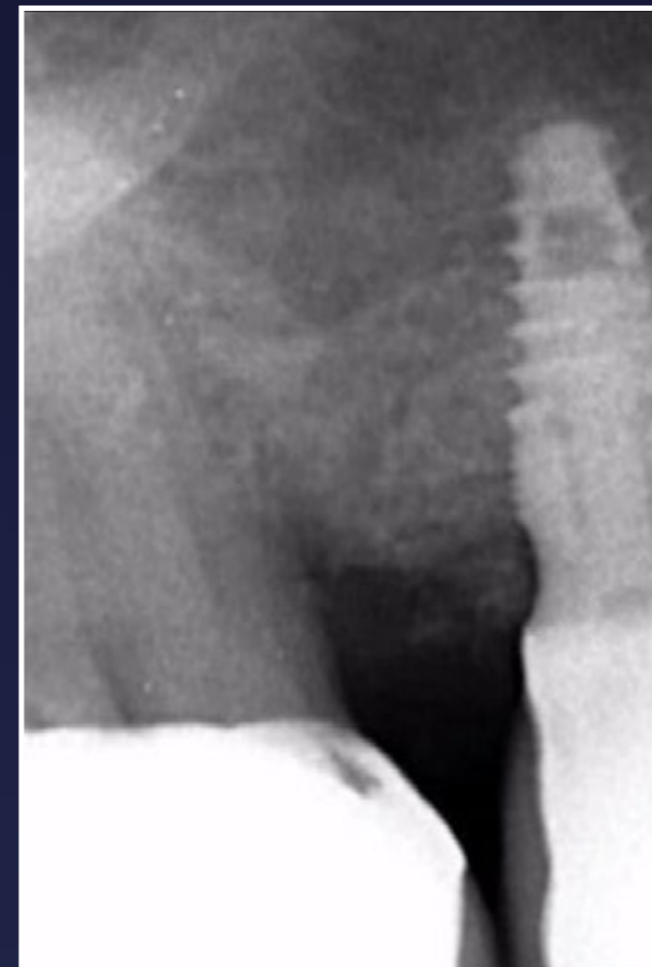RESULTS



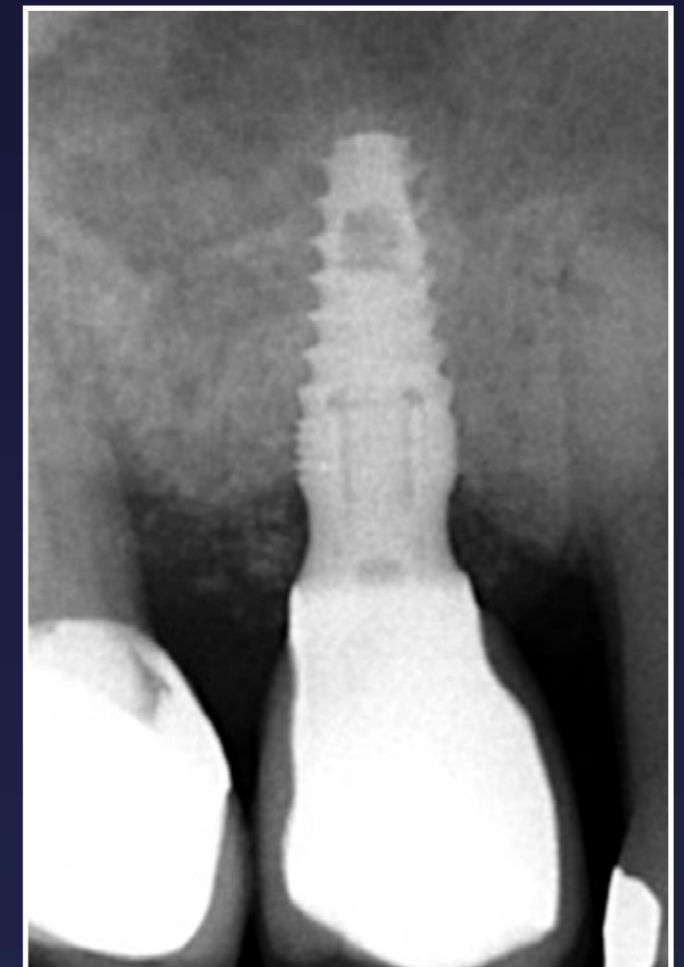
16. Loading 14 weeks post-op. Note healthy attached keratinised tissue



17. Screw retained crown fitted



18. Radiograph shows successful outcome - nice platform switch



19. Radiograph at 4 months showing stability of hard tissue