

See discussions, stats, and author profiles for this publication at: <https://www.researchgate.net/publication/264783270>

Management of peri-implant mucositis and peri-implantitis Case definitions for peri-implant diseases

Article · January 2014

READS

160

5 authors, including:



Filippo Graziani

Università di Pisa

77 PUBLICATIONS 1,067 CITATIONS

SEE PROFILE



Ignacio Sanz Sánchez

Complutense University of Madrid

32 PUBLICATIONS 205 CITATIONS

SEE PROFILE



David Herrera

Complutense University of Madrid

135 PUBLICATIONS 2,834 CITATIONS

SEE PROFILE



Mariano Sanz

Complutense University of Madrid

338 PUBLICATIONS 6,646 CITATIONS

SEE PROFILE

Management of peri-implant mucositis and peri-implantitis

ELENA FIGUERO, FILIPPO GRAZIANI, IGNACIO SANZ, DAVID HERRERA & MARIANO SANZ

The use of dental implants for supporting prosthetic rehabilitations has shown highly satisfactory results regarding restoration of the patient's function and esthetics, as well as in terms of long-term survival (2). However, dental implants can lose supportive bone, even in cases of successful osseointegration. The main cause of this loss of crestal bone surrounding an implant is local inflammation during the course of peri-implant diseases. These diseases are defined as inflammatory lesions of the surrounding peri-implant tissues and include two different entities: peri-implant mucositis and peri-implantitis (7). Peri-implant mucositis is defined as an inflammatory lesion limited to the surrounding mucosa of an implant, whereas peri-implantitis is an inflammatory lesion of the mucosa that affects the supporting bone with loss of osseointegration (19).

Both peri-implant diseases are infectious in nature and are caused by bacteria from dental biofilms (18). A recent review concluded that the microbiota associated with peri-implant diseases is a mixed anaerobic infection, with a composition similar to that of the subgingival microbiota of chronic periodontitis, although some cases of peri-implant disease may be specifically associated with other bacterial species, such as *Peptostreptococcus* spp. or *Staphylococcus* spp. (22). Although bacterial pathogens represent the initial step of the disease process, the ensuing local inflammatory response and the misbalance in the host–parasite interaction seem key in the pathogenesis of the tissue destruction defining these diseases. Different risk indicators that may influence the pathogenesis in favor of tissue destruction include poor oral hygiene, a history of periodontitis and cigarette smoking. Less evidence has been demonstrated for the role of diabetes and alcohol consumption (13). The possible role of other factors, such as genetic traits, the implant surface or the lack of keratinized mucosa, are also under investigation (63).

Different methods have been used to assess peri-implant tissue health and to diagnose these disease entities. These methods include peri-implant probing, analyses of peri-implant crevicular fluid or saliva, evaluation of the peri-implant microbiota and radiographic evaluation of the peri-implant bone levels. The current consensus indicates that changes in probing depth, and the presence of bleeding on probing and suppuration, must be evaluated to assess the peri-implant tissues, whilst radiographs should be used to confirm peri-implant bone loss (13, 57).

Peri-implant diseases are important disease entities as a result of their high prevalence and the lack of a standard mode of therapy (7, 35). Although the current epidemiological data are limited, peri-implant mucositis has been reported to affect 80% of the subjects with dental implants and 50% of the implants, whilst peri-implantitis affects 28–56% of the subjects and 12–43% of the implants. This reviews aims to describe the different approaches to treat peri-implant diseases and to evaluate critically the evidence available to support the different proposed therapies. With this purpose we used a recently published systematic review from our research group in which only controlled studies were considered (11). In addition, relevant recently published studies were included.

Case definitions for peri-implant diseases

Table 1 depicts the different diagnostic criteria used to define peri-implant mucositis. Although the definitions are heterogeneous, all but one (28) of the selected studies included bleeding on probing of the peri-implant mucosa. Peri-implantitis definition also varied across studies (see Table 2) but normally included the presence of bleeding on probing, deep probing depth (Fig. 1) and bone loss, although using

Table 1. Diagnostic criteria for peri-implant mucositis

Author (reference)	Mucositis definition
Heitz-Mayfield et al. (14)	Bleeding on probing and no bone loss
Thone-Muhling et al. (62)	Bleeding on probing and/or gingival index ≥ 1 on at least one site and no bone loss in the previous 2 years
Ramberg et al. (29)	Bleeding on probing
Porras et al. (28)	Plaque, probing depth ≤ 5 mm and evidence of inflammation by modified bleeding index
Felo et al. (10)	Bleeding on probing, modified gingival index > 1.5 , modified plaque index > 1.5 and probing depth ≤ 3 mm
Ciancio et al. (6)	Bleeding on probing, modified gingival index > 1.5 and modified plaque index > 1.7

different threshold values (Fig. 2). These values for probing depth were always > 3 mm and ranged from 1.8 to 3 mm for bone loss. Only one study had exclusively a bone-loss criterion ($> 50\%$) (5).

Treatment approaches for peri-implant diseases

Evaluation of the different therapies is based on a recently published systemic review of controlled studies with the addition of recently published trials (11). The evaluation has been divided into three parts: therapy of peri-implant mucositis; nonsurgical therapy of peri-implantitis; and surgical therapy of peri-implantitis. The treatment of peri-implant lesions usually includes mechanical debridement of biofilm and calculus. This therapy may be rendered through professional intervention or by the patient using home-use oral-hygiene techniques. In addition, adjunctive antimicrobials, such as antiseptics, or local or systemic antibiotics, may be used in conjunction with mechanical debridement alone or with mechanical debridement and mechanical plaque-control protocols. Furthermore, it is necessary to highlight the importance of the subject's own control of infection, through motivation and proper oral-hygiene practices, in order to prevent peri-implant biofilm and calculus reforming around the implant.

Peri-implant mucositis therapy

Peri-implant mucositis therapy: professional interventions

Mechanical debridement

Mechanical debridement alone involves the supra- and subgingival debridement of the implant surface,

the implant neck and the abutment. The main objective is to remove peri-implant biofilm and calculus without altering the implant surface, with the goal of re-establishing a healthy peri-implant mucosa (12, 14). Different debridement systems have been evaluated, normally in combination with polishing the implant surface and/or the prosthetic components using a rubber cup and a polishing paste or using an abrasive sodium-carbonate air-powder system. Such debridement systems include curettes and ultrasonic devices with polyether-etherketone-coated tips.

Curettes. Curettes of different materials have been produced for use specifically to debride implant surfaces:

- steel curettes have an external hardness higher than titanium and accordingly are not indicated for cleaning titanium implants. Nevertheless, they can be used on other implant surfaces, such as titanium zirconoxide or titanium oxinitride (45).
- titanium-coated curettes have a similar hardness to the titanium surface and thus do not scratch its surface (12) (Fig. 3).
- carbon-fiber curettes are softer than the implant surface and therefore remove bacterial deposits without damaging the surface, although they break easily (14) (Fig. 4).
- teflon curettes have similar properties to carbon-fiber curettes and they have been proposed for use in combination with air-abrasive systems (21) (Fig. 5).
- plastic curettes are the most fragile of all curette types and have limited debriding capacity (28) (Fig. 6).

Ultrasonic devices. Ultrasonic devices with polyether-etherketone-coated tips have been used to debride the implant surface (Fig. 7). The polyether-etherketone-coated tip is a modified tip made of a high-tech plastic

Table 2. Diagnostic criteria for peri-implantitis

Author (reference)	Peri-implant disease definition
Schar et al. (44)	Probing depth 4–6 mm, bleeding on probing at one or more sites and radiographic bone loss of 0.5–2 mm
Renvert et al. (33)	Probing depth ≥ 5 mm, bleeding on probing/suppuration and radiographic bone loss >3 mm
Renvert et al. (37) Persson et al. (25)	Probing depth ≥ 4 mm, bleeding on probing/suppuration and radiographic bone loss <2.5 mm
Renvert et al. (31)	Probing depth ≥ 4 mm, bleeding on probing/suppuration, bone loss <1.8 mm (three threads) and the presence of <i>Porphyromonas gingivalis</i> , <i>Prevotella intermedia</i> , <i>Fusobacterium nucleatum</i> , <i>Tannerella forsythia</i> , <i>Aggregatibacter actinomycetemcomitans</i> and <i>Treponema denticola</i>
Renvert et al. (30, 32)	Probing depth ≥ 4 mm, bleeding on probing/suppuration, bone loss fewer than three threads and the presence of <i>Porphyromonas gingivalis</i> , <i>Prevotella intermedia</i> , <i>Fusobacterium nucleatum</i> , <i>Tannerella forsythia</i> , <i>Aggregatibacter actinomycetemcomitans</i> and <i>Treponema denticola</i>
Schwarz et al. (47, 56)	Moderate (>4 mm) to advanced (>7 mm) probing depth, bone loss, bleeding on probing/suppuration, plaque index <1 and keratinized mucosa
Karring et al. (15)	Probing depth ≥ 5 mm, bleeding on probing, radiographic bone loss = 1.5 mm and exposed implant threads
Aghazadeh et al. (1)	Probing depth ≥ 5 mm, bleeding on probing/suppuration, radiographic bone loss ≥ 2 mm and angular peri-implant bone defects ≥ 3 mm
Schwarz et al. (53)	Probing depth >6 mm and radiographic bone loss >3 mm
Roos-Jansaker et al. (41)	Bleeding on probing/suppuration and bone loss more than three threads
Deppe et al. (8)	Probing depth >4 mm or bleeding on probing; vertical bone loss
Schwarz et al. (48, 52, 55)	Probing depth >6 mm and radiographic bone loss >3 mm
Romeo et al. (38, 39)	Probing depth >4 mm, bleeding on probing/suppuration and peri-implant radiolucency

material and has a stainless-steel core. It debrides the implant surface easily and is comfortable for the patient. The purpose of this device is to debride plaque and calculus from all around the implant neck and the abutment, leaving a clean and smooth surface (62).

Adjunctive Antimicrobials

Antiseptics. Antimicrobials, including chlorhexidine-based products, have been used as adjuncts to mechanical debridement to prevent recolonization of bacteria after mechanical treatment and to support the patient's oral-hygiene practices.

Different chlorhexidine formulations and dosages have been evaluated:

- 20 ml of 0.12% chlorhexidine mouth rinse, once daily for 3 months after professional prophylaxis (10).
- powered subgingival irrigation with 100 ml of 0.06% chlorhexidine, once daily for 3 months after professional prophylaxis (10).
- brushing with 1 cm of 0.5% chlorhexidine gel around the implants (see Fig. 8), twice daily for 4 weeks (14).
- rinsing with 10 ml of 0.12% chlorhexidine plus brushing with 0.12% chlorhexidine gel, twice daily for 10 days after treatment (28).

- full-mouth disinfection protocol, after debridement with an ultrasonic device, as follows: subgingival application of 0.1% chlorhexidine gel; brushing the dorsum of the tongue for 1 min with a 1% chlorhexidine gel; spraying each tonsil four times with 0.2% chlorhexidine spray; and rinsing with 0.2% chlorhexidine, twice, for 1 min. During the following 14 days, patients rinsed once daily for 30 s with 0.2% chlorhexidine and sprayed the tonsils once daily with 0.2% chlorhexidine spray (62).

Locally delivered antibiotics. These have been used to increase the antibacterial effect of the mechanical debridement and to prevent bacterial colonization of the implant surface. Locally delivered tetracycline was applied, in monolithic ethylene vinyl acetate fibers containing 25% (weight/volume) tetracycline hydrochloride, as follows: fibers were placed around implants in several circular layers until the peri-implant space was completely filled by the fiber; once placement of the delivery system was complete, an isobutyl cyanoacrylate adhesive was applied at the mucosal margin to secure the fiber (in the event of fiber loss in the 7 days following fiber placement,

Table 3. Nonsurgical treatment of peri-implantitis: interventions and main outcomes of the selected studies

Author (reference)	Follow up	n	Intervention	Probing pocket depth (mm)		Bleeding on probing	
				Baseline	Final	Baseline	Final
Schar et al. (44)	6 months	20	Titanium curettes + glycine-based air-abrasive + diode laser	4.19 (0.55)	3.83 (0.58)	4.03 (1.66)	1.51 (1.41)
		20	Titanium curettes + glycine-based air-abrasive + local minocycline	4.39 (0.77)	3.90 (0.78)	4.41 (1.47)	2.10 (1.55)
Sahm et al. (42)	6 months	15	Carbon-fiber curette + chlorhexidine	4 (0.8)	3.5 (0.8)	95.3 (9.6)	84.3 (15.5)
		15	Glycine-based air-abrasive	3.8 (0.8)	3.2 (0.9)	94.6 (15.8)	51.1 (24.7)
Persson et al. (24)	6 months	21	Air-abrasive	6.2 (1.9)	6.2 (1.9)		
		21	Erbium-doped yttrium aluminium garnet laser	5.9 (1.7)	5.9 (1.7)		
Renvert et al. (33)	6 months	21	Air-abrasive	Change: 0.8 (0.5)			No bleeding on probing: 25%
		21	Erbium-doped yttrium aluminium garnet laser	Change: 0.9 (0.8)			No bleeding on probing: 30.9%
Persson et al. (25)	6 months	17	Titanium curettes	4.0 (0.8)	4.0 (0.8)	1.7 (0.6)	1.2 (0.7)
Renvert et al. (37)		14	Ultrasonic device	4.3 (0.6)	3.9 (0.8)	1.7 (0.9)	1.4 (1)
Renvert et al. (31)	12 months	58 implants	Carbon-fiber curettes + chlorhexidine	3.87 (1.16)	3.72 (1.02)	86.5 (20)	48.1 (21)
		37 implants	Carbon-fiber curettes + local minocycline	3.85 (1.04)	3.55 (0.98)	89.2 (17)	63.5 (19)
Renvert et al. (30)	12 months	14	Carbon-fiber curettes + chlorhexidine	3.9 (0.3)	3.9 (0.4)	86 (14)	78 (13)
		16	Carbon-fiber curettes + local minocycline	3.9 (0.7)	3.6 (0.6)	88 (12)	71 (22)
Renvert et al. (32)	3 months	14	Carbon-fiber curettes + chlorhexidine	3.9 (0.3)	3.9 (0.3)	86 (14)	78 (13)
		16	Carbon-fiber curettes + local minocycline	3.9 (0.3)	3.5 (0.6)	88 (12)	71 (22)
Schwarz et al. (47)	12 months	8	Plastic curettes + chlorhexidine	Moderate: 4.5 (0.8) Moderate: 4.3 (0.5) Advanced: 6.0 (1.3) Advanced: 5.6 (0.9)			
		10	Erbium-doped yttrium aluminium garnet laser	Moderate: 4.6 (0.9) Moderate: 4.1 (0.4) Advanced: 5.9 (0.9) Advanced: 5.5 (0.6)			
Schwarz et al. (56)	6 months	9	Plastic curettes + chlorhexidine	5.5 (1.5)	4.8 (1.4)	80	58
		10	Erbium-doped yttrium aluminium garnet laser	5.4 (1.2)	4.6 (1.1)	83	31

Table 3. (Continued)

Author (reference)	Follow up	n	Intervention	Probing pocket depth (mm)		Bleeding on probing	
				Baseline	Final	Baseline	Final
Karring et al. (15)	6 months	11	Carbon-fiber curettes	6.2 (1.6)	6.3 (2.2)	72.7	81.8
		11	Ultrasonic device	5.8 (1.1)	5.8 (1.2)	63.6	36.4
Buchter et al. (5)	4.5 months	14	Plastic curettes	5.68 (0.28)	5.4 (0.34)	0.63 (0.1)	0.5 (0.1)
		14	Plastic curettes + doxycycline	5.64 (0.32)	4.49 (0.29)	0.54 (0.1)	0.27 (0.1)

Probing pocket depth and bleeding on probing values are given as mean or mean (standard deviation).

another fiber was placed); 10 days after initial placement, the fibers were removed (45).

Systemic antibiotics. Systemic antimicrobials have been administered adjunctively to mechanical debridement in order to achieve effective antimicrobial levels in the peri-implant crevicular fluid and therefore to support the antibacterial mechanical effect. Different antibiotics, such as azithromycin, 500 mg/day for 4 days, have been utilized in this respect (12).

Peri-implant mucositis therapy: home-use oral-hygiene interventions

Mechanical plaque control

Mechanical plaque control may involve the use of manual or powered toothbrushes as well as interproximal aids. Its importance should be highlighted because the long-term success of dental implants will depend on an effective peri-implant supportive therapy, in which plaque control around implants is key for both the primary prevention of peri-implant mucositis and its secondary prevention once treated. The following recommendations are usually found in protocols for primary and secondary prevention of peri-implant mucositis:

- manual squish grip brush, to be used twice daily for 30 s during a period of 6 weeks after professional removal of plaque from the implant abutments (60).
- soft manual toothbrush and dental floss, or specialized implant dental floss stocked by the various research sites and end-tuft brushes or interproximal brushes. This protocol of supportive therapy has been used twice daily for a period of 6 years (65).
- powered toothbrush, to be used twice daily for 30 s for a period of 6 weeks after professional removal of plaque from the implant abutments. It gives a three-dimensional brushing action, coupling sonic frequency and high-speed oscillation to provide deeper dental and peri-implant cleaning (60).
- counter-rotational powered brush. This has 10 spaced tufts of bristles that rotate 1.5 turns before reversing for another 1.5 turns. This reverse movement is intended to increase the scrubbing action and to force bristles into interproximal and subgingival areas. Adjacent tufts counter-rotate relative to each other, which has a stabilizing effect when the brush is placed on a given site. The bristle configuration is designed to reach between

Table 4. Surgical treatment of peri-implantitis: interventions and main outcomes of selected studies

Author (reference)	Follow up	n	Decontamination	Intervention	Probing pocket depth (mm)		Bleeding on probing	
					Baseline	Final	Baseline	Final
Aghazade et al. (1)	12 months	22	Hydrogen peroxide (3%)	Access flap surgery + autologous bone	6.0 (1.3)	3.8 (0.2)	87.5 (20.1)	48.4 (5.4)
		23		Access flap surgery + Bio-Oss	6.2 (1.4)	3.3 (0.2)	79.4 (28.9)	26.7 (4.7)
Schwarz et al. (51)	24 months	14	Plastic curette + saline	Access flap surgery + implantoplasty + BioOss + resorbable membrane	5.2 (1.5)	3.7 (1.1)	100 (0.0)	45.1 (30.4)
		10	Erbium-doped yttrium aluminium garnet laser		4.9 (1.4)	3.8 (1.3)	96.6 (10.6)	21.6 (33.3)
Schwarz et al. (53)	6 months	15	Plastic curette + saline	Access flap surgery + implantoplasty + BioOss + resorbable membrane	5.5 (1.8)	3.1 (0.6)	100 (0.0)	45.0 (31.2)
		15	Erbium-doped yttrium aluminium garnet laser		5.1 (1.6)	3.4 (0.6)	93.3 (18.7)	45.5 (33.0)
Schwarz et al. (52)	48 months	9	Plastic curette + saline	Access flap surgery + nanocrystal hydroxyapatite	6.9 (0.6)	5.8 (0.7)	80	48
		11		Access flap surgery + BioOss + resorbable membrane	7.1 (0.7)	4.6 (0.9)	79	28
Schwarz et al. (55)	24 months	9	Plastic curette + saline	Access flap surgery + nanocrystal hydroxyapatite	6.9 (0.6)	5.4 (0.7)	80	44
		11		Access flap surgery + BioOss + resorbable membrane	7.1 (0.8)	4.7 (0.7)	78	34
Schwarz et al. (48)	6 months	11	Plastic curette + saline	Access flap surgery + nanocrystal hydroxyapatite	7.0 (0.6)	4.9 (0.6)	82	30
		11		Access flap surgery + BioOss + resorbable membrane	7.1 (0.8)	4.5 (0.7)	78	28
Romeo et al. (38)	24 months	7	Metronidazole + tetracycline + saline	Resective surgery + implantoplasty	5.79 (1.69)	3.58 (1.06)	2.83 (0.47)	0.61 (0.67)
		10		Resective surgery	6.52 (1.62)	5.5 (1.47)	2.86 (0.35)	2.33 (0.74)
Khoury & Buchmann (16)	30 months	7	0.2% Chlorhexidine + citric acid hydrogen peroxide + 0.9% saline	Access flap surgery + autologous bone	6.40 (0.90)	2.90 (0.60)	Not reported	Not reported
		11		Access flap surgery + autologous bone + nonresorbable membrane	6.70 (1.10)	2.80 (1.30)	Not reported	Not reported
		7		Access flap surgery + autologous bone + resorbable membrane	6.40 (0.90)	5.10 (1.20)	Not reported	Not reported
Ross-Jansaker et al. (41)	12 months	29 implants	Hydrogen peroxide (3%) + saline	Access flap surgery + Algipore + resorbable membrane	5.44 (1.78)	2.86 (2.00)	79.3	21.6
		36 implants		Access flap surgery + Algipore	5.64 (1.84)	3.44 (1.58)	92.9	25
Deppe et al. (8)	20–236 months	17 implants	CO ₂ laser	Resective surgery	5.70 (1.40)	3.40 (1.50)	2.80 (1.20)	1.80 (1.10)
		13 implants		Beta-tricalcium phosphate + resorbable membrane	5.70 (1.40)	2.50 (1.40)	3.30 (0.60)	1.90 (1.00)
		16 implants	Air abrasive	Resective surgery	6.20 (1.80)	4.30 (1.20)	2.70 (0.90)	1.10 (1.20)
		11 implants		Beta-tricalcium phosphate + resorbable membrane	5.10 (1.70)	2.50 (1.10)	2.30 (1.40)	2.10 (1.40)

Probing pocket depth and bleeding on probing values are given as mean or mean (standard deviation) unless indicated otherwise.

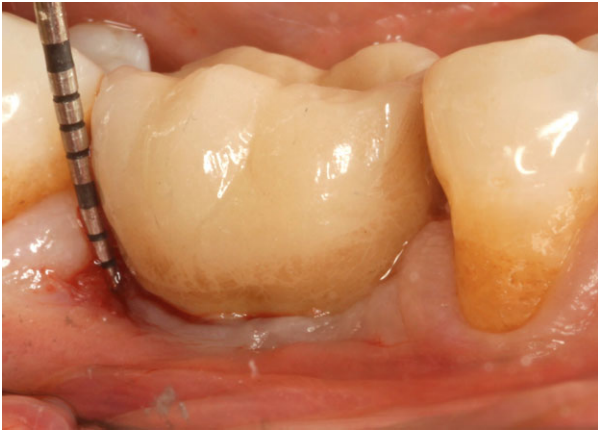

Fig. 1. Peri-implant probing pocket depth.

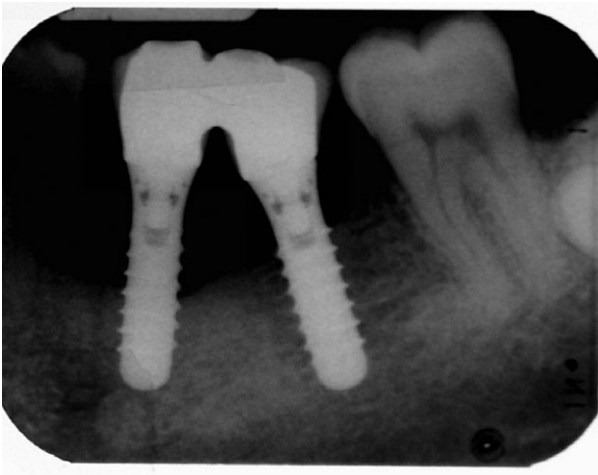

Fig. 2. Bone loss around implants: radiograph of implants with horizontal bone loss.

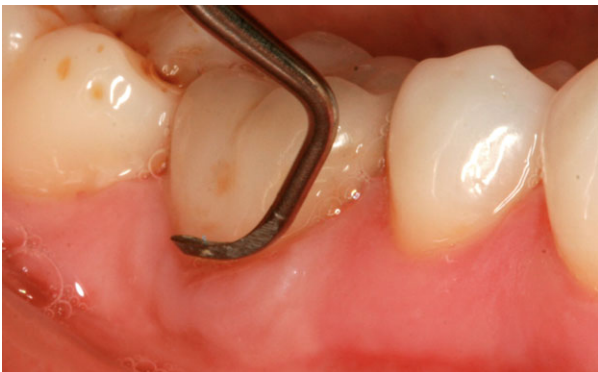

Fig. 3. Debridement of implant biofilm using a titanium curette.

teeth and subgingivally. This design is different from other leading powered brushes, which use oscillating, vibrating or acoustic modes of action. This maintenance protocol has been used twice daily for a period of 6 years (65).

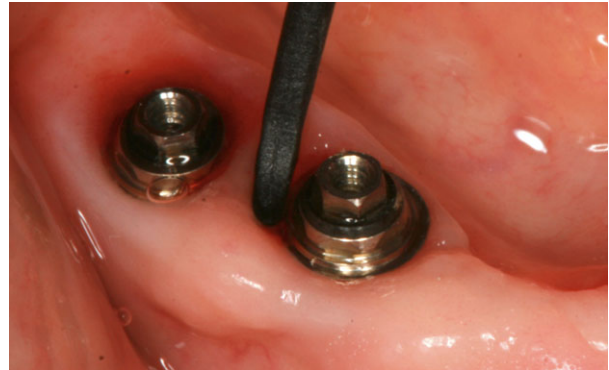

Fig. 4. Debridement of peri-implant biofilm using a carbon-fiber curette.

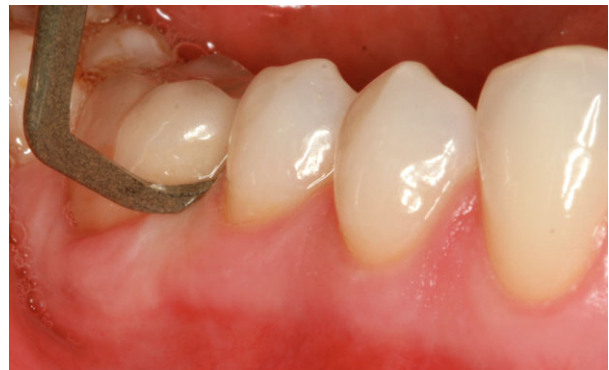

Fig. 5. Debridement of peri-implant biofilm using a Teflon curette (polytetrafluoroethylene-e).

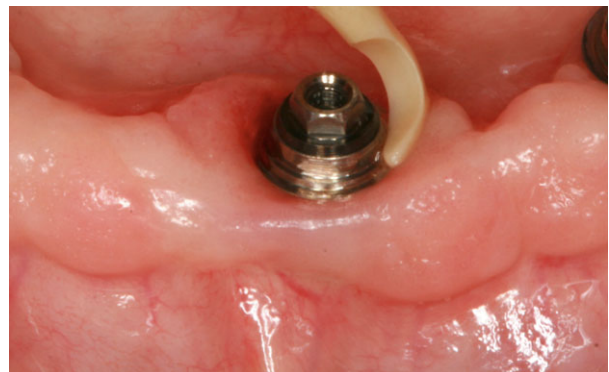

Fig. 6. Debridement of peri-implant biofilm using a plastic curette.

Chemical plaque control

Chemical plaque control may provide additional benefits as an adjunct to toothbrushes (manual or powered) and interdental-cleaning devices. In the 6th European Workshop in Periodontology, it was concluded that there was a need to determine whether antimicrobials used in periodontal therapy are also effective in the treatment of peri-implant diseases

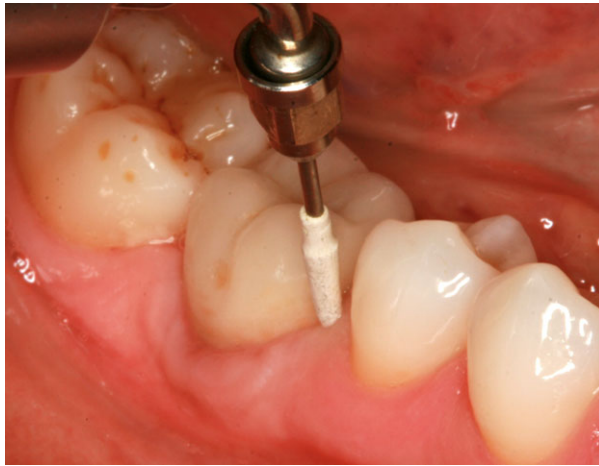


Fig. 7. Debridement of peri-implant biofilm using a poly-etheretherketone-coated ultrasonic tip.

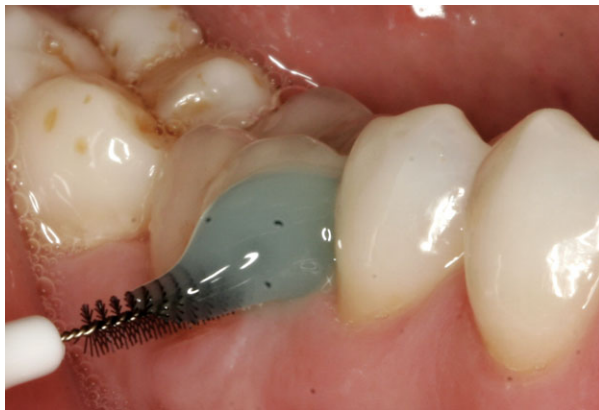

Fig. 8. Peri-implant oral-hygiene procedure with an interdental brush and chlorhexidine gel.

and to what extent initial improvements are sustained over the long term (19). Therefore, different chemical products, in combination with mechanical oral-hygiene techniques, have been studied. Examples of these adjunctive protocols are:

- triclosan/copolymer toothpaste. Triclosan (0.3%) and methyl vinyl ether-maleic anhydride polymer (2.0%) in a sodium fluoride silica-base toothpaste, used in conjunction with a soft bristle brush for 6 months twice daily, for 60 s each time (29, 58).
- fluoride toothpaste. A toothpaste containing 0.243% sodium fluoride silica-based toothpaste, used in conjunction with a soft bristle brush for 6 months twice daily, for 60 s each time (29, 58).
- essential-oils rinse. After a dental prophylaxis, Listerine® was used after a standard oral hygiene procedure, twice daily for 30 s, for a period of 3 months (6).
- chlorhexidine rinse. Rinsing twice a day with 0.12% chlorhexidine, in conjunction with brushing

using a soft manual toothbrush and use of specialized implant dental floss and end-tuft brushes or interproximal brushes. This protocol of supportive therapy was used for a period of 6 years and chlorhexidine rinsing was combined with the use of a counter-rotational powered brush (65).

Peri-implant mucositis therapy: evaluation in controlled trials

At least seven randomized controlled clinical trials evaluating the therapy of peri-implant mucositis have been published (6, 10, 14, 28, 29, 45, 62). In these studies, the sample size ranged from eight to 59 patients and the mean follow-up period varied from 3 to 8 months. Three studies included patients with treated periodontitis (14, 29, 62); two included periodontally healthy subjects (10, 28); and two did not report the periodontal status (6, 45). The studies can be grouped into two categories, depending on whether the intervention is professional or based on the patient's oral-hygiene practices, as follows:

- professional mechanical debridement, with or without the adjunctive use of antimicrobials (14, 28, 45, 62).
- home-use oral-hygiene intervention. After an initial prophylaxis, patients were instructed to use an antiseptic as an adjunct to conventional oral-hygiene techniques for a certain period of time (3–6 months) (6, 10, 29).

Treatment efficacy is based on evaluation of the changes in the gingival inflammatory parameters. Bleeding on probing was considered as the main clinical outcome variable, although probing depth and plaque index were also usually reported. Microbiological outcomes were reported in two articles (14, 62). Only one study reported the number and percentage of cases of mucositis solved (complete resolution of bleeding on probing at all the measured sites) (14).

Based on these clinical outcomes, the conclusions discussed in the following sections were reached for mechanical debridement and home-use oral-hygiene interventions.

Mechanical debridement

When mechanical debridement alone was compared with mechanical debridement plus the adjunctive use of different protocols of chlorhexidine (14, 28, 62) or locally delivered tetracycline (45), reductions in bleeding on probing were significant in both test and control groups, with no clear benefit derived from the use of chlorhexidine or locally delivered tetracycline. The results for probing depth showed higher variability

compared with bleeding on probing. Although two studies found a similar probing-depth reduction in both groups (14, 62), one found higher reductions in the control group (28) and another did not find any change in probing depth in test or control groups (45). Plaque index was not evaluated in one paper (14) and the results for the other trials showed either a similar reduction of plaque index in both groups (28, 62) or no changes in any of the groups (45). For microbiological outcomes, no differences could be seen between groups when using PCR (62) or DNA probes (14).

Home-use oral-hygiene interventions

When evaluating home-use oral-hygiene interventions, different plaque-control regimens were compared. Two studies evaluated the adjunctive home use of antiseptics after an initial prophylaxis (6, 10) and one study evaluated the home use of two different toothpastes as unique treatments for peri-implant mucositis (29). The reported results were: (i) a higher reduction of bleeding on probing and in the plaque index after 3 months using an essential-oils mouthrinse compared with the negative control, but no differences for probing depth or clinical attachment level (6); (ii) a greater reduction in the plaque index, in the modified bleeding index and in the stain index, when comparing irrigation with 0.06% chlorhexidine using a powered oral irrigator with a special subgingival irrigating tip to rinse with 0.12% chlorhexidine mouthrinse, once daily for 3 months (10); and (iii) a higher performance of triclosan/copolymer-containing toothpaste compared with a sodium fluoride toothpaste after a period of home-use of 6 months, in terms of bleeding on probing, despite the fact that no changes were noted among groups for plaque index or probing depth (29).

Peri-implant mucositis therapy: summary and conclusions

Treatment of peri-implant mucositis usually includes mechanical debridement of biofilm and calculus either by professional intervention or by home-use oral-hygiene techniques, with or without the adjunctive use of antimicrobials. Professional mechanical interventions, with or without the adjunctive use of antimicrobials, have been shown to result in a significant reduction of peri-implant tissue inflammation (as evaluated by reductions in bleeding on probing) and therefore peri-implant mucositis seems to be successfully treated by professional mechanical debridement, independently of the adjunctive use of

an antimicrobial. In the case of home-use oral-hygiene products, mechanical plaque control, together with the use of an antiseptic, may provide benefit in the treatment of peri-implant mucositis in terms of reduction of bleeding on probing and sometimes in reduction of the plaque index. In summary, clinical trials evaluating the treatment of peri-implant mucositis provide a variety of effective protocols for reducing peri-implant tissue inflammation and therefore the clinician should select those that adapt better to the specific patient's circumstances.

Peri-implantitis nonsurgical therapy

The basis for peri-implantitis non-surgical therapy is infection control through debridement of the implant surface, with the aims of debriding the adhered biofilm and reducing the bacterial load below the threshold level for causing disease (64). Mechanical debridement around dental implants encounters some specific characteristics: the absence of periodontal ligament; a variable (more/less rough) implant surface; and different types of abutment connection. These factors can jeopardize not only the professional therapy, but also the patient's self-performed hygiene because these characteristics may facilitate biofilm formation when the surfaces become exposed to the oral environment (34). In order to overcome these limitations, different protocols combining adjunctive treatments have been proposed (Table 3).

Peri-implantitis nonsurgical therapy: mechanical or automatic debridement

Similar objectives and technologies for the mechanical debridement of implant surfaces (curettes, air-abrasive devices, ultrasonic devices and lasers) have been evaluated for the treatment of peri-implantitis, with the main difference that they are aimed more subgingivally to decontaminate the exposed implant surfaces. Regarding the use of *curettes* for scaling implant surfaces, the same considerations described for the treatment of peri-implant mucositis are valid for the nonsurgical treatment of peri-implantitis. Different types of curettes have been studied, mainly those made of carbon fiber (15) or titanium (25, 37, 44), and most of the protocols included an adjunctive polish with a rubber cup and a polishing paste.

Standard powdered air-abrasive systems are based on the air-spray of sodium bicarbonate. They are used for polishing and for removing tooth stains, but

cannot be used for implant instrumentation because they may damage hard and soft tissue as a result of their high abrasiveness (17). Recently, a powered air-abrasive system, based on a low-abrasive amino-acid glycine powder (Fig. 9), has been demonstrated as an effective method of biofilm removal from the root surface, without damaging hard and soft tissues (27) and it has been recommended for debriding implant surfaces. It uses a specially designed nozzle, consisting of a thin, flexible, plastic tube (length: 1.7 cm; diameter: 0.8 mm at the tip) that is fitted with three orthogonally orientated holes. This specific design is associated with the horizontal exit of the air-powder mixture and reduced pressure, thus preventing the formation of emphysema in the adjacent tissue. The hand-piece (Air-Flows EL-308/A; EMS Electro Medical Systems, Nyon, Sweden) should be guided in a circular motion, from coronal to apical, parallel to the implant surface in a noncontact mode, and the instrumentation time at each aspect (i.e. mesial, distal, vestibular and oral) should be limited to 5 s, as recommended by the manufacturer (42). It has also been recommended to place the nozzle in the pocket mesially, lingually, distally and buccally, for ca. 15 s in each position. The nozzle should be moved with a circumferential movement around the implant, attempting to cover the entire exposed implant surface (33, 44).

Similarly to curettes and air-abrasive devices, the aim of *ultrasonic devices* is to remove biofilm and calculus during the treatment of peri-implantitis, without altering the implant surface. To accomplish this, different tip modifications have been proposed, such as carbon fiber, silicone or plastic (15, 25, 37). Another modification to the conventional ultrasonic device is the Vector[®] system (Dürr Dental, Bietigheim-Bissingen, Germany), in which the horizontal vibration is converted by a resonating ring into a vertical vibration, resulting in a parallel movement of the working tip to the surface.

The use of *lasers* has been proposed in the treatment of peri-implantitis as a result of their anti-infec-

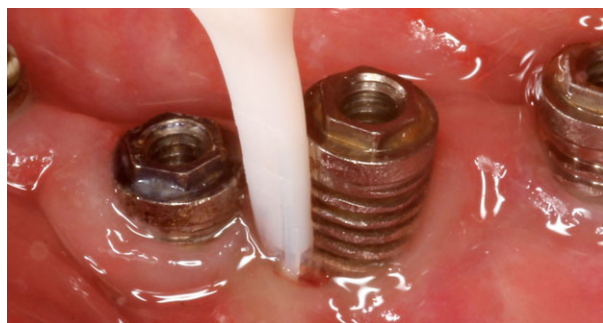

Fig. 9. Debridement of peri-implant biofilm using a glycine-based air-abrasive system.

tive, physical and ablation properties. The erbium-doped yttrium aluminium garnet laser (Fig. 10) is the laser that has shown the highest potential for use in the treatment of peri-implantitis as a result of its ability to remove subgingival plaque and calculus efficiently without significantly damaging the implant surface (59). This laser is used for peri-implantitis treatment with a special hand-piece containing a cone-shaped sapphire tip, which should be used in a parallel and semicircular motion around the circumference of the pocket. The laser should be set with an energy of 100 mJ and a frequency of 10 Hz (24, 33, 50, 56). Recently, a protocol has been proposed that combines the use of a diode laser (with a wavelength of 660 nm and a power density of 100 mW for 10 s in each pocket) with phenothiazine chloride dye (for 3 min), followed by irrigation with 3% hydrogen peroxide (44).

All the debridement systems described above can be combined to achieve better removal of biofilm and calculus: the combination of sodium carbonate air-powder and resin curettes has been evaluated (9).

Peri-implantitis nonsurgical therapy: adjunctive use of antimicrobial products

Adjunctive therapies, such as antiseptics and antibiotics, have been proposed to improve the results of nonsurgical debridement as reduction of bacterial

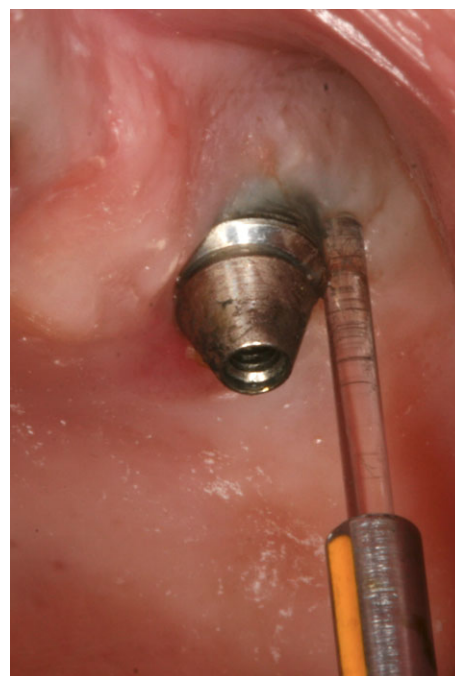

Fig. 10. Debridement of peri-implant biofilm using an erbium-doped yttrium aluminium garnet laser.

loads to levels compatible with tissue health is difficult to accomplish using mechanical means only (36).

Chlorhexidine-based products, as gels, irrigation and/or rinses, and in different formulations and regimes, have been reported. Examples include: (i) repeated irrigation of the peri-implant pocket with 0.2% chlorhexidine in one session (4); (ii) single application of 1% chlorhexidine gel with a disposable syringe (30, 32); (iii) repeated application of 1% chlorhexidine gel at treatment and at 30 and 90 days after treatment (31); (iv) the combination of pocket irrigation with 0.2% chlorhexidine plus 0.2% chlorhexidine gel, applied subgingivally in each implant at the day of intervention and the use of 0.2% chlorhexidine mouth rinse, twice daily for 2 weeks (50, 56); and (v) pocket irrigation with 0.12% chlorhexidine plus 1% chlorhexidine gel (42).

Different protocols using *locally or systemically delivered antimicrobials* have been evaluated: (i) a single-unit dose of 1 mg of minocycline and 3 mg of poly(glycolide-co-dl-lactide) placed submucosally at each treatment site, at treatment and 30 and 90 days after treatment (31); (ii) a single dose of 1 mg of minocycline microspheres (30, 44); (iii) 1 mg of minocycline microspheres at treatment and 180 and 270 days after treatment (43); (iv) or topical irrigation with a solution containing 8.5% by weight of doxycycline and 37% by weight of poly-DL-lactide dissolved in a biocompatible carrier of *N*-methyl-2-pyrrolidone (4). Systemic antibiotics have been also used, but there are no controlled clinical trials evaluating their effect.

Peri-implantitis nonsurgical therapy: evaluation in controlled trials

At least nine controlled trials, reported in 13 articles, have evaluated the nonsurgical therapy of peri-implantitis (Table 3). Although the same case definition for peri-implantitis was not used in all studies, all included bleeding on probing of the peri-implant mucosa, increased probing depth and radiographic bone loss. The sample sizes ranged from 18 to 42 patients and the mean follow-up time varied from 3 to 12 months.

Different treatment protocols were evaluated and those can be grouped into three categories:

- antimicrobials. Mechanical debridement was performed with the adjunctive use of an antiseptic or a locally delivered antibiotic (4, 30, 31, 42, 44).
- lasers. Two types of lasers were compared with different protocols of mechanical debridement (24, 33, 44, 50, 56).

- ultrasonic devices. The Vector[®] system was compared with two different types of curettes (15, 25, 37).

Efficacy was evaluated by measuring reductions in probing depth and bleeding on probing as the main outcome measurements. As secondary outcome variables, changes in plaque index, clinical attachment level, microbiological outcomes and radiographic bone-level changes were used in some studies.

Based on the effect on these clinical outcomes we can draw the following conclusions, regarding the *adjunctive use of antimicrobials*:

- in the first subgroup, three publications reported the results of the same study, with variations in the follow up (3–12 months) and in the type of analysis (patient- or implant-based) (30, 31, 44). They compared the use of carbon-fiber curettes plus chlorhexidine gel with carbon-fiber curettes plus locally delivered minocycline, and reported a very small added effect with the use of minocycline, both on probing depth (0–0.15 mm in the chlorhexidine group and 0.3–0.4 mm in the minocycline group) and on bleeding on probing (8–38% in the chlorhexidine group and 16–26% in the minocycline group). Interestingly, the authors observed that when repeating the application of minocycline in residual pockets, the results were much better (31).
- in the second subgroup, plastic curettes alone were compared with plastic curettes plus the adjunctive use of locally delivered doxycycline (4). After a mean follow-up period of 4.5 months, changes in probing depth and bleeding on probing were only significant in the antibiotic group. Although the control group had a mean reduction in probing depth of 0.28 mm and in bleeding on probing of 13%, the experimental group experienced reductions of 1.15 mm and 27%, respectively.
- in the last subgroup, carbon-fiber curettes plus chlorhexidine irrigation and gel application was compared with a glycine-based powder air-abrasive (42). After 6 months of follow up, both groups showed a similar reduction in probing depth (0.5 mm in the chlorhexidine group and 0.6 mm in the air-abrasive group), although bleeding on probing was reduced more in the air-abrasive group (43% vs. 11%, respectively).

Based on these results, locally delivered antibiotics may provide an extra clinical benefit when compared with chlorhexidine, especially when repeated applications are administered. Nevertheless, the data should

be analyzed carefully, as the clinical effect was limited.

Regarding the evaluation of *lasers*, the following conclusions were reported:

- two types of lasers have been studied – erbium-doped yttrium aluminium garnet lasers and diode lasers – although the vast majority of the research has focused on erbium-doped yttrium aluminium garnet lasers. In a first group of studies, use of the erbium-doped yttrium aluminium garnet laser was compared with conventional debridement using plastic curettes and subgingival irrigation with chlorhexidine (50, 56). It was reported that up to the 6-month evaluation, the erbium-doped yttrium aluminium garnet laser obtained higher reduction of probing depth and bleeding on probing than did the conventional debridement, but after 12 months both groups experienced a relapse in the clinical benefits previously obtained, although the rebound was higher in the control group. Therefore, it can be stated that erbium-doped yttrium aluminium garnet laser improved the clinical outcomes, but not enough to control peri-implant infection 1 year after therapy.
- a second group of studies analyzed the clinical and microbiological effects of the erbium-doped yttrium aluminium garnet laser compared with glycine-based air-abrasive (24, 33). After a 6-month period, both groups showed a significant reduction of probing depth, without differences between groups (0.9 mm in the air-abrasive group and 0.8 mm in the laser group). Data for bleeding on probing values showed that while 31% of sites were free of bleeding in the laser group, 25% of sites were free of bleeding in the air-abrasive group (33). For the microbiological outcomes, it was found that none of the groups could reduce bacterial counts at 6 months and that *Porphyromonas gingivalis* counts were higher in patients with progressive peri-implantitis (24).
- the diode laser has been used in combination with photodynamic therapy and local delivery of minocycline after initial mechanical debridement with titanium curettes and glycine-based air-abrasive (44). At the 3-month follow-up time point, significantly reduced probing depth and bleeding on probing was observed in both groups, although no further changes could be seen up to the 6-month follow-up time point. No differences could be seen between groups for probing depth and bleeding on probing reduction at any time point. Nevertheless, at the end of the study, the photodynamic

group had twice as many patients with complete resolution of inflammation (30% vs. 15%).

Based on these results, the use of lasers could provide short-term (up to 3 months) clinical benefits in the nonsurgical treatment of peri-implantitis. Nevertheless, we have to analyze the cost-benefits of this therapy carefully because the results were similar to those obtained with cheaper technologies that were easier to use.

Finally, regarding the evaluation of *ultrasonic devices*, the following conclusions were reached: the Vector[®] system was compared with carbon-fiber (15) or titanium (25, 37) curettes after 6 months of follow-up. It was observed that carbon-fiber curettes had no effect on probing-depth reduction and resulted in an increase in bleeding on probing. On the other hand, the Vector[®] system could not reduce probing depth but was able to reduce bleeding on probing from 63% to 36% (15). In the case of titanium curettes, the authors could not find intra- or intergroup differences for probing depth, bleeding on probing changes (37) or microbiological outcomes (25). Therefore, we can conclude that this technology was ineffective in resolving peri-implantitis and had a very small effect on mucosal inflammation.

Peri-implantitis nonsurgical therapy: summary and conclusions

Several protocols have been reported for the nonsurgical treatment of peri-implantitis (Table 3). They usually involved mechanical debridement of the implant surface using curettes (4, 15, 25, 30, 31, 37, 42, 44, 50, 56), ultrasonic devices (15, 25, 37), air-abrasive devices (24, 33, 42, 44) or lasers (24, 33, 44, 50, 56), alone or combined with some sort of chemical action mainly based on local antibiotics (4, 30, 31, 44) or antiseptics such as chlorhexidine (30, 31, 42, 44, 50, 56). The analyses on the efficacy of these protocols in controlled trials revealed a very limited effect in terms of the surrogate outcome probing depth; however, the effect on bleeding on probing was more significant. Out of the 13 selected studies, the largest probing-depth reduction was 1.2 mm (4) and final bleeding on probing scores were >50% in almost all the published articles. In addition, this treatment did not result in changes of the bone levels. On the other hand, it is also important to consider the key limiting factors in these studies, such as the limited follow up (only 12-month data are currently available), reduced sample sizes and the lack of a defined control group.

Based on the available data, it seems that the nonsurgical therapy of peri-implantitis is not effective in

disease resolution because only limited improvements in the main clinical parameters have been reported and there is a clear tendency for disease recurrence. It is therefore recommended to consider advanced therapies, such as surgical interventions, when nonsurgical peri-implant surgery is unable to achieve significant improvements in the clinical parameters.

Peri-implantitis surgical therapy

As described earlier, nonsurgical treatment of peri-implant diseases has shown modest efficacy, and one possible explanation for these limited results may be related to insufficient decontamination of the implant surface exposed to bacterial biofilms. Indeed, the geometry of the threads and the modification of the implant surface may complicate the decontamination when bone loss occurs and the implant surfaces, especially rough surfaces, are exposed to bacterial biofilms (34). Moreover, the histopathology of the peri-implant lesions is characterized by the presence of an inflammatory cell infiltrate extending apically in direct contact with the bone crest and leading to loss of osseointegration (3). In addition, peri-implantitis has been associated with a gram-negative anaerobic microbiota, similar to that found in severe periodontitis around natural teeth, which might be difficult to control with nonsurgical therapy alone (36).

As additional objectives of the treatment of peri-implant infection, the treatment of peri-implantitis should aim for bone regeneration and the attainment of re-osseointegration. This phenomenon of direct bone-to-implant contact on a previously contaminated implant surface has been documented in pre-clinical models but has never been demonstrated in humans (23, 26). The rationale of the surgical treatment of peri-implantitis is therefore twofold: to improve implant surface cleanability; and to modify the anatomy of soft and hard peri-implant tissues in order to obtain re-osseointegration.

Peri-implantitis surgical therapy: decontamination of the implant surface

When the implant surface is exposed to oral biofilms, it becomes contaminated and, in order to promote healing, decontamination of the surface is mandatory. Numerous approaches have been used for implant surface decontamination during peri-implant surgery, including mechanical, chemical and laser treatments.

Mechanical decontamination

Mechanical decontamination consists of the physical removal of hard- and soft-tissue deposits on the contaminated exposed implant surface. Instruments for mechanical debridement usually include curettes, ultrasonic devices with special tips and air-powder abrasive systems. The advantages and limitations of these systems have already been described when used in nonsurgical therapy (33).

A second, and more aggressive, approach has been proposed, consisting of smoothening of the implant surface (and thus removing the rough surface of the implant), resulting in a polished smooth surface more amenable for oral-hygiene practices. This procedure, termed 'implantoplasty' (38), is carried out with burs and stones under copious irrigation because there is an important rise in temperature and an extensive local contamination with titanium (61).

Chemical decontamination

The rationale for the use of chemical treatments is to disinfect/decontaminate the implant surface by direct application of appropriate substances. Citric acid, hydrogen peroxide, chlorhexidine and/or saline have been utilized, and all have given similar results in experimental studies (16, 46).

Lasers

Lasers have also been used to decontaminate the implant surface, although the scientific literature often failed to find clinical benefits. Schwarz et al. (53) noticed that erbium lasers yielded significant advantages in terms of bleeding on probing and clinical attachment level; however, no differences were noted when compared with conventional mechanical treatment. No differences between the use of lasers and conventional treatment were also noted with a CO₂ laser as adjunct to both resective and reconstructive techniques (8).

Peri-implantitis surgical therapy: surgical techniques

Various surgical techniques have been recommended, depending on the final objective of the surgical intervention: (i) access for cleaning and decontamination of the implant surface (access flaps); (ii) access for cleaning and decontamination plus exposure of the affected surfaces for cleaning (apically repositioned flaps); and (iii) access for cleaning plus aiming for bone regeneration and re-osseointegration (regenerative techniques).

Access flap surgery

The objective of this flap surgical intervention is to conserve and to maintain all the soft tissues around the affected implant and to focus mainly on the decontamination of the implant surface. Usually, intracrevicular incisions (Fig. 11a) are made around the affected implants and mucoperiosteal flaps are raised both buccally and palatally/lingually (Fig. 11b). Degranulation of the peri-implant inflamed tissues is best accomplished with titanium curettes and implant surface decontamination is performed using one of the methods previously described. Finally, the flaps are repositioned and adequately sutured (Fig. 11c).

As there is no evidence from human or animal studies that implant surface decontamination alone may result in re-osseointegration, this surgical intervention aims to eliminate the inflammatory changes responsible for the disease process. As this technique aims to maintain the position of the soft-tissue mar-

gin around the implant neck, this can only be attained when the peri-implant bone loss is shallow.

Apically positioned flaps

This surgical approach has been advocated in order to enhance self-performed oral hygiene and reduce the pockets around the affected implants (20). Technically, a reverse beveled incision is designed dependent on the probing pocket depth and the width and the thickness of the peri-implant mucosa (Fig. 12a). Vertical releasing incisions may be needed in order to position the flap apically. Mucoperiosteal flaps are raised both buccally and palatally/lingually (Fig. 12b). The collar of the affected tissues is then removed and the implant surfaces are thoroughly decontaminated. Often osteoplasty, carefully performed using bone chisels, is needed. Finally, the flaps are sutured in order to leave the previously affected part of the implant exposed to the oral cavity (Fig. 12c). In order to smoothen the exposed part and to decrease the postsurgical contamination of the implant surface, implantoplasty has been suggested (38). This technique may be indicated for peri-implantitis with suprabony defects or a one-wall intrabony defect. It is obviously a technique chosen mainly for nonesthetic areas (39).

Regenerative surgical techniques

Regenerative approaches have two main objectives:

- to support the tissue dimensions during the healing process, avoiding recession of the mucosa.
- to enhance the chance of obtaining re-osseointegration, using reconstructive and regenerative techniques/materials.

In this technique, intracrevicular incisions are often performed in order to maintain the total amount of soft tissues (Fig. 13a). After elevation of buccal and lingual periosteal flaps, degranulation of the defect is performed using titanium instruments. After decontamination of the implant surface, a graft is placed around the implant, filling the intrabony component of the defect (Fig. 13b). Grafting may be performed with either autologous bone (16) or bone substitutes (52). The graft may be covered (Fig. 13c) with a resorbable or a nonresorbable (16, 41) membrane. Finally, the flaps are coronally positioned and sutured in order to determine healing (Fig. 13d), with either a nonsubmerged or a submerged approach (1).

A combined regenerative and resective approach has also been proposed (53), including extensive implantoplasty in the suprabony component of the defect; conversely, for the intrabony component, two procedures of decontamination were compared,

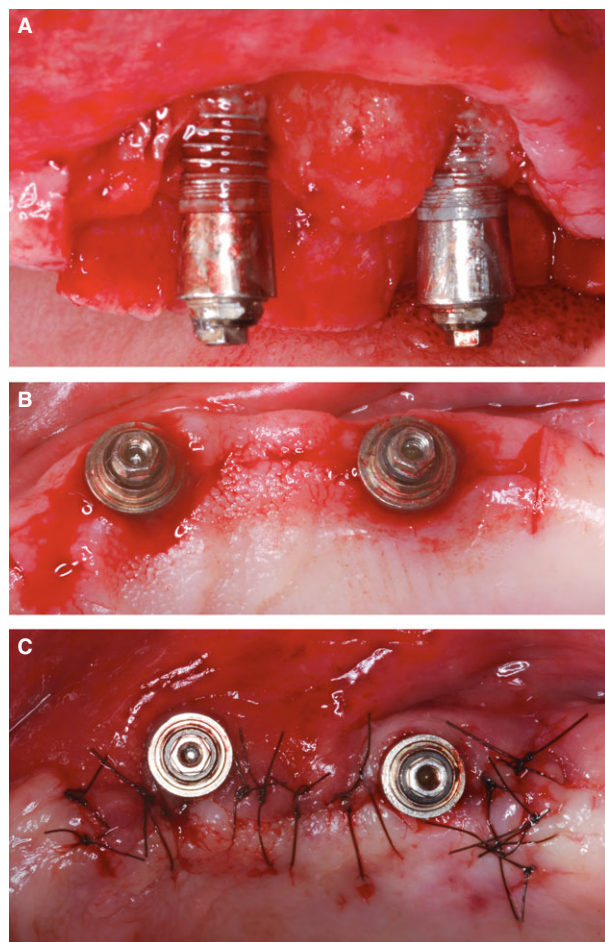


Fig. 11. Surgical therapy: access flap. (a) Surgical incisions. (b) Mucoperiosteal flaps. (c) Suturing.

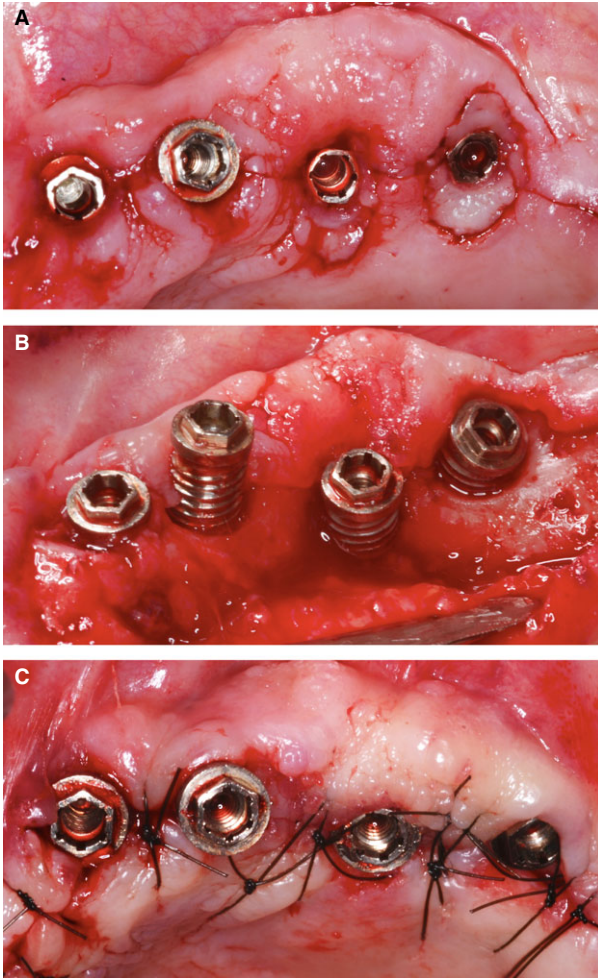


Fig. 12. Surgical therapy: resective surgery. (a) Incisions. (b) Mucoperiosteal flaps. (c) Suturing.

namely an erbium-doped yttrium aluminium garnet laser or plastic curettes and sterile saline. This technique is based on the knowledge that the most common peri-implant defects normally include an intrabony component and a more coronal suprabony portion. The intrabony component of the defect was treated with a collagen membrane and a bovine xenograft (53) and the suprabony component was treated with resective surgery.

Peri-implantitis surgical therapy: evaluation in controlled trials

There are a limited number of controlled studies evaluating the surgical therapy of peri-implantitis, and they have small sample sizes, a limited follow-up period and a high risk of bias (11) (Table 4). Moreover, the evaluation of efficacy is hampered by the lack of a standard mode of therapy, and therefore there is no clear control therapy. In fact, study designs comparing nonsurgical treatment with open flap debride-

ment or comparing open flap debridement with apically repositioned flaps are lacking.

Studies evaluating the surgical therapy of peri-implantitis can be grouped into three categories according to their main objective:

- to compare different methods of implant-surface decontamination whilst using the same surgical approach, such as resective, reconstructive or mixed (8, 38, 51, 53).
- to compare grafting of peri-implant bony defects with or without a membrane (16, 41).
- to compare two different types of reconstructive surgery (48, 52).

As discussed in the nonsurgical therapy section, clinical conclusions are drawn based on the results from surrogate periodontal outcomes. The validity of these surrogates has been extensively studied in periodontology but it is not clear whether their utility is similar in implant dentistry. Indeed, few papers have provided information on true end-point outcomes (peri-implantitis resolution) and none has provided information regarding evaluation of the surgical treatment of peri-implant diseases (14, 33). In spite of these limitations, and based on the results from surrogate outcomes, different conclusions can be drawn. These are discussed below.

When comparing *apically repositioned flaps, with and without implantoplasty* after 24 months, groups treated with implantoplasty demonstrated significant improvements in probing depth and clinical attachment levels (38). Another study (8) compared decontamination using air-powder abrasion with that using a CO₂ laser, during resective or reconstructive surgery (with a mixture of beta-tricalcium phosphate and autologous bone), and demonstrated no significant differences between the four groups at the short-term evaluation. However, after longer follow-up periods, laser decontamination and soft-tissue resection showed the highest performance, and no differences were noted among air abrasion and laser treatment when reconstructive surgery was performed. A third study (53) reported no differences, in terms of peri-implant bleeding or clinical attachment levels at 6 months, between decontamination with plastic curettes and saline and decontamination with the erbium-doped yttrium aluminium garnet laser, after extensive implantoplasty and treatment of the intrabony component with bovine xenograft and collagen membrane.

In *reconstructive approaches*, an important conclusion was the lack of differences independently from the use or not of a resorbable membrane. With reconstructive surgery using autogenous bone grafting and decontamination with chlorhexidine, citric acid,

hydrogen peroxide and saline, after 3 years of follow up a significant decrease of probing depth was observed in both groups, without intergroup differences (16); with a bone substitute and decontamination with hydrogen peroxide and saline, the 1-year results showed no bleeding in 75% of implants in

both groups and similar probing-depth reduction, clinical attachment level gain or defect fill (41) – the 3-year results confirmed the previous finding (40).

When comparing *different approaches of reconstructive surgery*, some conclusions based on surrogate parameters were drawn. Comparison of a graft of nanoapatite plus a bovine xenograft with collagen membranes and decontamination with plastic curettes and chlorhexidine as gel and solution, despite initially similar results (48), showed, after 4 years, that the use of xenograft plus collagen membrane appeared superior in terms of probing-depth reduction and clinical attachment level gain (52).

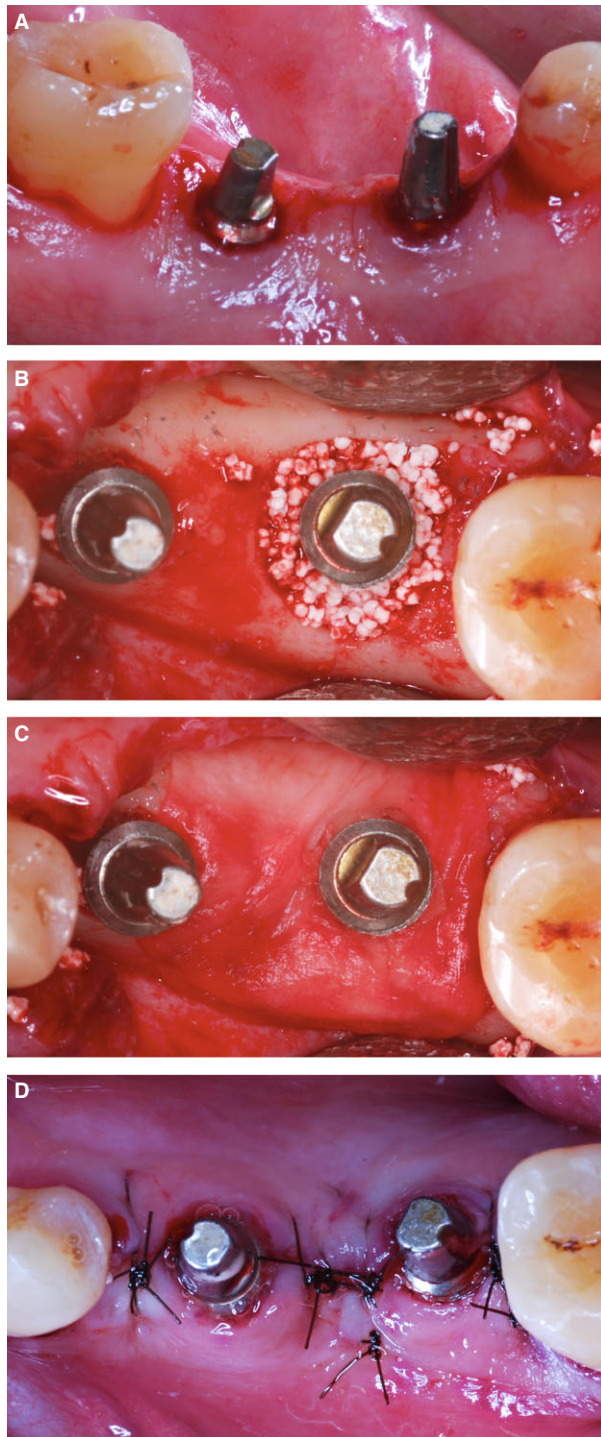


Fig. 13. Surgical therapy: regenerative surgery. (a) Incisions. (b) Defect fill with bone substitute. (c) Resorbable membrane to cover the bone defect. (d) Suturing.

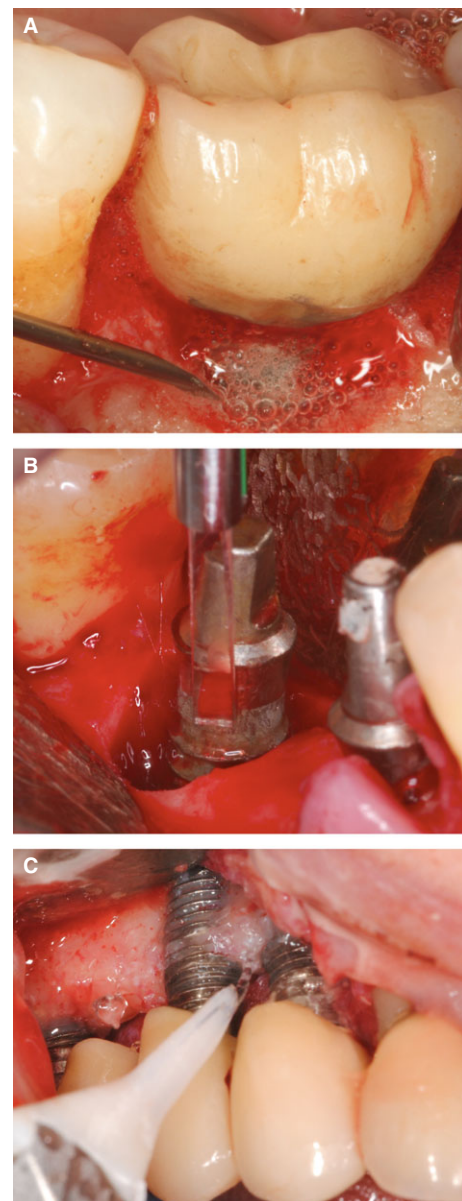


Fig. 14. Implant surface decontamination, during surgery, with hydrogen peroxide (a), with erbium-doped yttrium aluminium garnet laser (b) and with glycine-based air abrasive (c).

Peri-implantitis surgical therapy: summary and conclusions

Although the evidence presented is very limited for establishing solid conclusions and recommendations, some suggestions can be made. The characteristics of the peri-implant bone defects caused by peri-implantitis may help to select the most suitable surgical approach. A classification has been proposed for categorizing the morphology of the peri-implant defects and, based on this morphology, to develop a decision-making tree for the recommended surgical intervention (49). In the presence of circumferential bony defects with intact bony walls, the use of regenerative surgical approaches provided improved outcomes when compared with some degree of buccal dehiscence morphologies (54). Therefore, regenerative surgical techniques should be used in the presence of circumferential and intrabony defects. On the other hand, when defects show a predominant suprabony component, an apically repositioned flap should be used in nonesthetic areas. Even though there is no evidence to support the use of access flaps, they may be suggested for shallow defects or in esthetic areas after unsuccessful nonsurgical treatment.

In terms of surface decontamination (Fig. 14a–c), the literature does not clearly indicate superiority of a specific decontamination protocol. In fact, lasers did not show additional advantages over traditional systems (8, 53), and even rinsing with saline has shown successful outcomes (46). There is no evidence to recommend the use of a specific regenerative surgical technique, such as grafting with autogenous or xenogeneic grafts or bone substitutes, although it seems clear that the use of barrier membranes does not provide a clear added value (16, 40, 41).

References

1. Aghazadeh A, Rutger Persson G, Renvert S. A single-centre randomized controlled clinical trial on the adjunct treatment of intra-bony defects with autogenous bone or a xenograft: results after 12 months. *J Clin Periodontol* 2012; **39**: 666–673.
2. Berglundh T, Persson L, Klinge B. A systematic review of the incidence of biological and technical complications in implant dentistry reported in prospective longitudinal studies of at least 5 years. *J Clin Periodontol* 2002; **29**(Suppl. 3): 197–212.
3. Berglundh T, Zitzmann NU, Donati M. Are peri-implantitis lesions different from periodontitis lesions? *J Clin Periodontol* 2011; **38**(Suppl. 11): 188–202.
4. Buchter A, Kleinheinz J, Meyer U, Joos U. Treatment of severe peri-implant bone loss using autogenous bone and a bioabsorbable polymer that delivered doxycycline (Atridox). *Br J Oral Maxillofac Surg* 2004; **42**: 454–456.
5. Buchter A, Meyer U, Kruse-Losler B, Joos U, Kleinheinz J. Sustained release of doxycycline for the treatment of peri-implantitis: randomised controlled trial. *Br J Oral Maxillofac Surg* 2004; **42**: 439–444.
6. Ciano SG, Lauciello F, Shibly O, Vitello M, Mather M. The effect of an antiseptic mouthrinse on implant maintenance: plaque and peri-implant gingival tissues. *J Periodontol* 1995; **66**: 962–965.
7. Claffey N, Clarke E, Polyzois I, Renvert S. Surgical treatment of peri-implantitis. *J Clin Periodontol* 2008; **35**: 316–332.
8. Deppe H, Horch HH, Neff A. Conventional versus CO₂ laser-assisted treatment of peri-implant defects with the concomitant use of pure-phase beta-tricalcium phosphate: a 5-year clinical report. *Int J Oral Maxillofac Implants* 2007; **22**: 79–86.
9. Duarte PM, de Mendonca AC, Maximo MB, Santos VR, Bastos MF, Nociti FH. Effect of anti-infective mechanical therapy on clinical parameters and cytokine levels in human peri-implant diseases. *J Periodontol* 2009; **80**: 234–243.
10. Felo A, Shibly O, Ciano SG, Lauciello FR, Ho A. Effects of subgingival chlorhexidine irrigation on peri-implant maintenance. *Am J Dent* 1997; **10**: 107–110.
11. Graziani F, Figuero E, Herrera D. Systematic review of quality of reporting, outcome measurements and methods to study efficacy of preventive and therapeutic approaches to peri-implant diseases. *J Clin Periodontol* 2012; **39**(Suppl. 12): 224–244.
12. Hallstrom H, Persson GR, Lindgren S, Olofsson M, Renvert S. Systemic antibiotics and debridement of peri-implant mucositis. A randomized clinical trial. *J Clin Periodontol* 2012; **39**: 574–581.
13. Heitz-Mayfield LJ. Peri-implant diseases: diagnosis and risk indicators. *J Clin Periodontol* 2008; **35**: 292–304.
14. Heitz-Mayfield LJ, Salvi GE, Botticelli D, Mombelli A, Faddy M, Lang NP. Anti-infective treatment of peri-implant mucositis: a randomised controlled clinical trial. *Clin Oral Implants Res* 2011; **22**: 237–241.
15. Karring ES, Stavropoulos A, Ellegaard B, Karring T. Treatment of peri-implantitis by the Vector system. *Clin Oral Implants Res* 2005; **16**: 288–293.
16. Khoury F, Buchmann R. Surgical therapy of peri-implant disease: a 3-year follow-up study of cases treated with 3 different techniques of bone regeneration. *J Periodontol* 2001; **72**: 1498–1508.
17. Kontturi-Narhi V, Markkanen S, Markkanen H. Effects of airpolishing on dental plaque removal and hard tissues as evaluated by scanning electron microscopy. *J Periodontol* 1990; **61**: 334–338.
18. Lang NP, Berglundh T. Periimplant diseases: where are we now?—Consensus of the Seventh European Workshop on Periodontology. *J Clin Periodontol* 2011; **38**(Suppl. 11): 178–181.
19. Lindhe J, Meyle J. Peri-implant diseases: consensus Report of the Sixth European Workshop on Periodontology. *J Clin Periodontol* 2008; **35**: 282–285.
20. Lozada JL, James RA, Boskovic M, Cordova C, Emanuelli S. Surgical repair of peri-implant defects. *J Oral Implants Res* 1990; **16**: 42–46.
21. Maximo MB, de Mendonca AC, Renata Santos V, Figueiredo LC, Feres M, Duarte PM. Short-term clinical and microbio-

- logical evaluations of peri-implant diseases before and after mechanical anti-infective therapies. *Clin Oral Implants Res* 2009; **20**: 99–108.
22. Mombelli A, Decaillet F. The characteristics of biofilms in peri-implant disease. *J Clin Periodontol* 2011; **38**(Suppl. 11): 203–213.
23. Parlar A, Bosshardt DD, Cetiner D, Schafroth D, Unsal B, Haytac C, Lang NP. Effects of decontamination and implant surface characteristics on re-osseointegration following treatment of peri-implantitis. *Clin Oral Implants Res* 2009; **20**: 391–399.
24. Persson GR, Roos-Jansaker AM, Lindahl C, Renvert S. Microbiologic results after non-surgical erbium-doped: yttrium, aluminum, and garnet laser or air-abrasive treatment of peri-implantitis: a randomized clinical trial. *J Periodontol* 2011; **82**: 1267–1278.
25. Persson GR, Samuelsson E, Lindahl C, Renvert S. Mechanical non-surgical treatment of peri-implantitis: a single-blinded randomized longitudinal clinical study. II. Microbiological results. *J Clin Periodontol* 2010; **37**: 563–573.
26. Persson LG, Berglundh T, Lindhe J, Sennerby L. Re-osseointegration after treatment of peri-implantitis at different implant surfaces. An experimental study in the dog. *Clin Oral Implants Res* 2001; **12**: 595–603.
27. Petersilka GJ, Steinmann D, Haberlein I, Heinecke A, Flemmig TF. Subgingival plaque removal in buccal and lingual sites using a novel low abrasive air-polishing powder. *J Clin Periodontol* 2003; **30**: 328–333.
28. Porras R, Anderson GB, Caffesse R, Narendran S, Trejo PM. Clinical response to 2 different therapeutic regimens to treat peri-implant mucositis. *J Periodontol* 2002; **73**: 1118–1125.
29. Ramberg P, Lindhe J, Botticelli D, Botticelli A. The effect of a triclosan dentifrice on mucositis in subjects with dental implants: a six-month clinical study. *J Clin Dent* 2009; **20**: 103–107.
30. Renvert S, Lessem J, Dahlén G, Lindahl C, Svensson M. Topical minocycline microspheres versus topical chlorhexidine gel as an adjunct to mechanical debridement of incipient peri-implant infections: a randomized clinical trial. *J Clin Periodontol* 2006; **33**: 362–369.
31. Renvert S, Lessem J, Dahlén G, Renvert H, Lindahl C. Mechanical and repeated antimicrobial therapy using a local drug delivery system in the treatment of peri-implantitis: a randomized clinical trial. *J Periodontol* 2008; **79**: 836–844.
32. Renvert S, Lessem J, Lindahl C, Svensson M. Treatment of incipient peri-implant infections using topical minocycline microspheres versus topical chlorhexidine gel as an adjunct to mechanical debridement. *J Int Acad Periodontol* 2004; **6**: 154–159.
33. Renvert S, Lindahl C, Roos Jansaker AM, Persson GR. Treatment of peri-implantitis using an Er: YAG laser or an air-abrasive device: a randomized clinical trial. *J Clin Periodontol* 2011; **38**: 65–73.
34. Renvert S, Polyzois I, Claffey N. How do implant surface characteristics influence peri-implant disease? *J Clin Periodontol* 2011; **38**(Suppl. 11): 214–222.
35. Renvert S, Roos-Jansaker AM, Claffey N. Non-surgical treatment of peri-implant mucositis and peri-implantitis: a literature review. *J Clin Periodontol* 2008; **35**: 305–315.
36. Renvert S, Roos-Jansaker AM, Lindahl C, Renvert H, Persson GR. Infection at titanium implants with or without a clinical diagnosis of inflammation. *Clin Oral Implants Res* 2007; **18**: 509–516.
37. Renvert S, Samuelsson E, Lindahl C, Persson GR. Mechanical non-surgical treatment of peri-implantitis: a double-blind randomized longitudinal clinical study. I: clinical results. *J Clin Periodontol* 2009; **36**: 604–609.
38. Romeo E, Ghisolfi M, Murgolo N, Chiapasco M, Lops D, Vogel G. Therapy of peri-implantitis with resective surgery. A 3-year clinical trial on rough screw-shaped oral implants. Part I: clinical outcome. *Clin Oral Implants Res* 2005; **16**: 9–18.
39. Romeo E, Lops D, Chiapasco M, Ghisolfi M, Vogel G. Therapy of peri-implantitis with resective surgery. A 3-year clinical trial on rough screw-shaped oral implants. Part II: radiographic outcome. *Clin Oral Implants Res* 2007; **18**: 179–187.
40. Roos-Jansaker AM, Lindahl C, Persson GR, Renvert S. Long-term stability of surgical bone regenerative procedures of peri-implantitis lesions in a prospective case-control study over 3 years. *J Clin Periodontol* 2011; **38**: 590–597.
41. Roos-Jansaker AM, Renvert H, Lindahl C, Renvert S. Surgical treatment of peri-implantitis using a bone substitute with or without a resorbable membrane: a prospective cohort study. *J Clin Periodontol* 2007; **34**: 625–632.
42. Sahm N, Becker J, Santel T, Schwarz F. Non-surgical treatment of peri-implantitis using an air-abrasive device or mechanical debridement and local application of chlorhexidine: a prospective, randomized, controlled clinical study. *J Clin Periodontol* 2011; **38**: 872–878.
43. Salvi GE, Persson GR, Heitz-Mayfield LJ, Frei M, Lang NP. Adjunctive local antibiotic therapy in the treatment of peri-implantitis II: clinical and radiographic outcomes. *Clin Oral Implants Res* 2007; **18**: 281–285.
44. Schar D, Ramseier CA, Eick S, Arweiler NB, Sculean A, Salvi GE. Anti-infective therapy of peri-implantitis with adjunctive local drug delivery or photodynamic therapy: six-month outcomes of a prospective randomized clinical trial. *Clin Oral Implants Res* 2013; **24**: 104–110.
45. Schenk G, Flemmig TF, Betz T, Reuther J, Klaiber B. Controlled local delivery of tetracycline HCl in the treatment of periimplant mucosal hyperplasia and mucositis. A controlled case series. *Clin Oral Implants Res* 1997; **8**: 427–433.
46. Schou S, Berglundh T, Lang NP. Surgical treatment of peri-implantitis. *Int J Oral Maxillofac Implants* 2004; **19**(Suppl.): 140–149.
47. Schwarz F, Bieling K, Bonsmann M, Latz T, Becker J. Non-surgical treatment of moderate and advanced periimplantitis lesions: a controlled clinical study. *Clin Oral Invest* 2006; **10**: 279–288.
48. Schwarz F, Bieling K, Latz T, Nuesry E, Becker J. Healing of intrabony peri-implantitis defects following application of a nanocrystalline hydroxyapatite (Ostim) or a bovine-derived xenograft (Bio-Oss) in combination with a collagen membrane (Bio-Gide). A case series. *J Clin Periodontol* 2006; **33**: 491–499.
49. Schwarz F, Herten M, Sager M, Bieling K, Sculean A, Becker J. Comparison of naturally occurring and ligature-induced peri-implantitis bone defects in humans and dogs. *Clin Oral Implants Res* 2007; **18**: 161–170.

50. Schwarz F, Jepsen S, Hertzen M, Sager M, Rothamel D, Becker J. Influence of different treatment approaches on non-submerged and submerged healing of ligature induced peri-implantitis lesions: an experimental study in dogs. *J Clin Periodontol* 2006; **33**: 584–595.
51. Schwarz F, John G, Mainusch S, Sahm N, Becker J. Combined surgical therapy of peri-implantitis evaluating two methods of surface debridement and decontamination. A two-year clinical follow up report. *J Clin Periodontol* 2012; **39**: 789–797.
52. Schwarz F, Sahm N, Bieling K, Becker J. Surgical regenerative treatment of peri-implantitis lesions using a nanocrystalline hydroxyapatite or a natural bone mineral in combination with a collagen membrane: a four-year clinical follow-up report. *J Clin Periodontol* 2009; **36**: 807–814.
53. Schwarz F, Sahm N, Iglhaut G, Becker J. Impact of the method of surface debridement and decontamination on the clinical outcome following combined surgical therapy of peri-implantitis: a randomized controlled clinical study. *J Clin Periodontol* 2011; **38**: 276–284.
54. Schwarz F, Sahm N, Schwarz K, Becker J. Impact of defect configuration on the clinical outcome following surgical regenerative therapy of peri-implantitis. *J Clin Periodontol* 2010; **37**: 449–455.
55. Schwarz F, Sculean A, Bieling K, Ferrari D, Rothamel D, Becker J. Two-year clinical results following treatment of peri-implantitis lesions using a nanocrystalline hydroxyapatite or a natural bone mineral in combination with a collagen membrane. *J Clin Periodontol* 2008; **35**: 80–87.
56. Schwarz F, Sculean A, Rothamel D, Schwenzer K, Georg T, Becker J. Clinical evaluation of an Er: YAG laser for nonsurgical treatment of peri-implantitis: a pilot study. *Clin Oral Implants Res* 2005; **16**: 44–52.
57. Serino G, Turri A, Lang NP. Probing at implants with peri-implantitis and its relation to clinical peri-implant bone loss. *Clin Oral Implants Res* 2013; **24**: 91–95.
58. Sreenivasan PK, Vered Y, Zini A, Mann J, Kolog H, Steinberg D, Zambon JJ, Haraszthy VI, da Silva MP, De Vizio W. A 6-month study of the effects of 0.3% triclosan/copolymer dentifrice on dental implants. *J Clin Periodontol* 2011; **38**: 33–42.
59. Takasaki AA, Aoki A, Mizutani K, Kikuchi S, Oda S, Ishikawa I. Er: YAG laser therapy for peri-implant infection: a histological study. *Laser Med Sci* 2007; **22**: 143–157.
60. Tawse-Smith A, Duncan WJ, Payne AG, Thomson WM, Wennström JL. Relative effectiveness of powered and manual toothbrushes in elderly patients with implant-supported mandibular overdentures. *J Clin Periodontol* 2002; **29**: 275–280.
61. Teughels W, Van AN, Sliepen I, Quirynen M. Effect of material characteristics and/or surface topography on biofilm development. *Clin Oral Implants Res* 2006; **17**(Suppl. 2): 68–81.
62. Thone-Muhling M, Swierkot K, Nonnenmacher C, Mutters R, Flores-de-Jacoby L, Mengel R. Comparison of two full-mouth approaches in the treatment of peri-implant mucositis: a pilot study. *Clin Oral Implants Res* 2010; **21**: 504–512.
63. Tomasi C, Derks J. Clinical research of peri-implant diseases – quality of reporting, case definitions and methods to study incidence, prevalence and risk factors of peri-implant diseases. *J Clin Periodontol* 2012; **39**(Suppl. 12): 207–223.
64. Tomasi C, Wennstrom JL. Full-mouth treatment vs. the conventional staged approach for periodontal infection control. *Periodontol 2000* 2009; **51**: 45–62.
65. Truhlar RS, Morris HF, Ochi S. The efficacy of a counter-rotational powered toothbrush in the maintenance of endosseous dental implants. *J Am Dent Assoc* 2000; **131**: 101–107.