

PATIENT MEDICAL HISTORY

Male
62 years old
Non-smoker

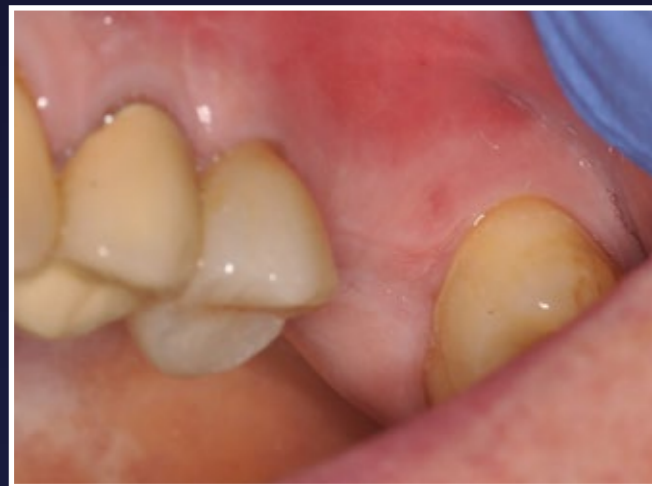High blood pressure
Meds: Amitriptyline, Propranolol, Lercanidipine
Allergies: Penicillin allergy

Missing UL6, only 3mm bone availability below sinus

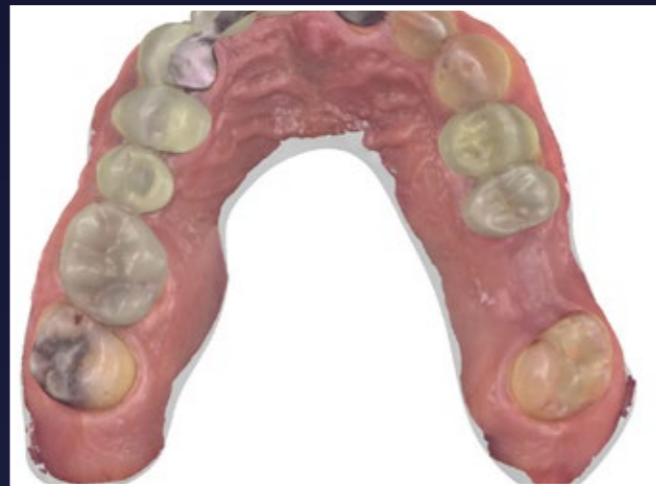Case from Dr Kris Leeson,
York, UK



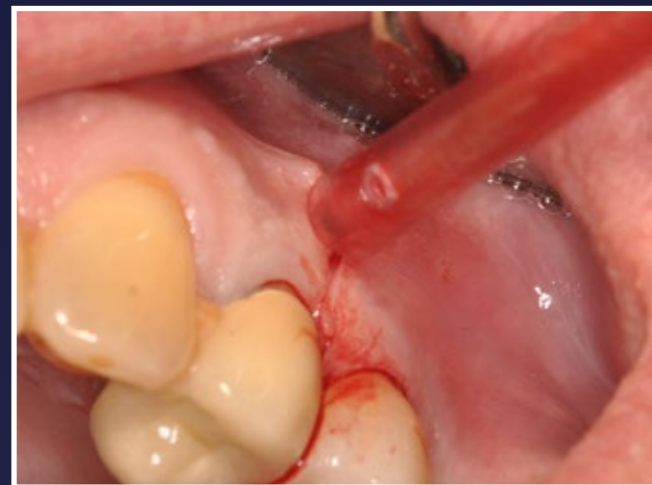
🇬🇧 Dr Kris Leeson



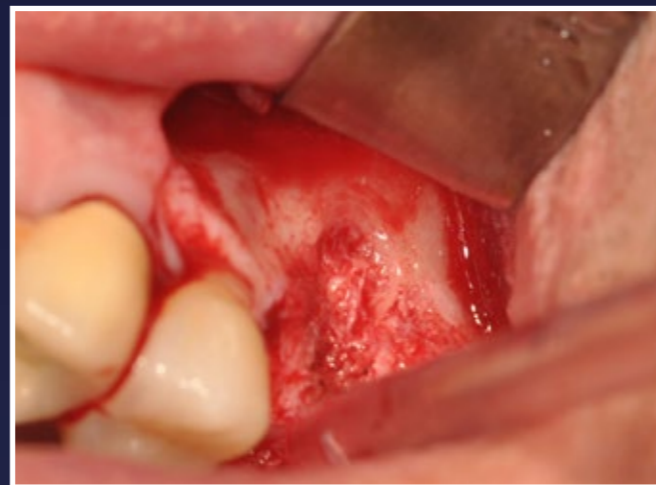1. Pre-op



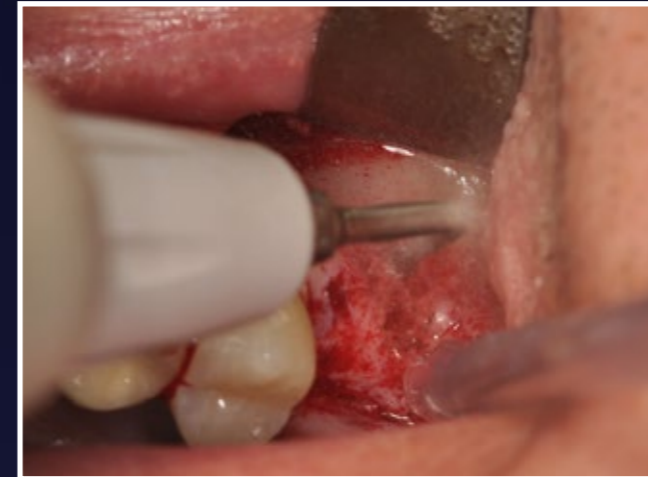
2. Digital impression pre-op



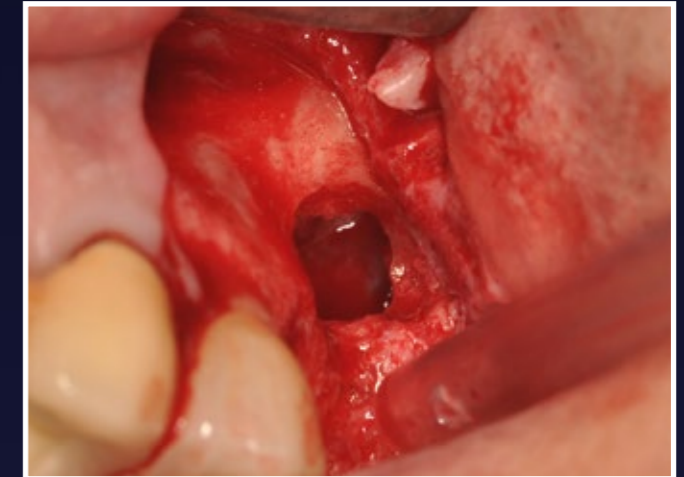3. Initial relieving incision



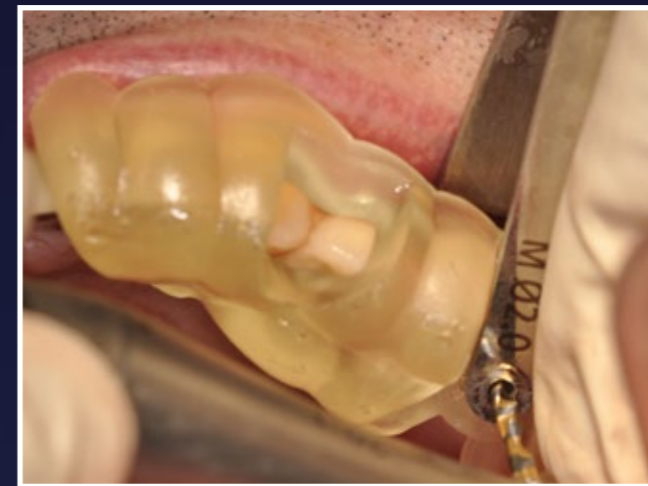4. Exposed lateral wall of sinus



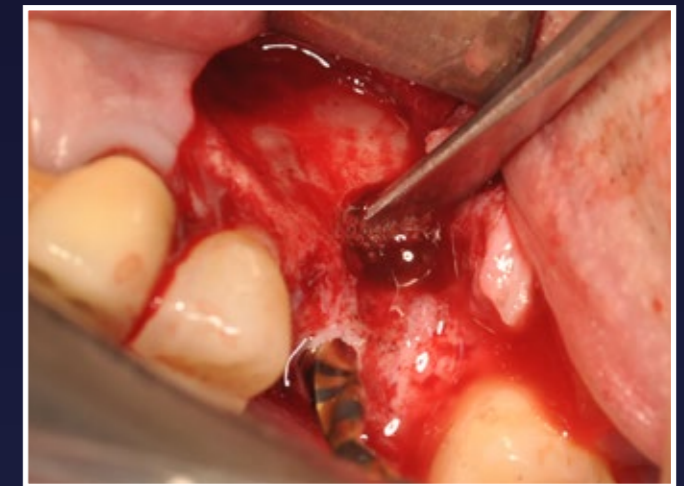5. Piezo used to open window



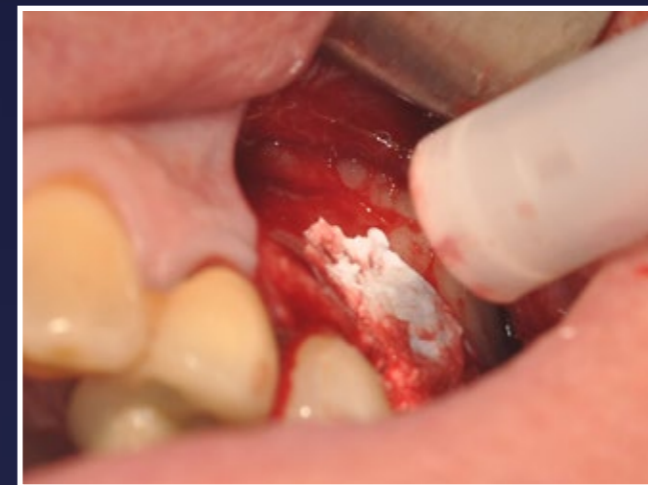6. Lateral window



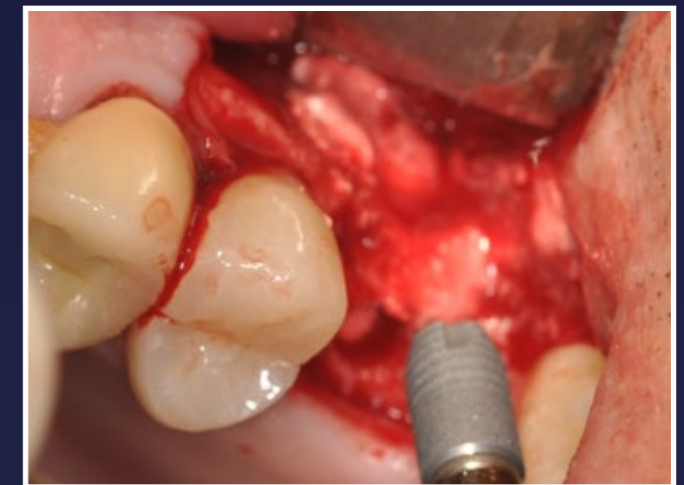
7. Surgical pilot guide used



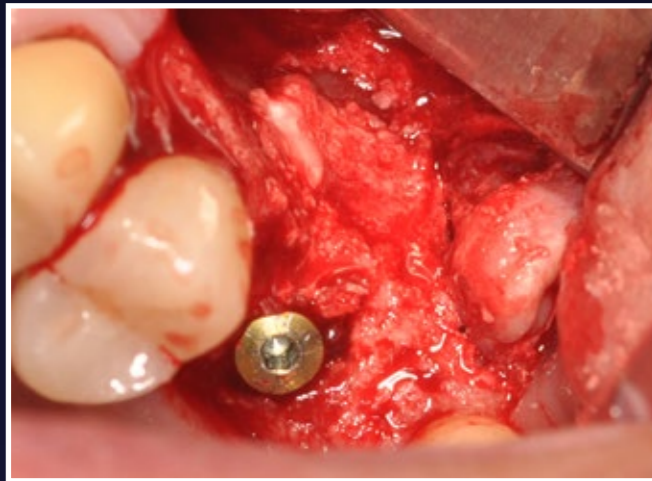
8. Osteotomy prepared



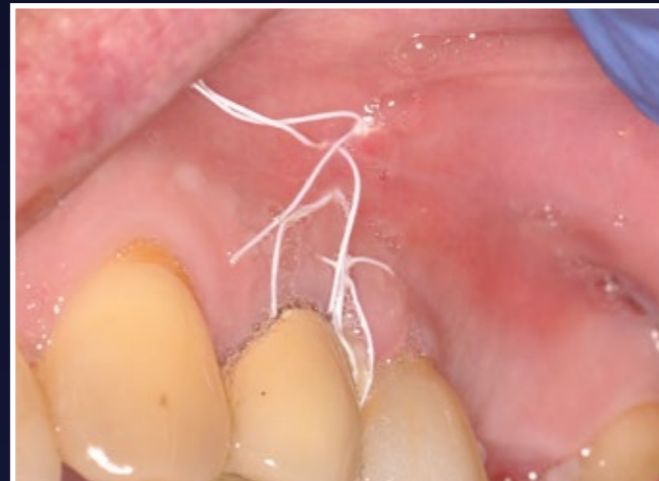9. EthOss placement



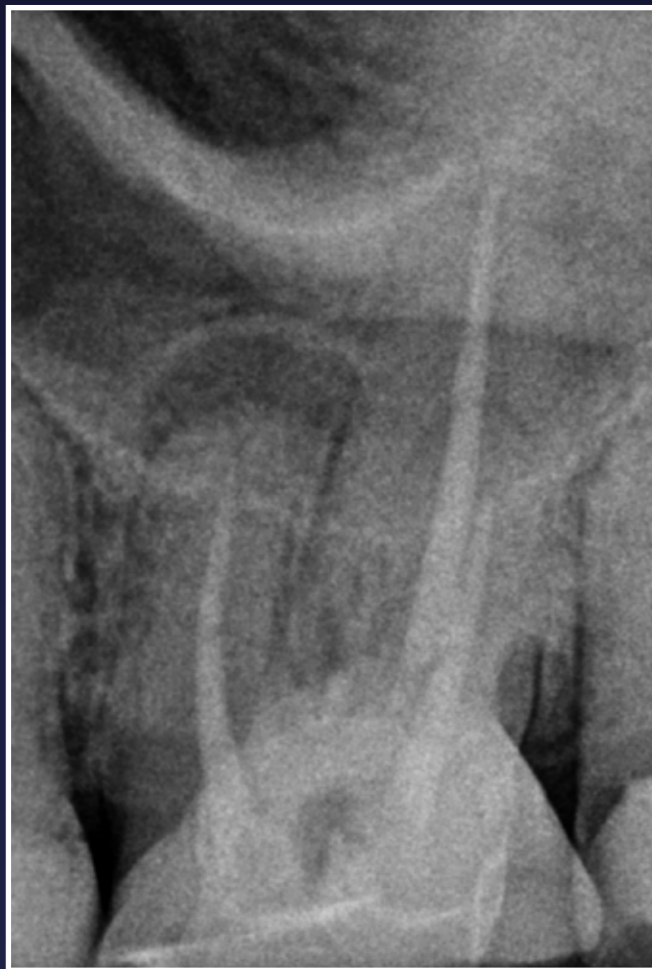10. Implant placed



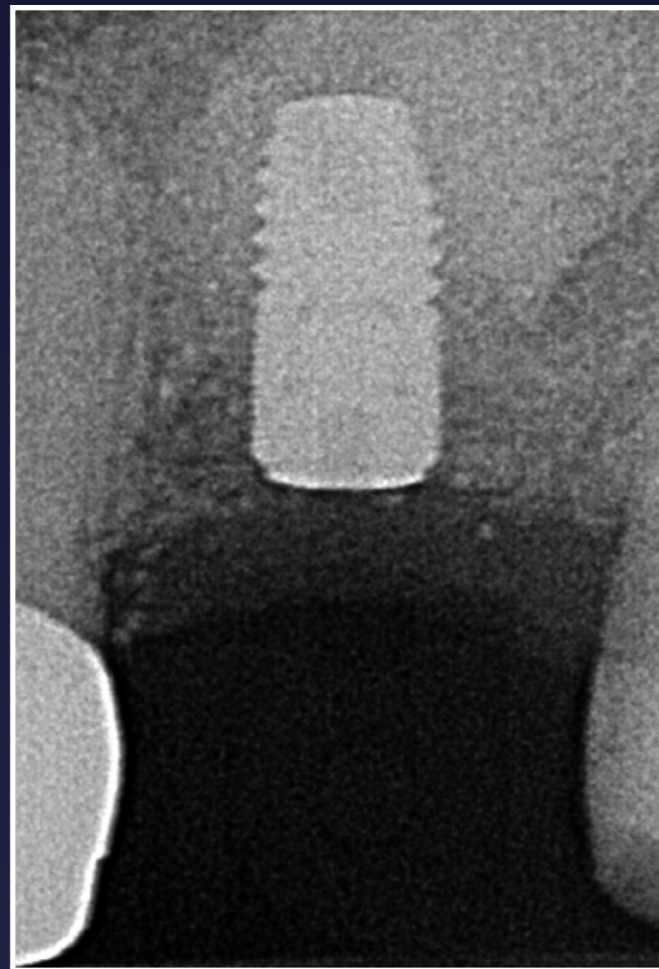
11. Cover screw in situ



12. Post-op sutured with 4/0 Teflon

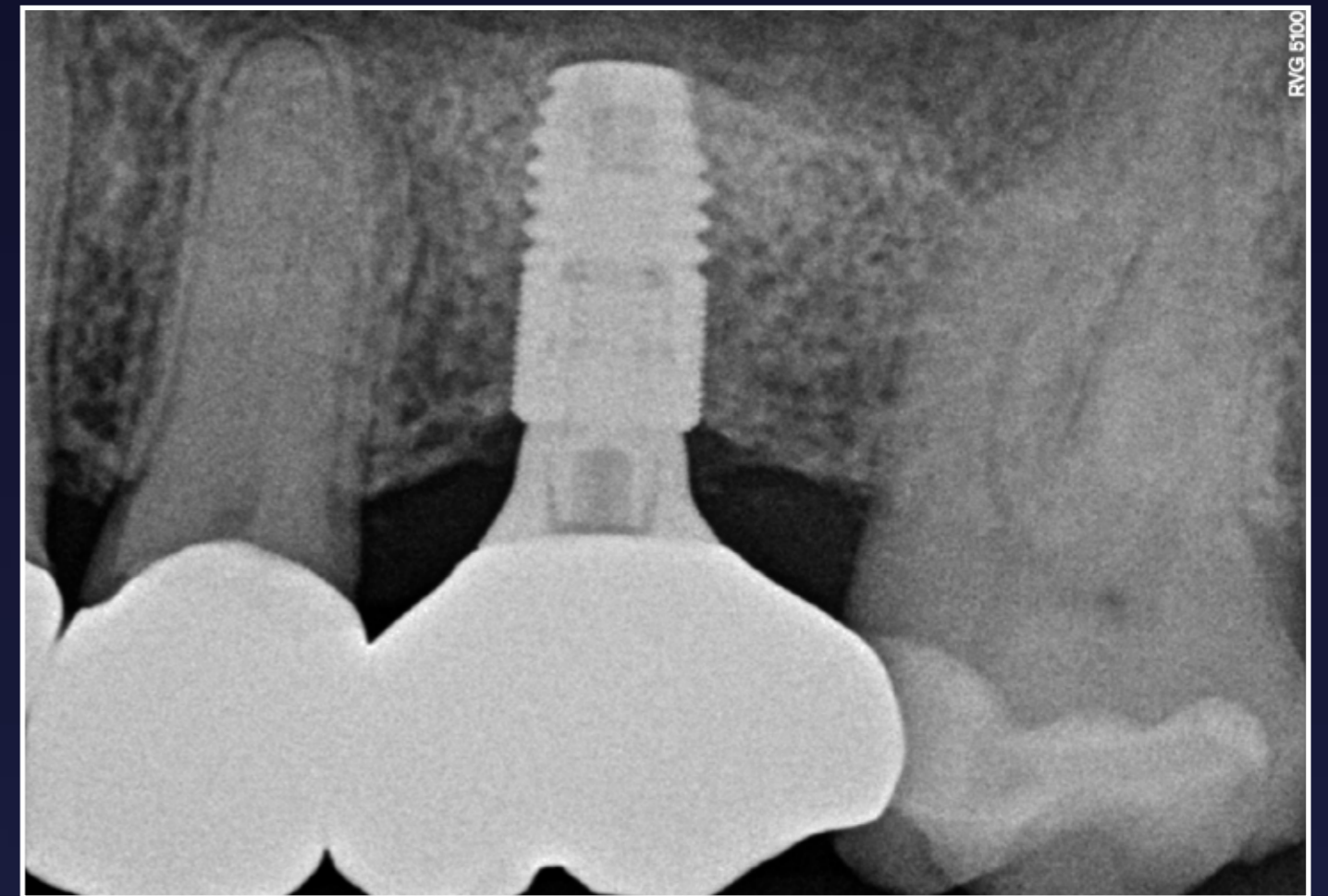


13. Initial radiograph before extraction



14. Radiograph immediately post-op

RESULTS



15. Loaded at 1 year

[Return to contents](#)