

PATIENT MEDICAL HISTORY

Male
45 years old
Non-smoker

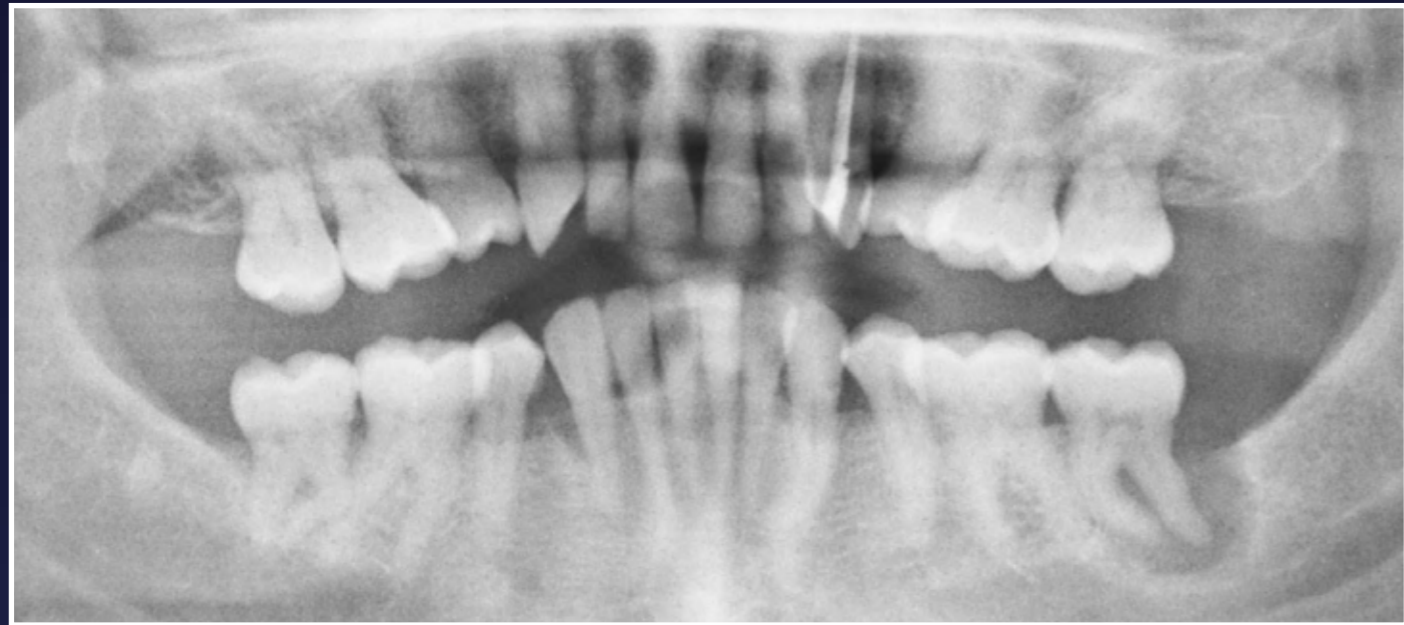Incidental finding of periodontal pocketing and bone loss distal LL7 aspect on OPT

Referring GDP feared implant replacement would not be possible due to extensive bone loss

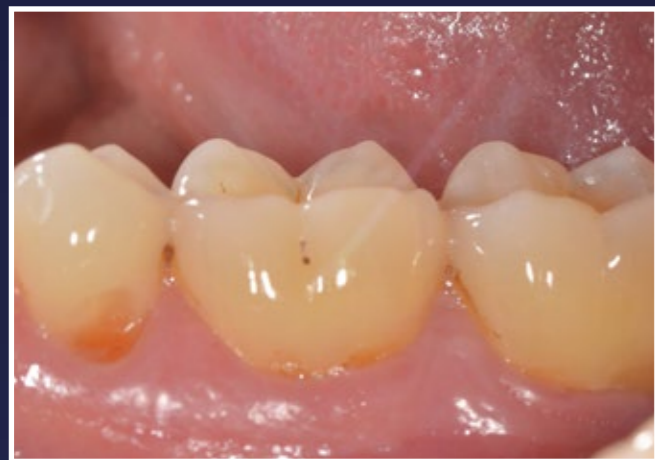Case from Dr Jonathan Cochrane, Bristol, UK



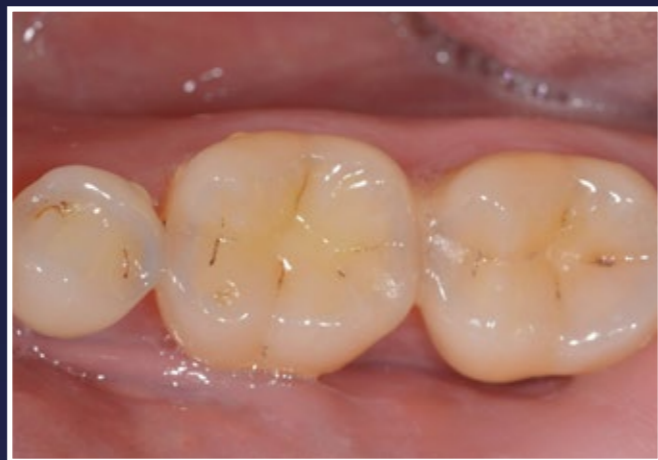🇬🇧 Dr Jonathan Cochrane



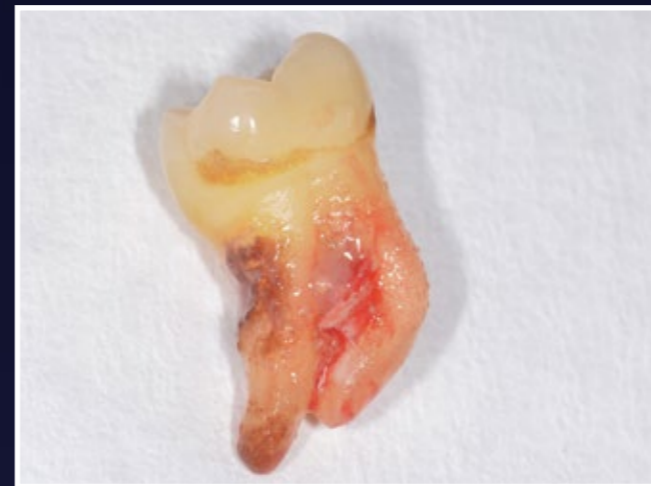1. Panoramic radiograph showing defect



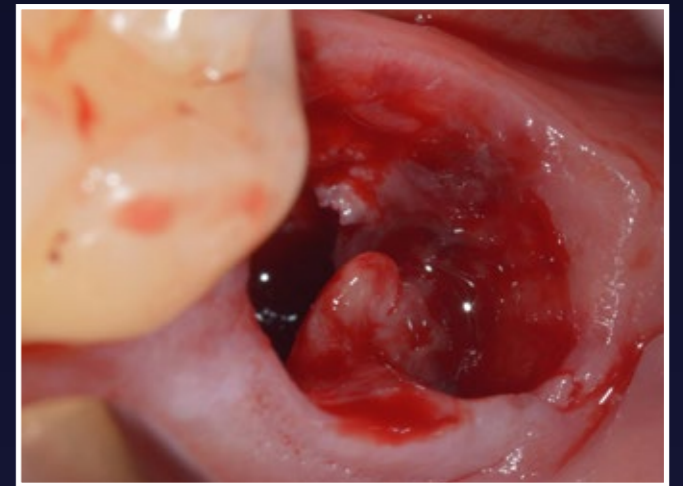
2. No visible problems



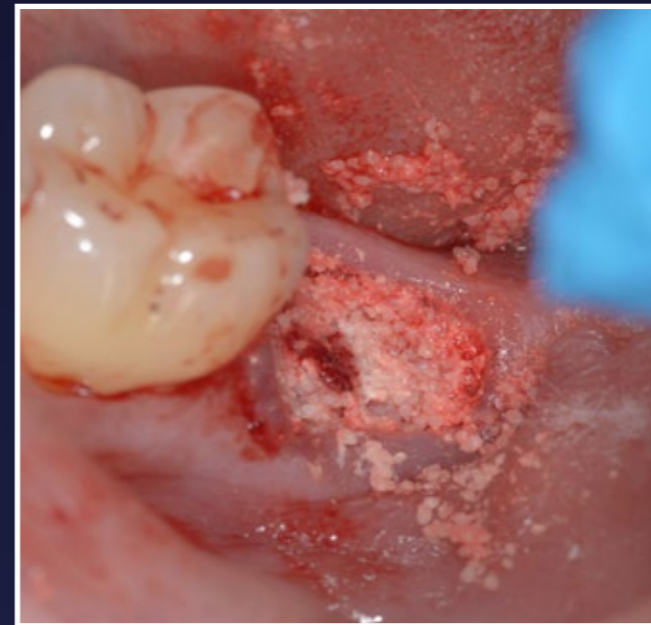3. No visible problems



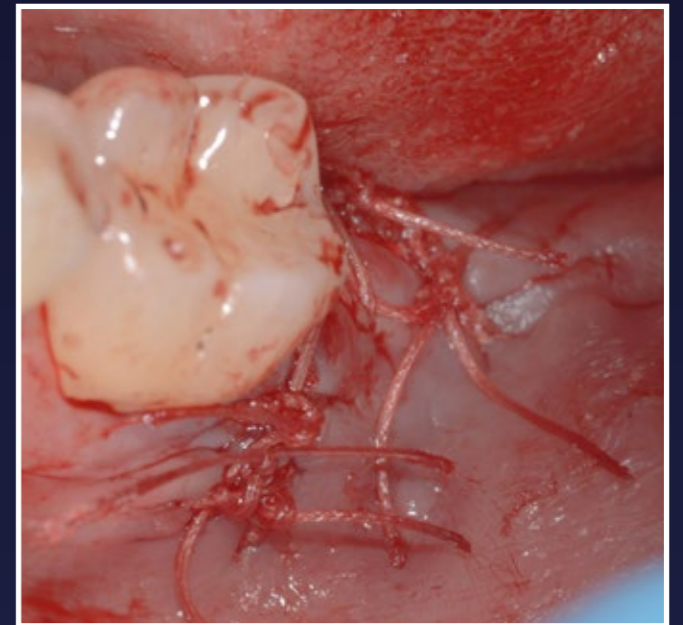
4. LL7 post extraction - problem is now visible



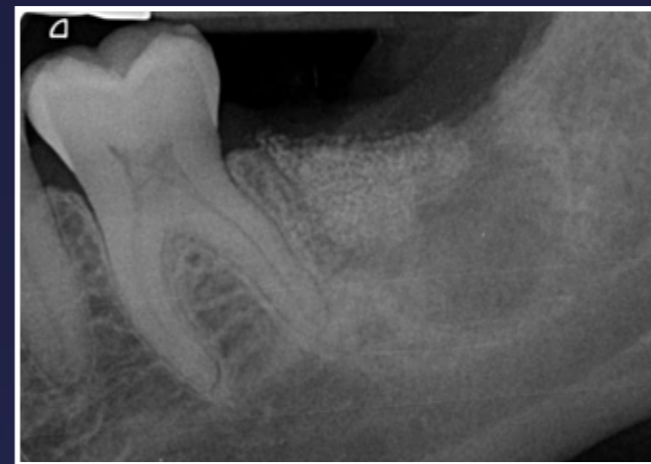5. Extraction socket prior to degranulation



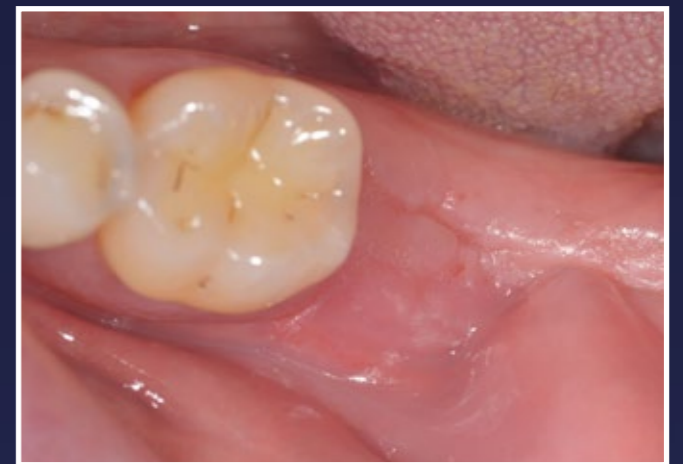6. EthOss bone graft material is placed and dried with a sterile gauze for 5 minutes



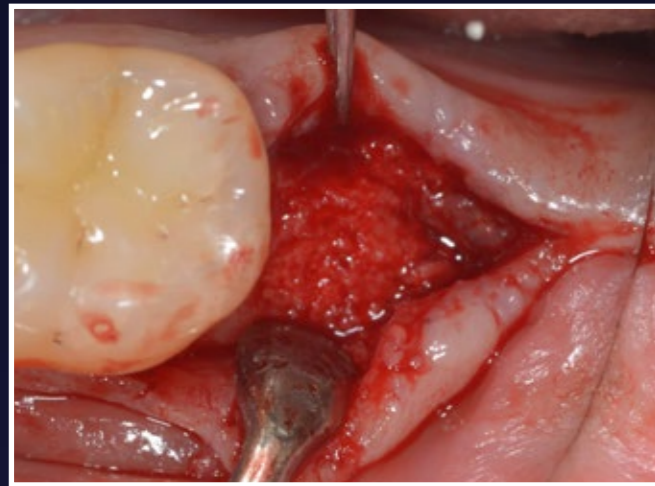
7. Flap released and sutured shut



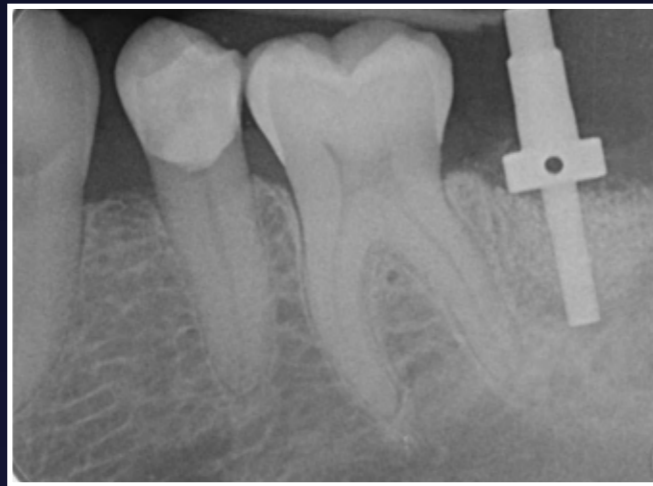8. Radiograph showing 10 weeks post-op



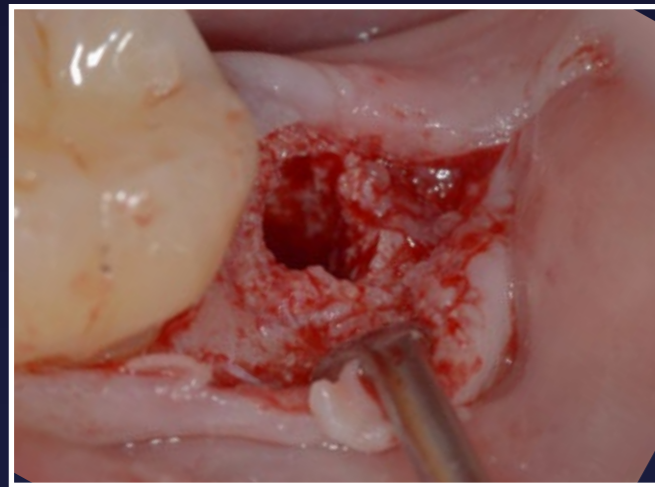
9. Healthy soft tissue and very wide ridge



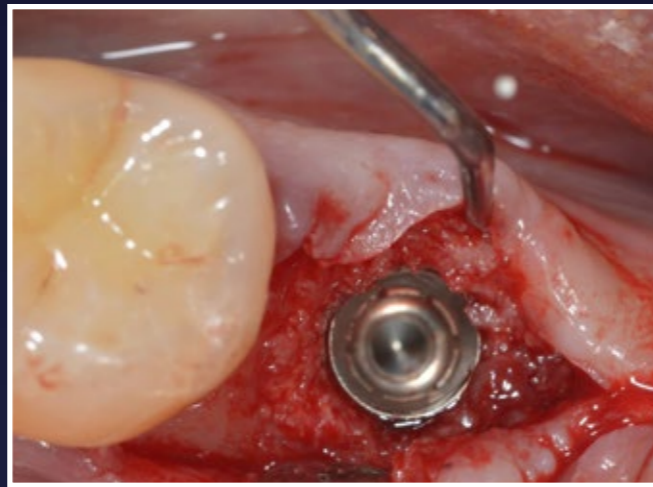
10. Flap raised showing new host regenerated bone



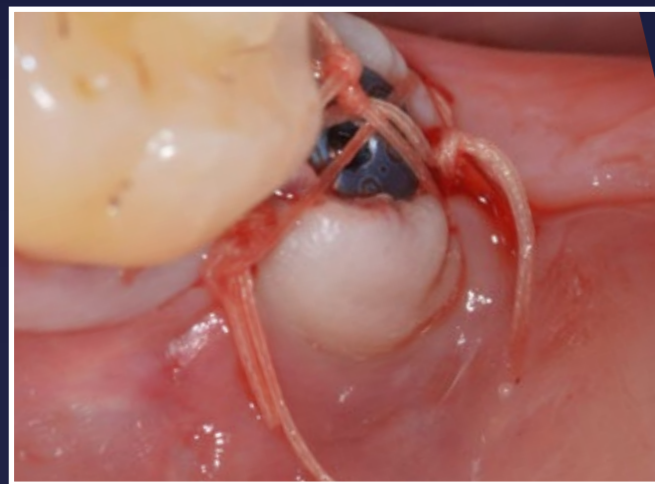
11. Radiograph prior to implant placement



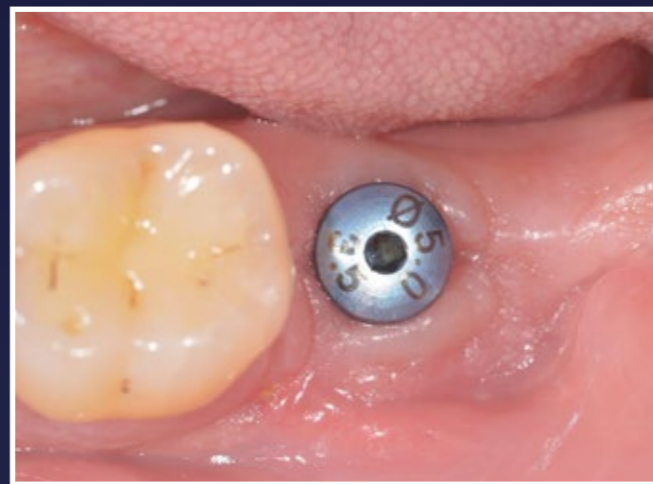12. D4 quality bone formation



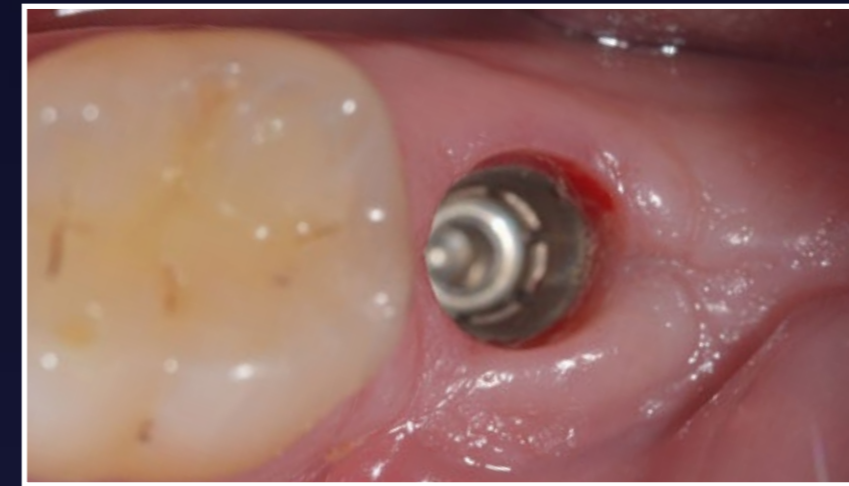
13. 4.8mm diameter Astra EV implant is placed



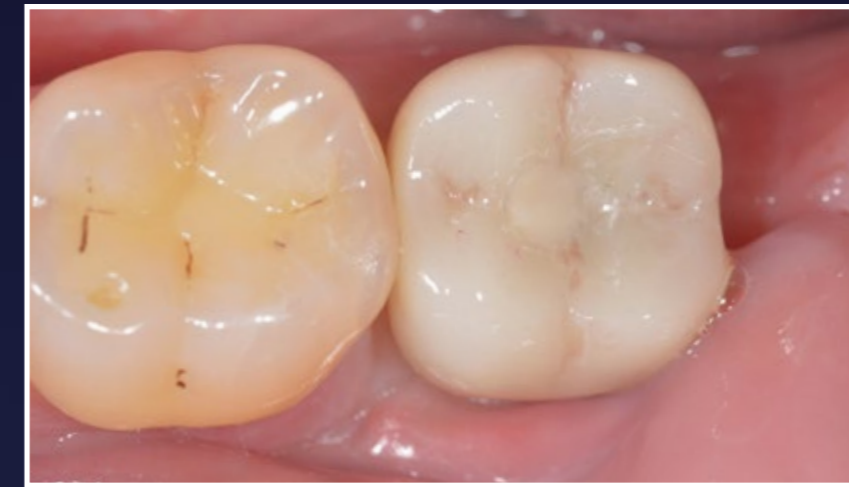14. Sutured closed with vicryl. Note new (buccal) keratinised tissue formation



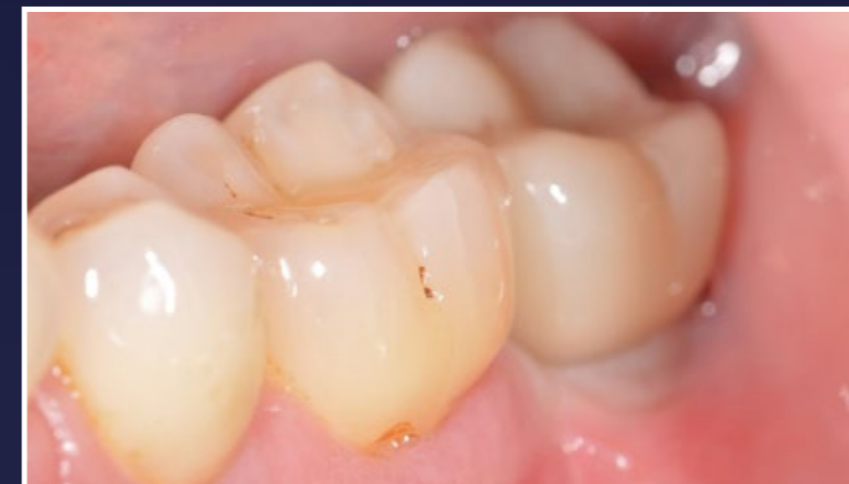15. 10 weeks further healing



16. Healthy soft tissue maturation

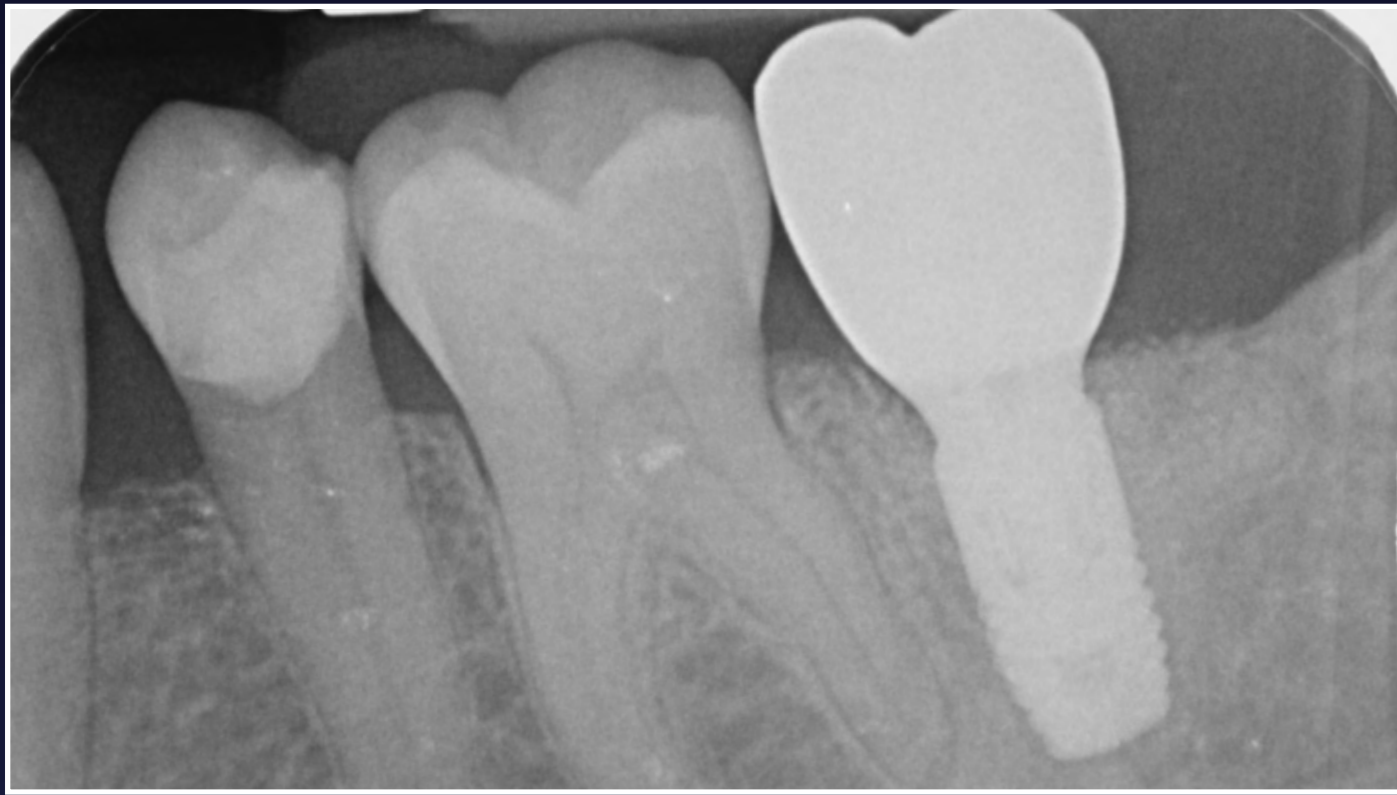

17. Zirconia crown in place

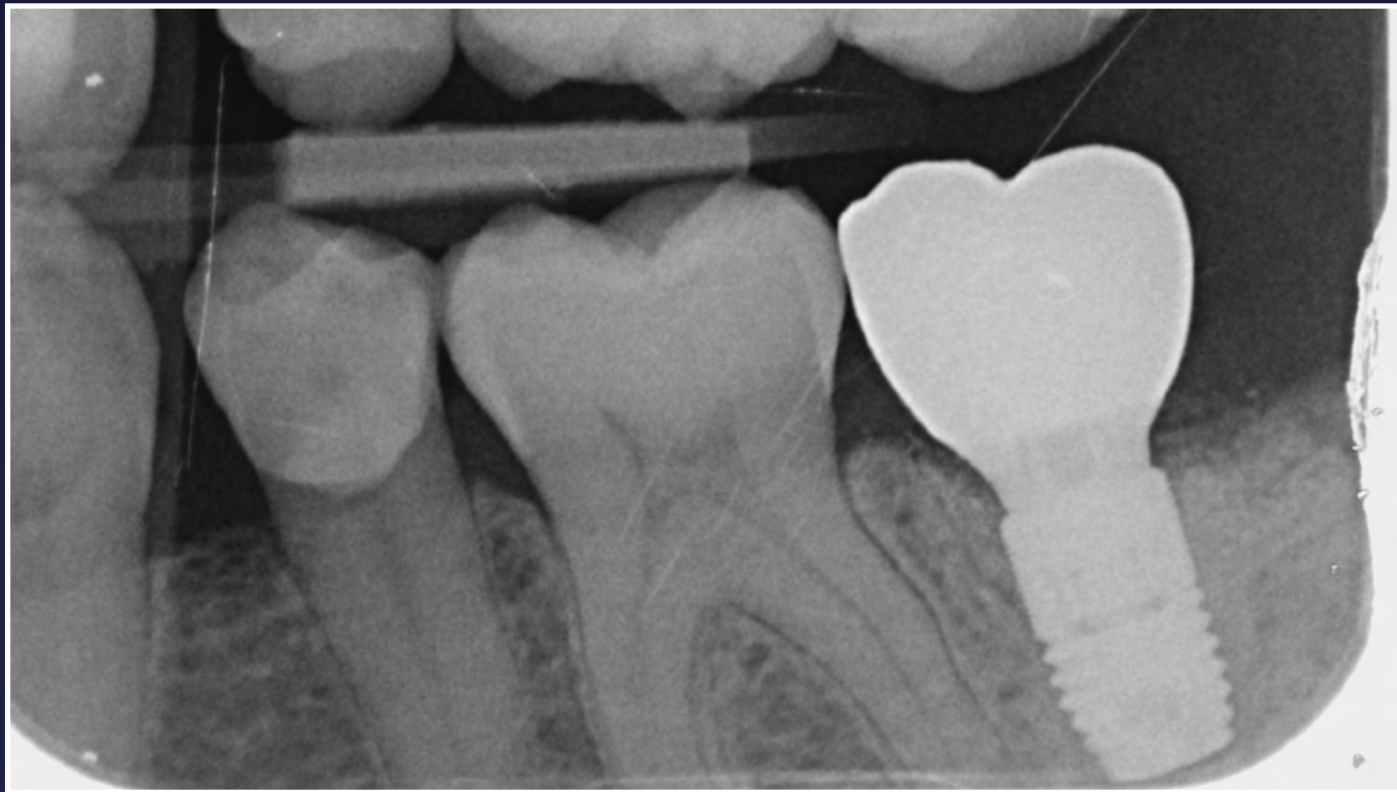

18. Happy with the outcome

RESULTS



1. Final PA showing excellent results



2. 1 year recall showing bone levels maintained

**GROW
STRONGER**