

PATIENT MEDICAL HISTORY

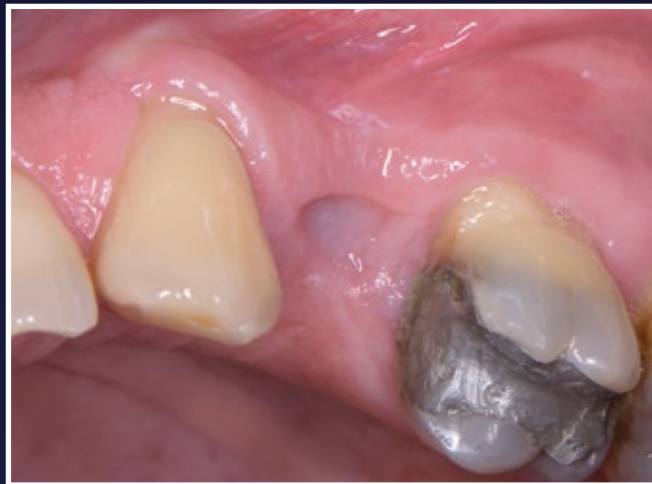Female
55 years old
Healthy, non-smoker

Patient suffered from a root fracture. Needed removal and to restore hard and soft tissue

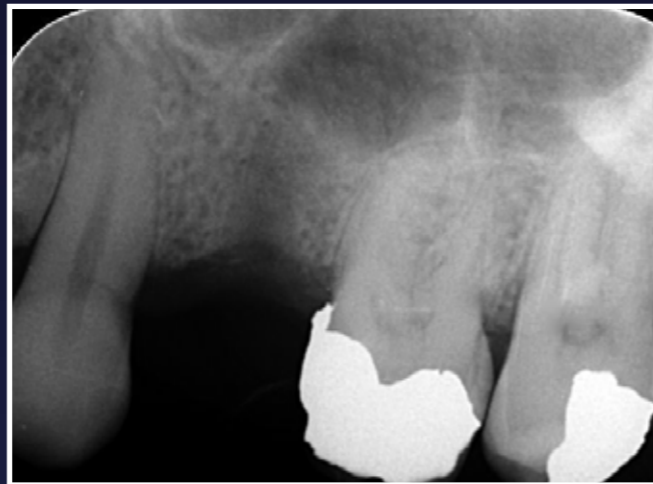Case from Dr Minas Leventis, Greece



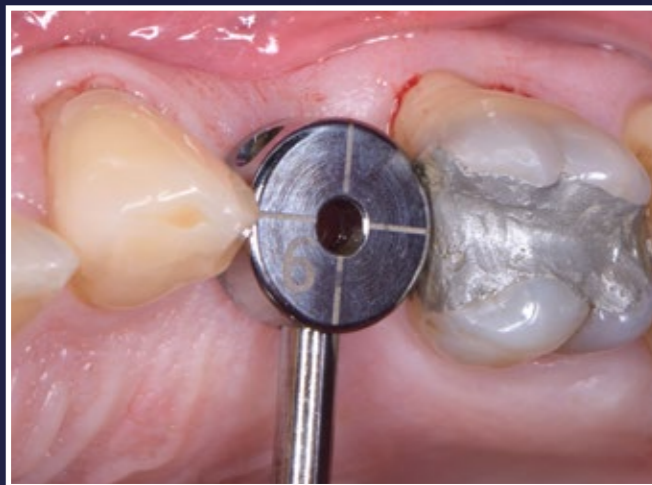
Dr Minas Leventis



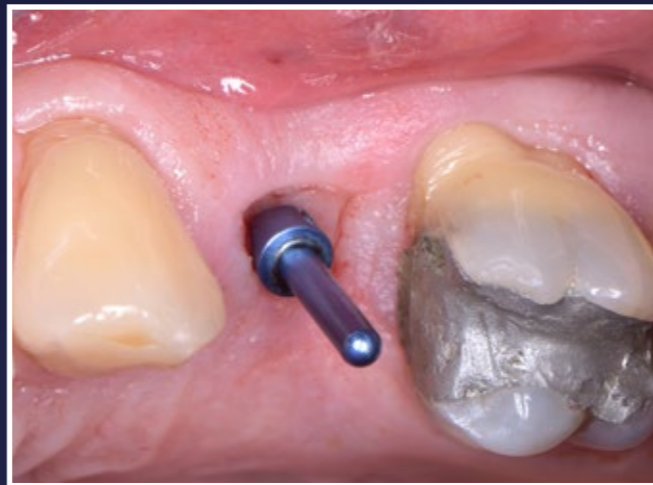1. Initial situation 3 weeks after simple extraction of the upper left second premolar



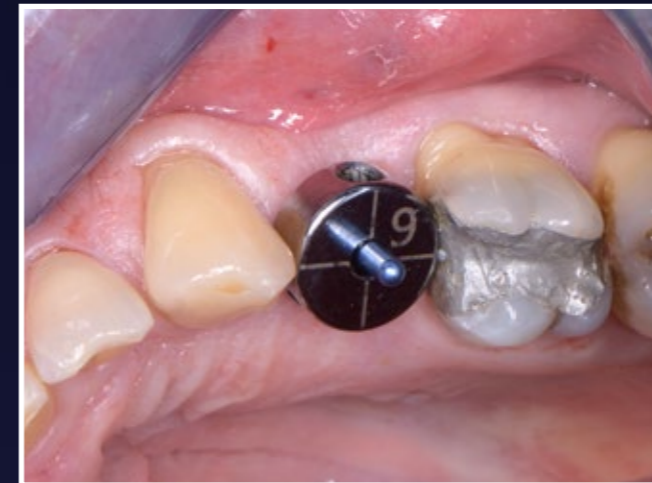2. Initial periapical x-ray



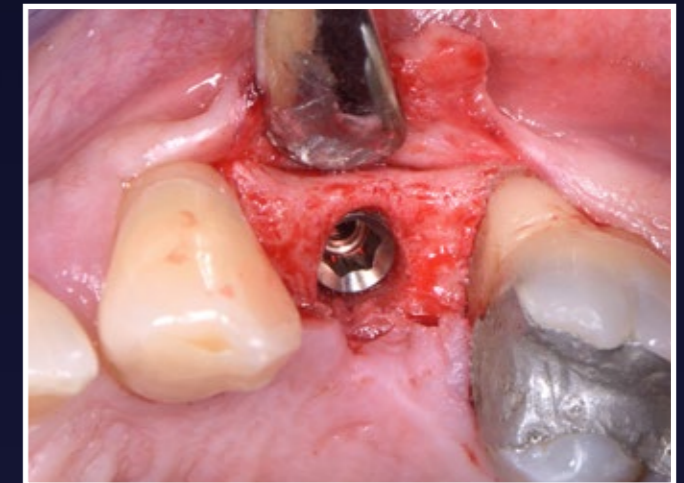
3. Intraoral evaluation of the edentulous space



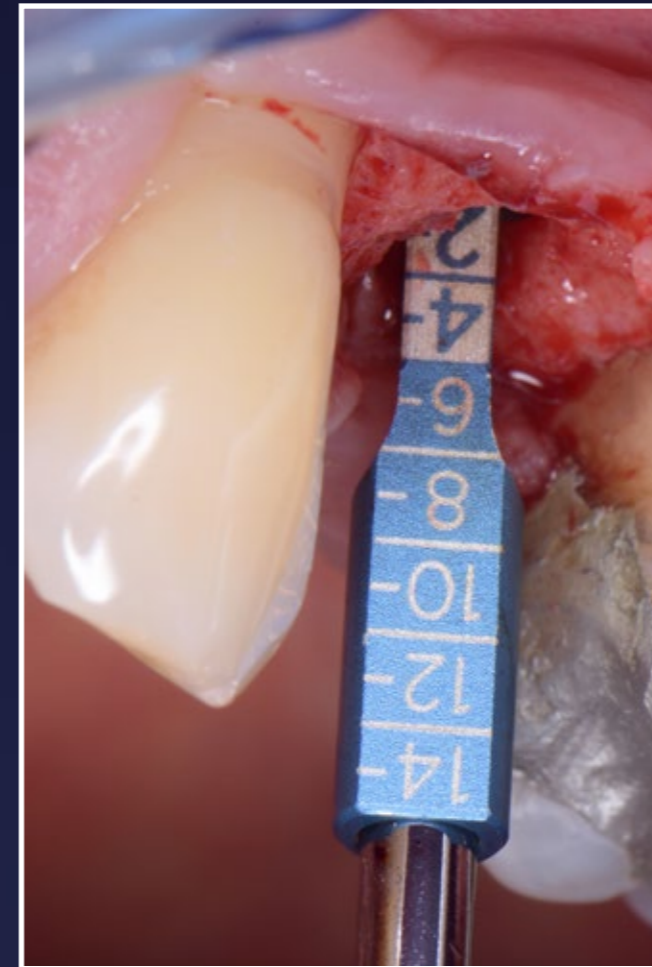
4. Distances measured and position of the initial pilot osteotomy identified



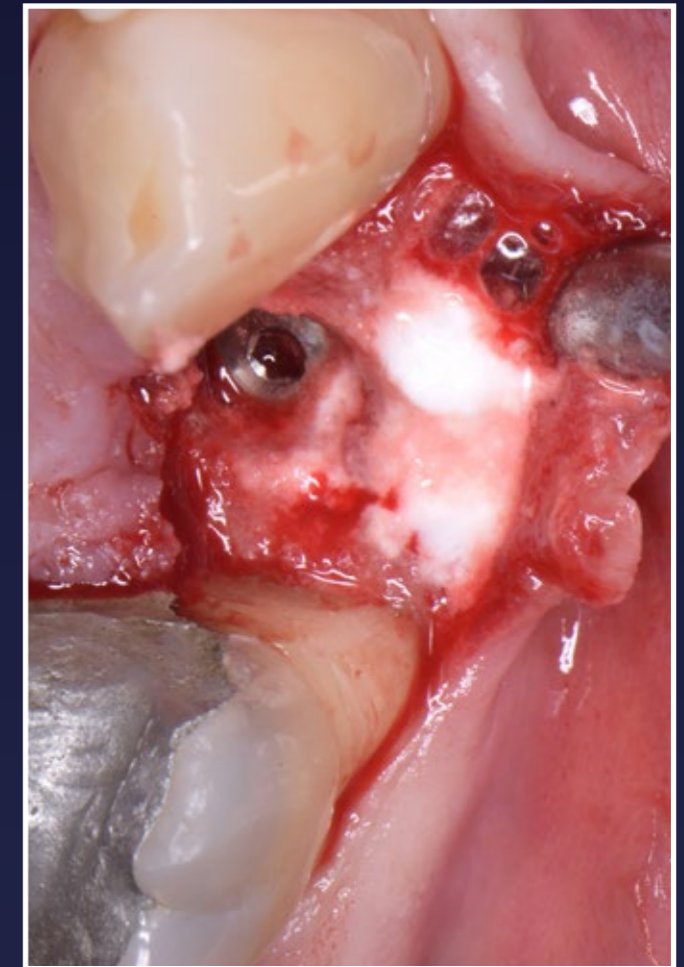
5. Distances measured and position of the initial pilot osteotomy identified



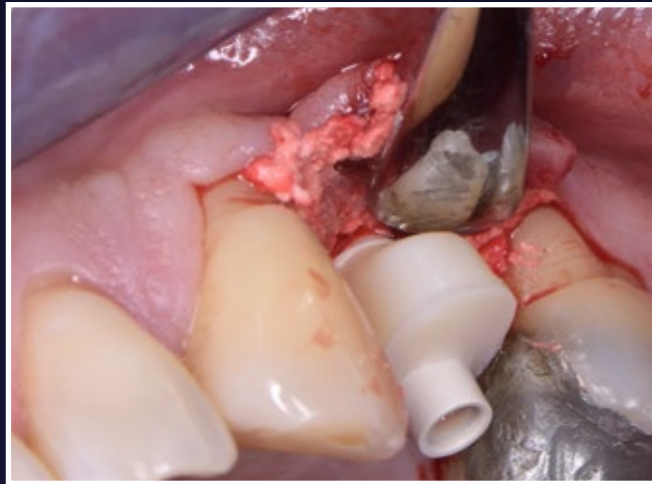
6. A site-specific full-thickness flap was raised and a Paltop Dynamic 4.0x8.0 implant was placed 1mm subcrestally, achieving excellent initial stability



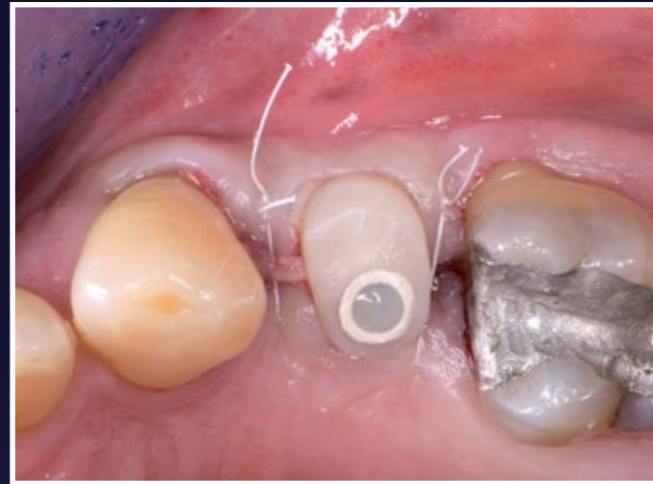
7. Measurement of the depth of placement and the thickness of the overlying soft tissues



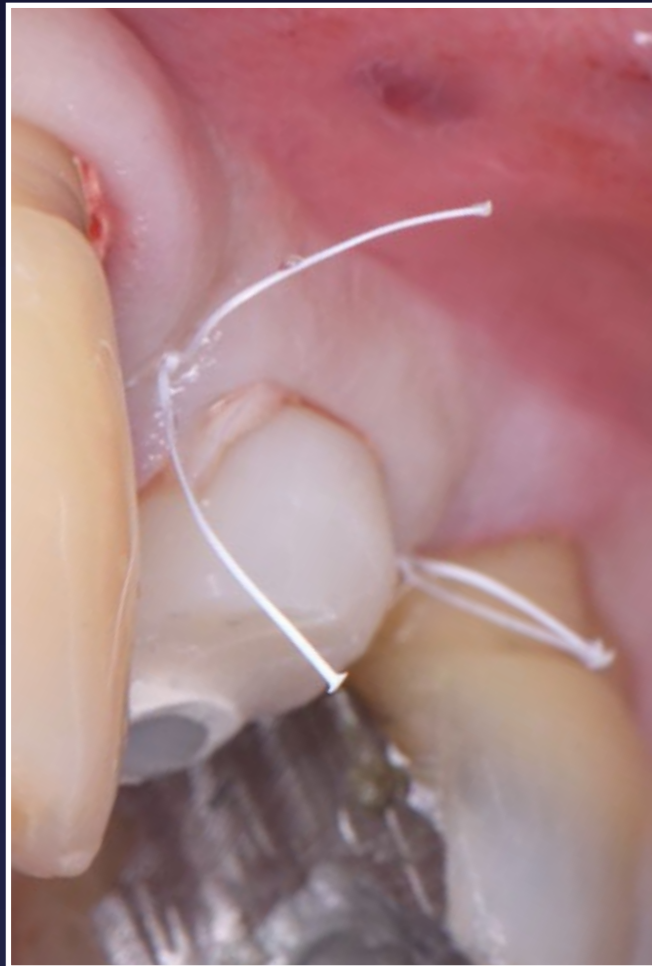8. The buccal area was grafted with 0.5cc EthOss



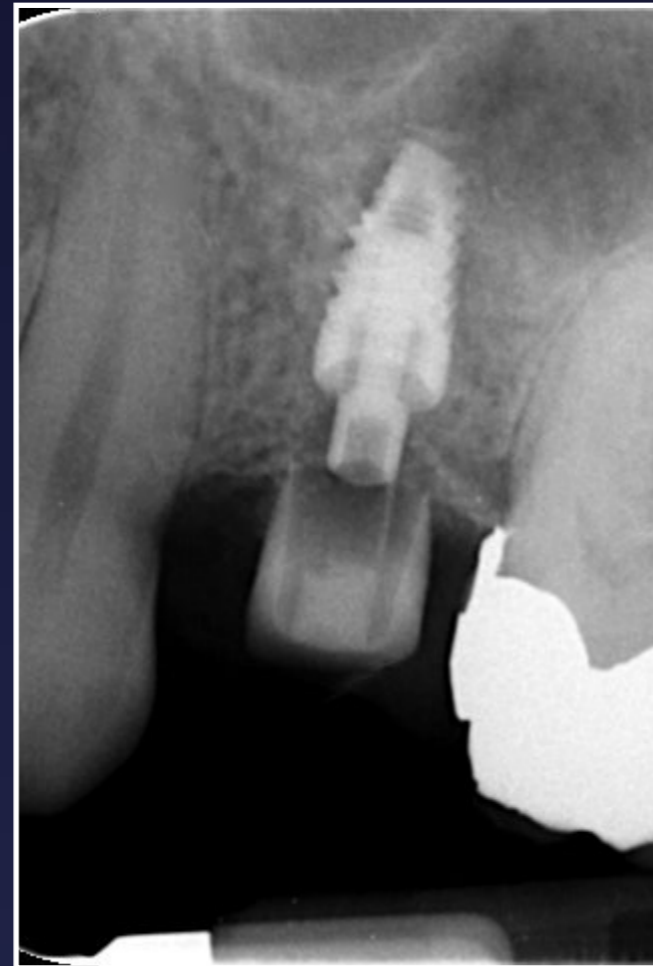
9. Using the Cervico mould a customised healing abutment was fabricated and fitted



10. Clinical views immediately post-op

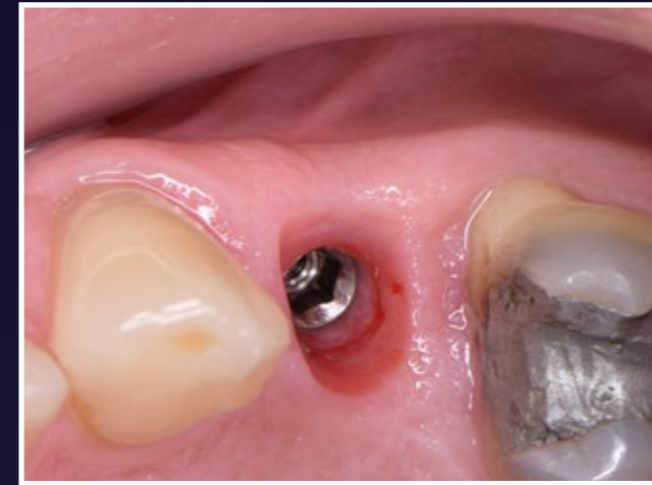

11. Clinical views immediately post-op

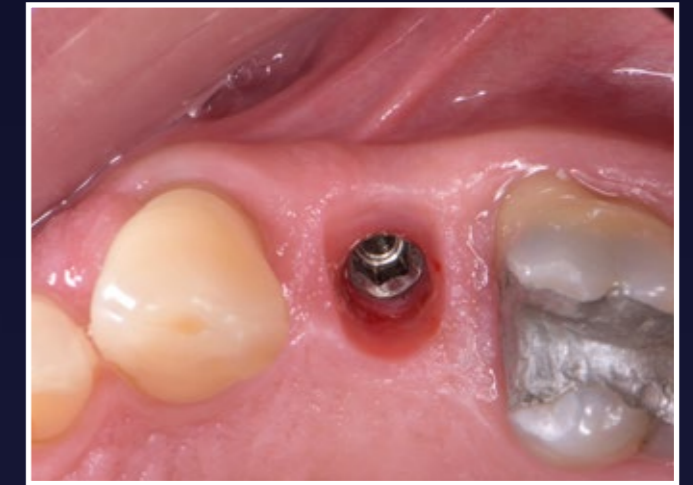


12. Periapical x-ray immediately post-op

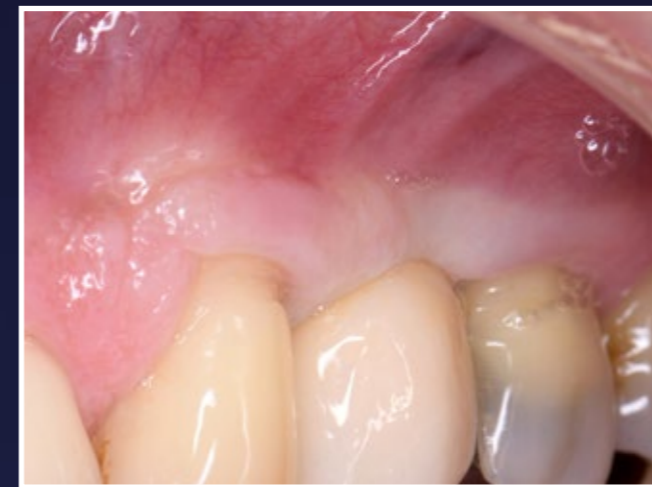RESULTS



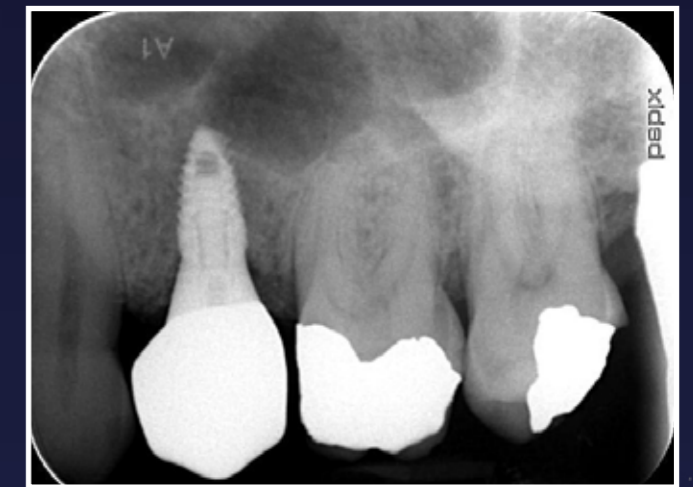13. Clinical views 3 months post-op



14. Clinical views 3 months post-op



15. Clinical view immediately after fitting the implant crown



16. Final periapical x-ray