

PATIENT MEDICAL HISTORY

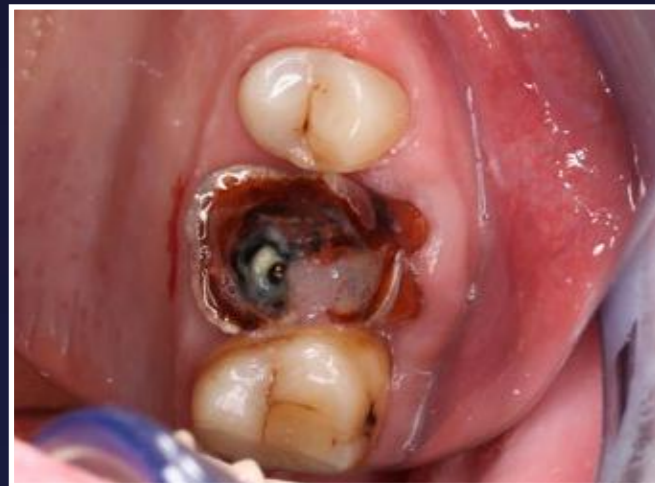Male
49 years old

Perio issues and heavy smoker

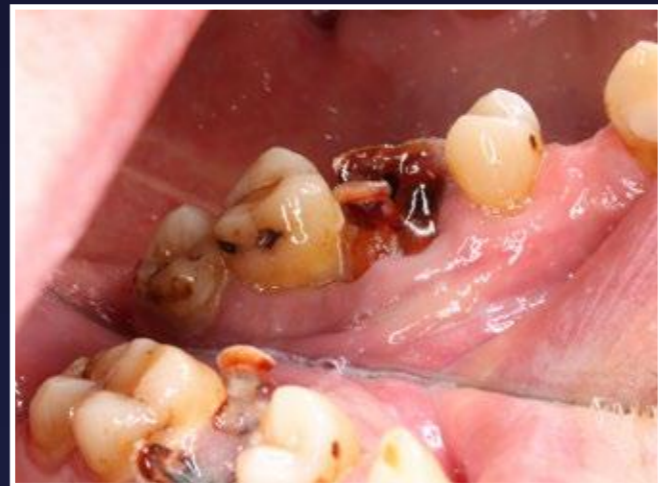Case from Dr Ragnar Ilp,
Estonia



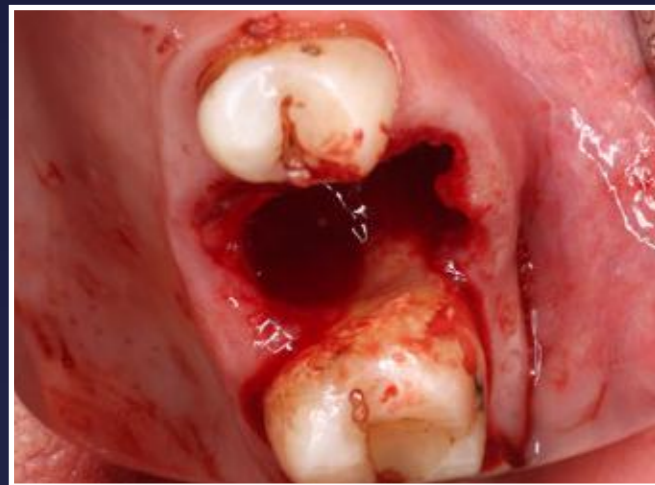Dr Ragnar Ilp



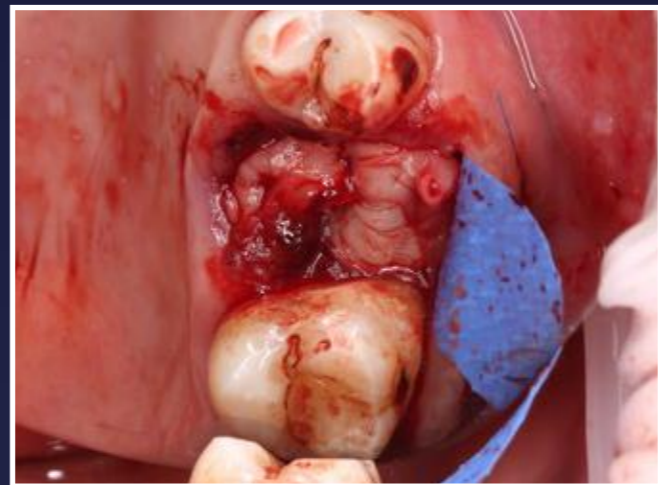1. Upper first molar (UR6). Hopeless diagnosis



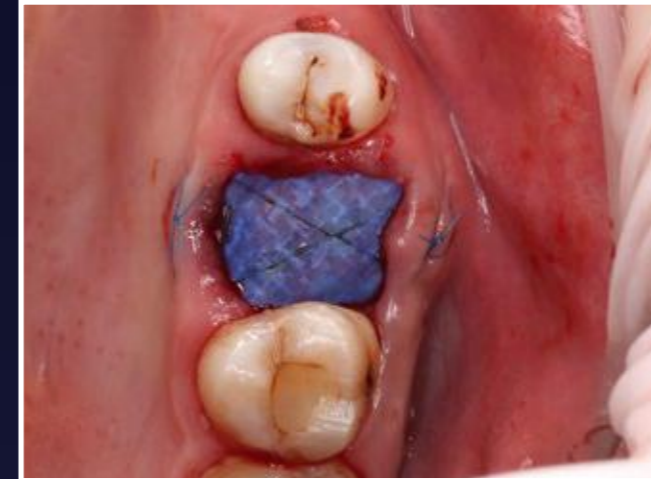2. Distal root is very close to the 2nd molar



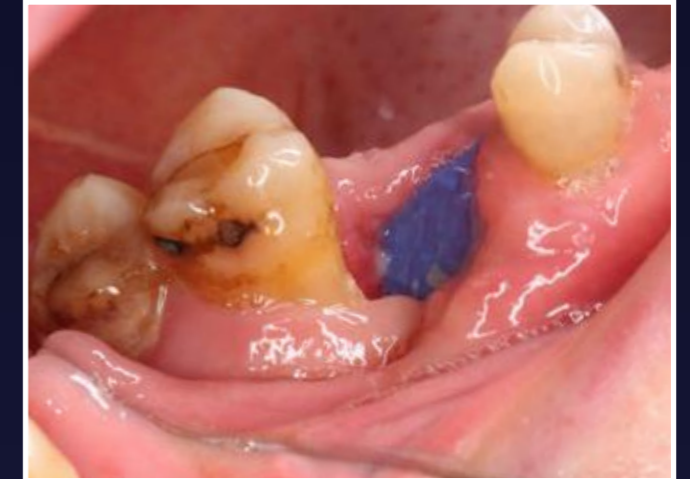3. MB root of 2nd molar has bone loss due to the proximity of the hopeless tooth. The buccal plate was also missing almost to the apices



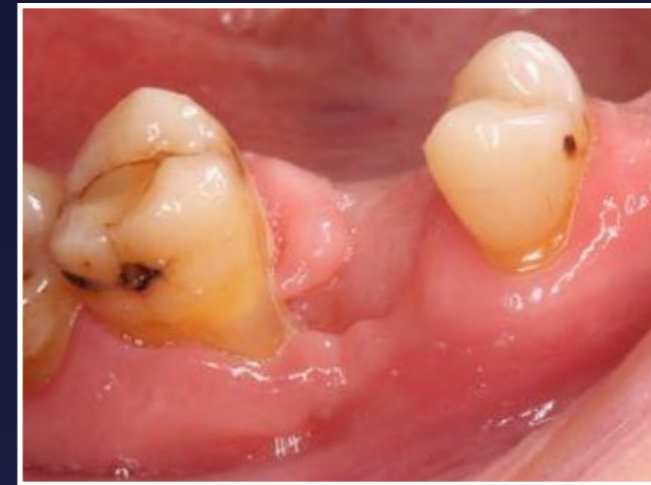4. Initial treatment using non resorbable PTFE membranes. Split thickness "pouches" on both sides, socket filled with PRF, no xenografts



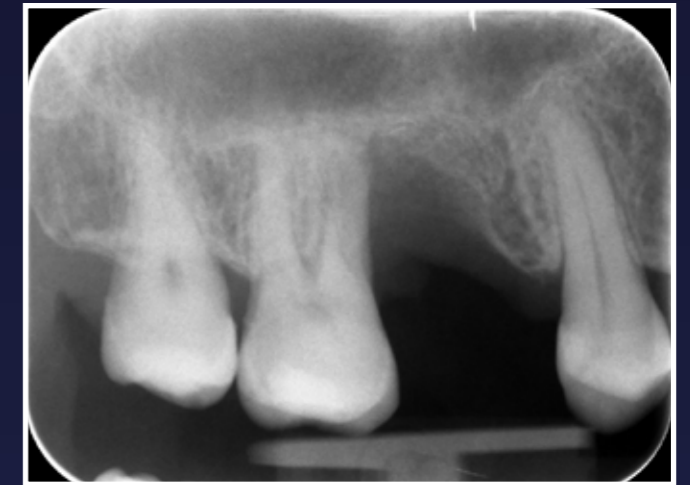5. Cross-suture to hold everything in place



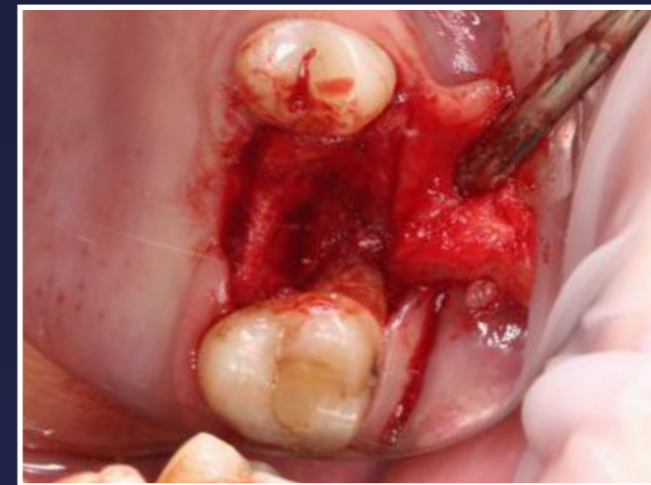6. 2 weeks later difficulties caused by lack of stability of both materials. After two additional weeks the membrane came off by itself



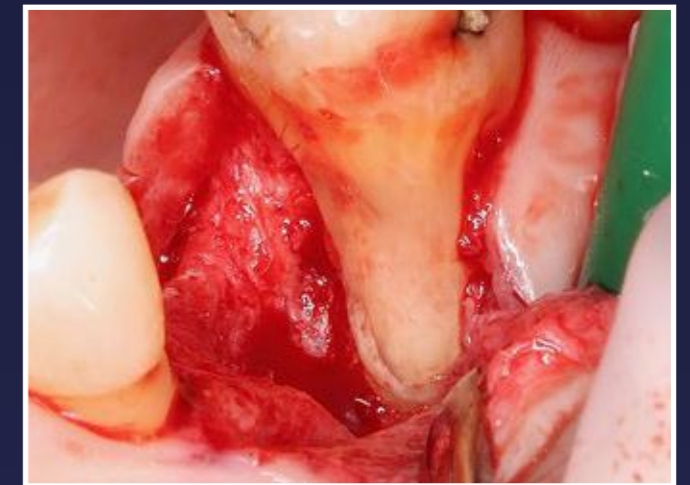
7. 5 months later, appointment time for implant surgery



8. Radiograph prior to surgery

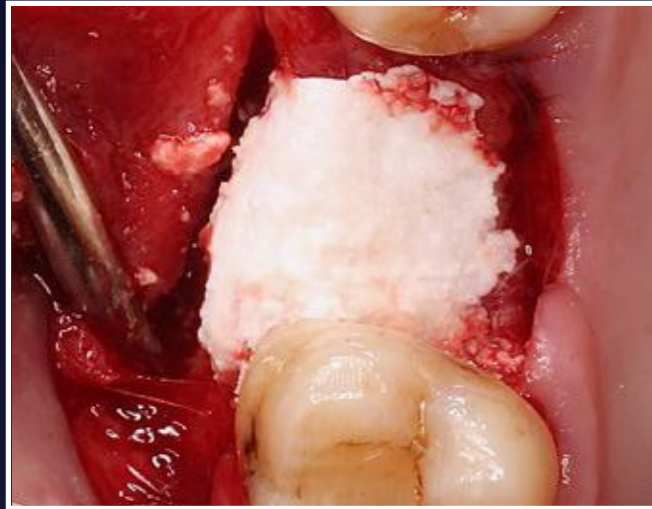

9. Degranulated site, bone loss almost to the apex of the 2nd molar

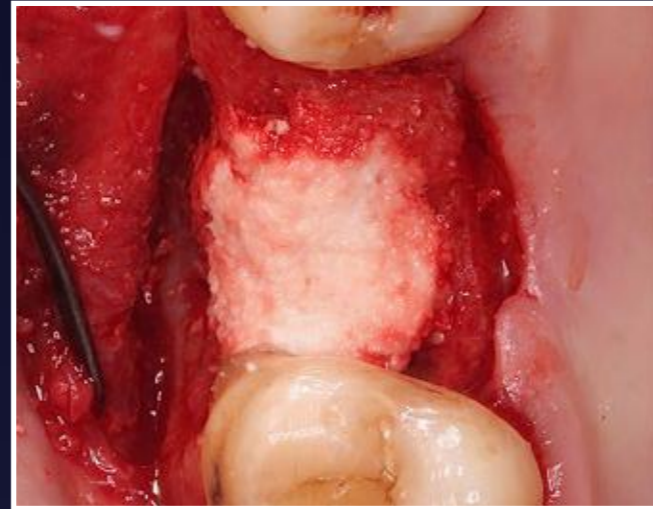


10. Defect clearly visible

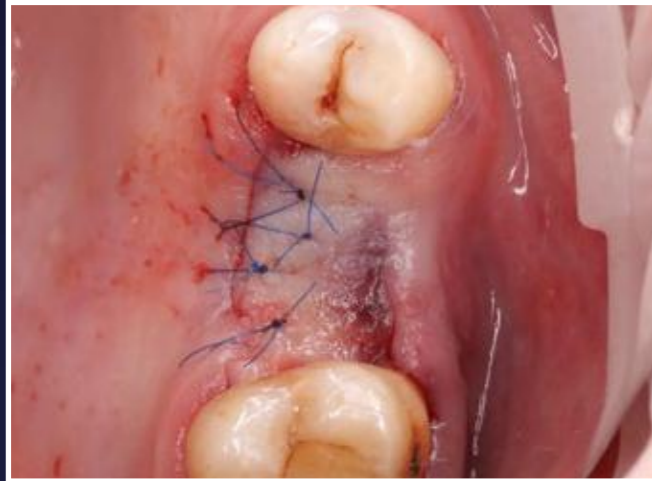Upper First Molar Socket Graft



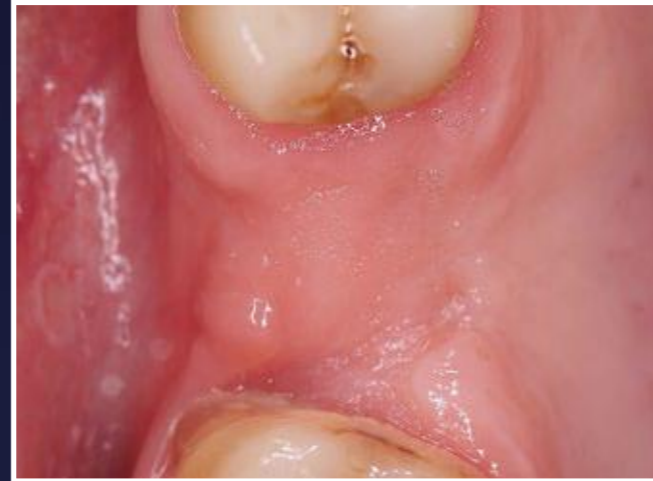11. Grafted the site with EthOss bone graft material



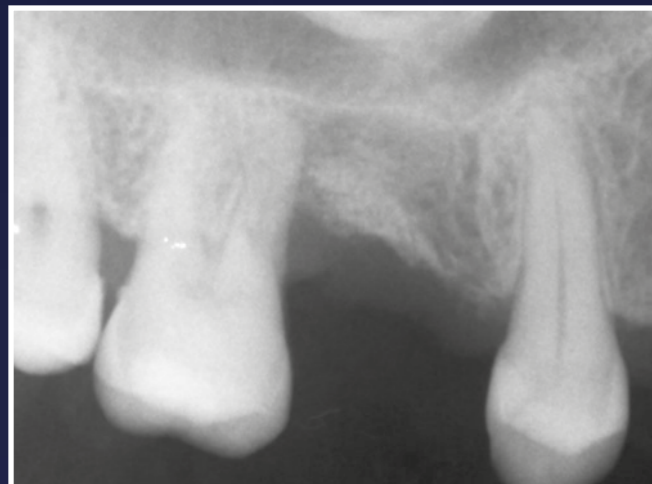12. EthOss graft set after applying pressure using sterile gauze and waiting 3 minutes



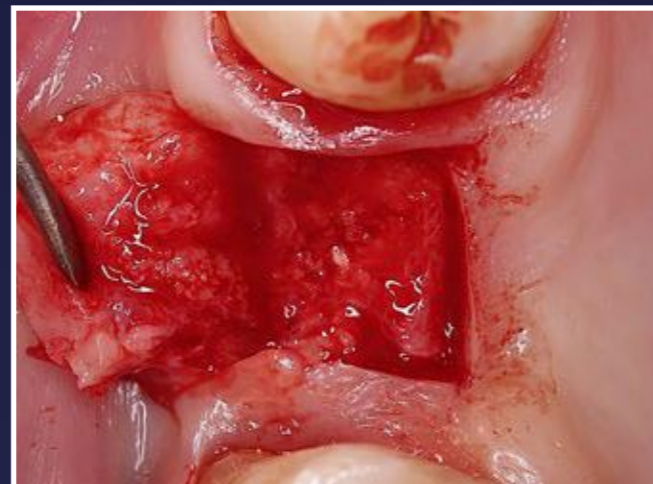13. Tension-free closure after periosteal release



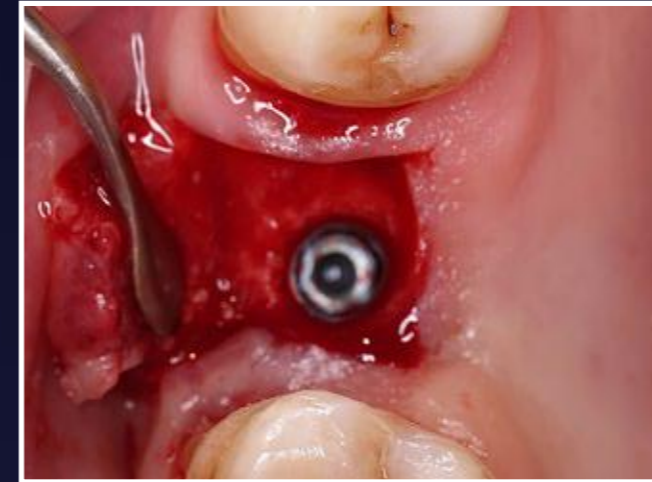
14. A further 6 months later due to patient's travels



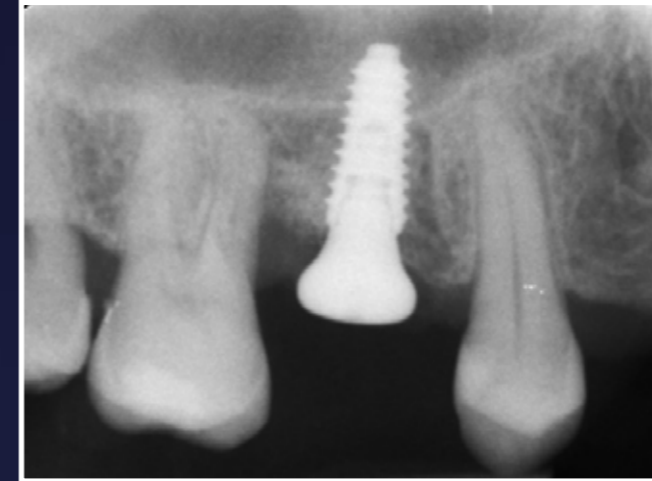
15. Radiograph showing new host bone



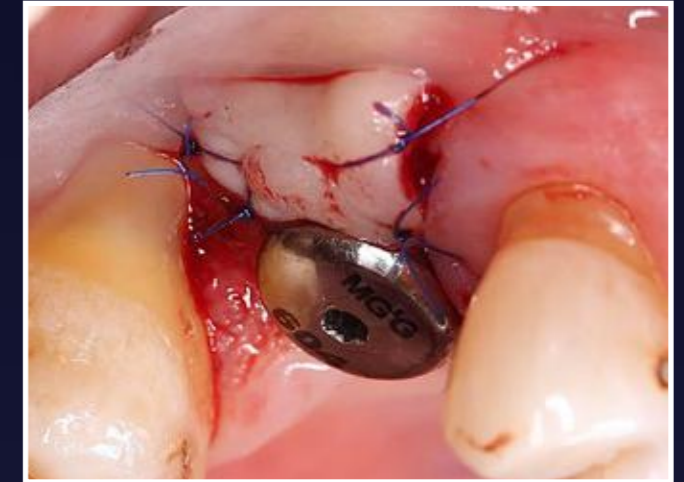
16. New host bone visible



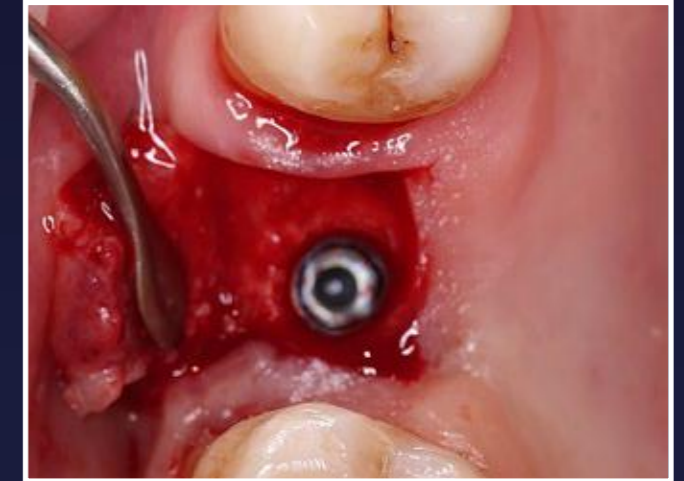17. AnyRidge 4x10 implant placed



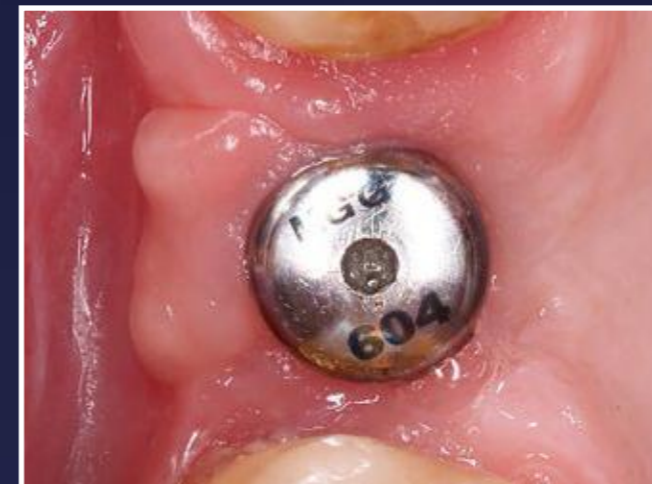19. Post-placement radiograph - also a small crestal lift with Densah burs



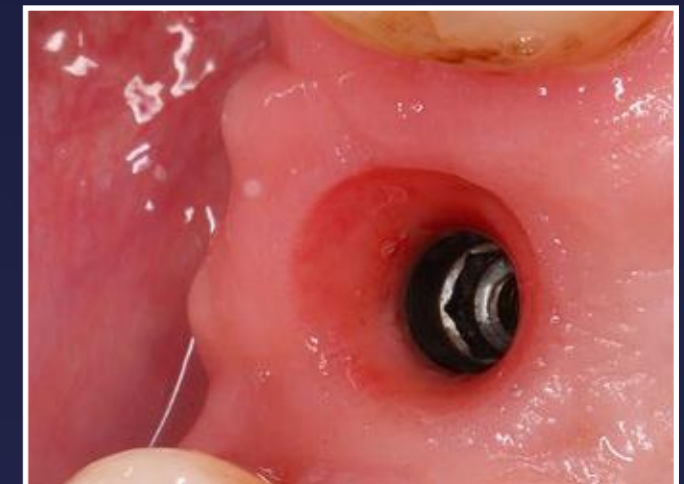18. Healing cap fitted and sutured closed



20. Another 7 months later

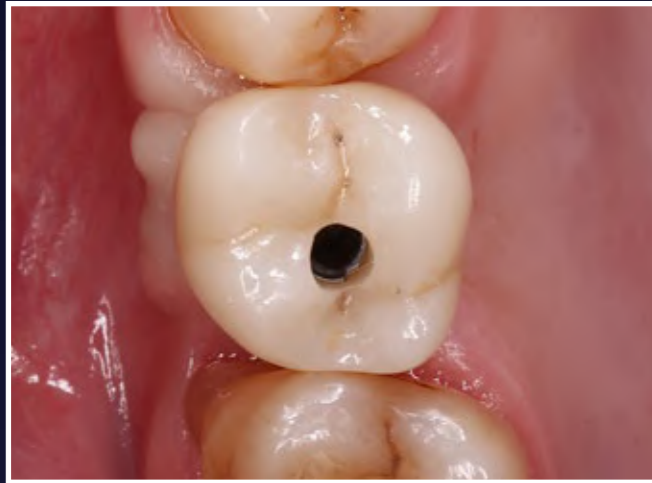


21. Tissue maturation before removing healing cap

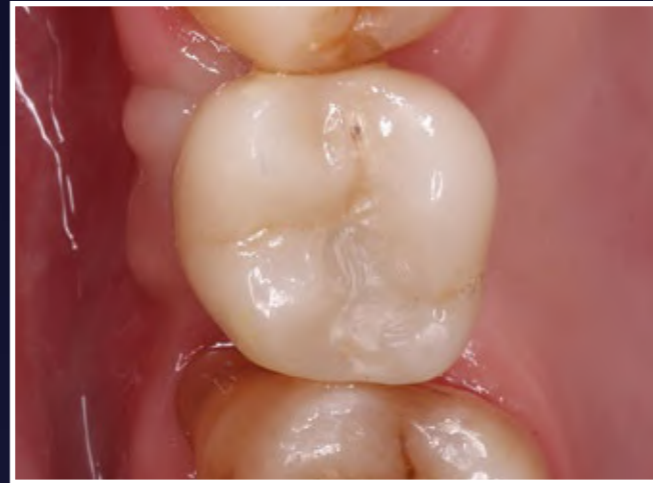

22. 3-4 mm of tissue height, as required. Everything is stable and feels solid

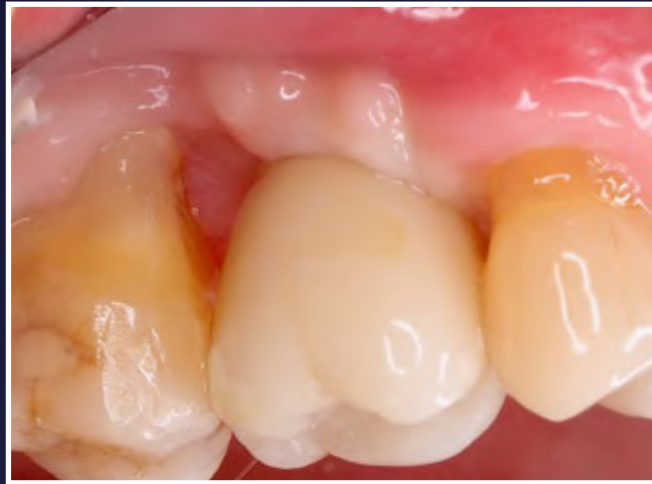Upper First Molar Socket Graft



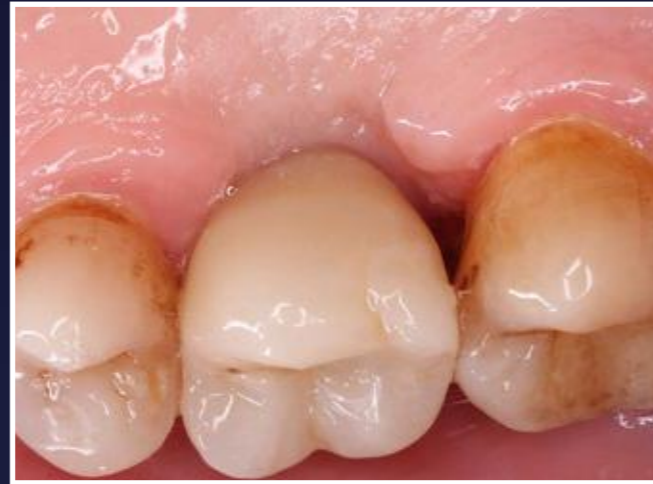23. Slight tissue blanching, only lasted for a couple of minutes



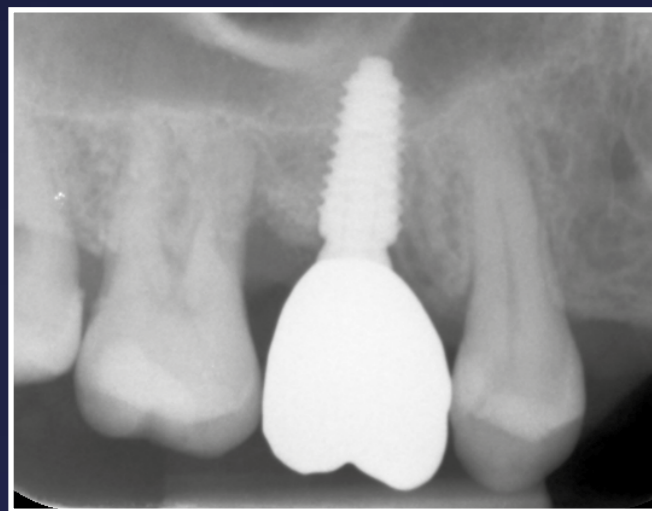
24. Teflon tape and composite to seal it



25. Distal part is cleanable, still 4mm probing depth for UR7



26. Palatal view



27. Final radiograph for this part of the treatment

GROW
CONFIDENT