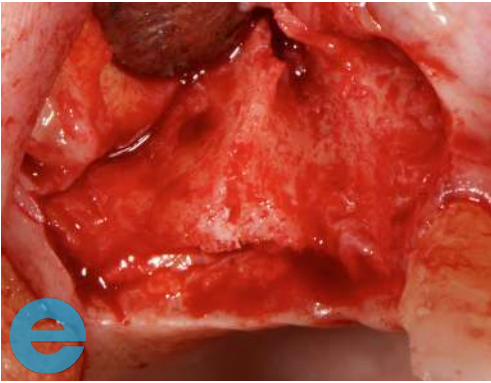
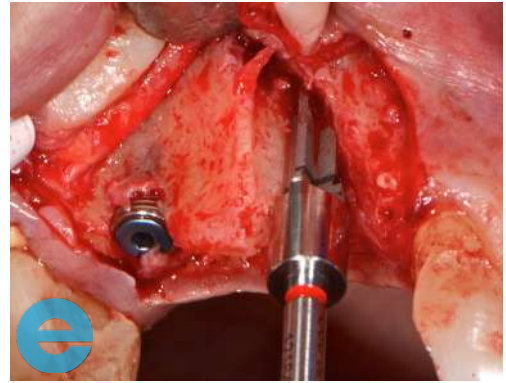


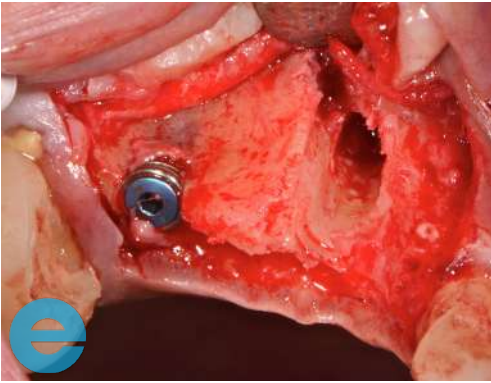
# UPPER PREMOLAR BRIDGE CASE STUDY



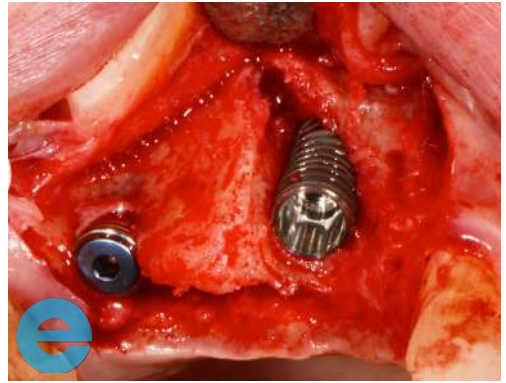
1. Buccal defect at the 13 area.



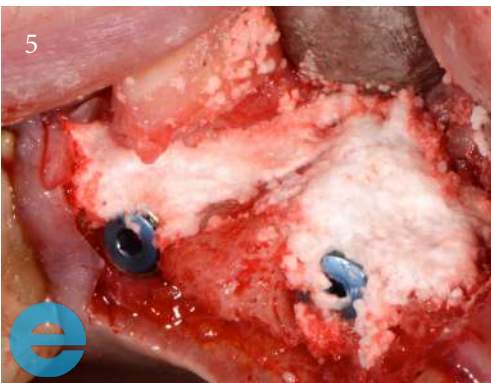
2. Angle placement drill.



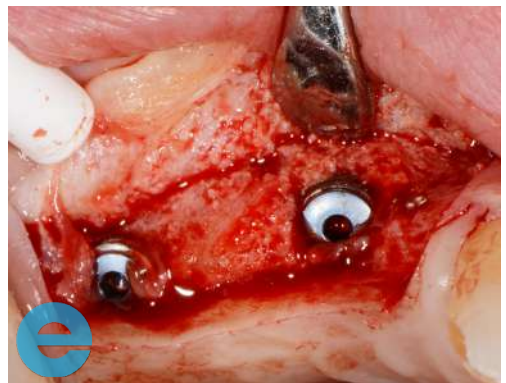
3. Angled osteotomy.



4. Implant placed.

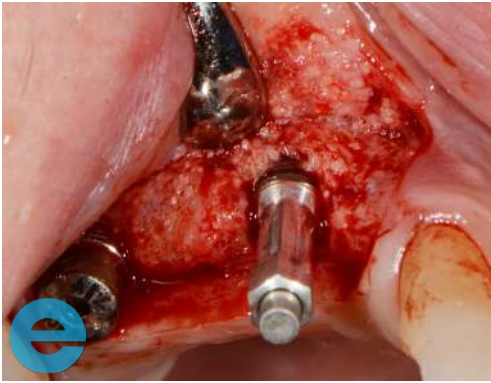


5. Grafted with EthOss®.

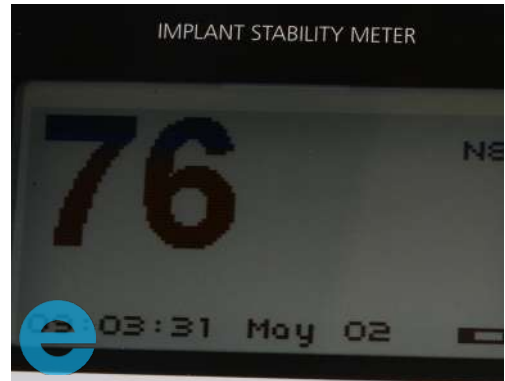

6. New bone at 13 weeks.

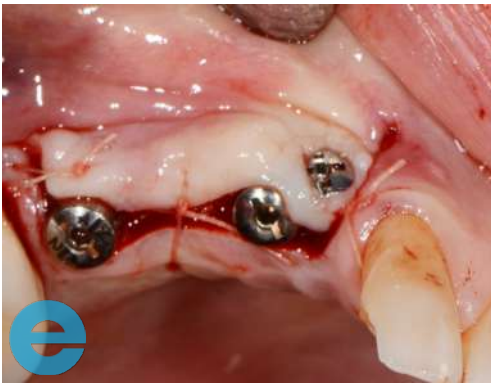# UPPER PREMOLAR BRIDGE CASE STUDY



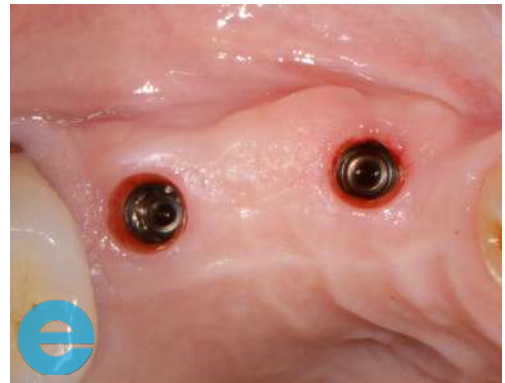7. Osstell peg.



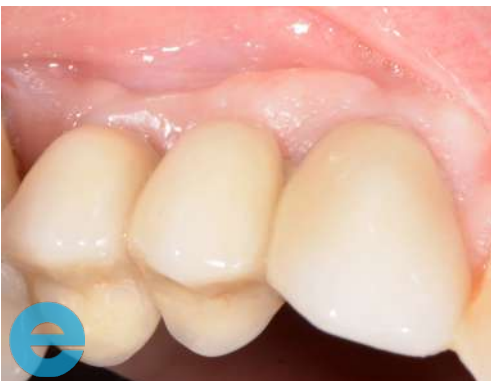8. Osstell reading of 76 ISQ.



9. Soft tissue screw tissue adjustment.



10. Impressions.



11. Loaded at 2 years.



# GROW STRONGER

## USEFUL RESOURCES

### RECOMMENDED CLINICAL PROTOCOL

*Clinical study showcasing recommended clinical protocol for EthOss*

Download

### SURGICAL GUIDELINES

*The official recommended guide on how to use EthOss*

Download

### HOW TO MIX ETHOSS

*Explainer video*

Watch