

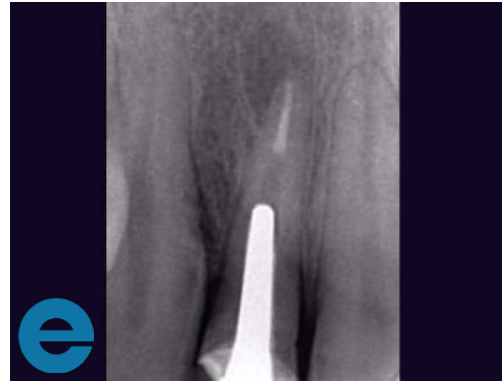UPPER RIGHT LATERAL INCISOR

Male, 34 years old, no other health concerns

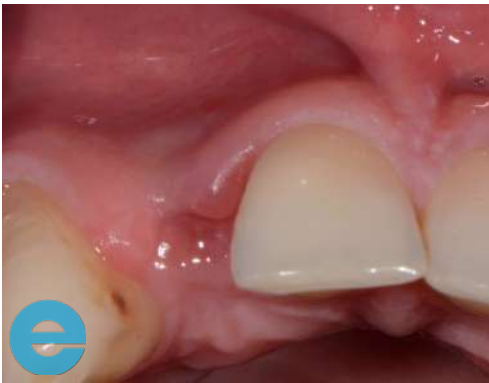Previous root fracture with associated bone loss

Treated according to standard protocol, extraction with 3-week healing period followed by simultaneous implant placement and graft

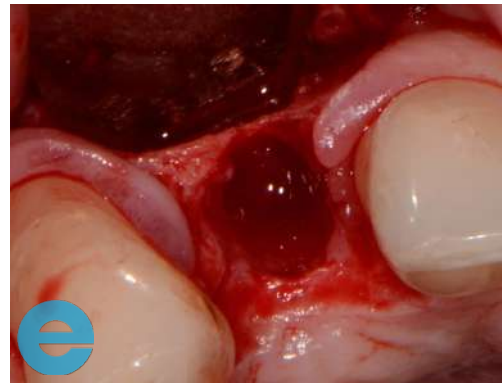
Case from Dr Peter Fairbairn



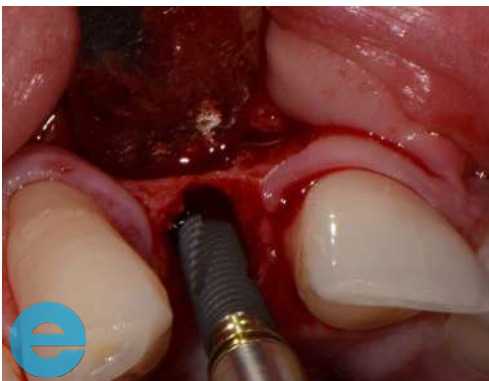1. Initial situation. Root fracture and bone loss at apical area



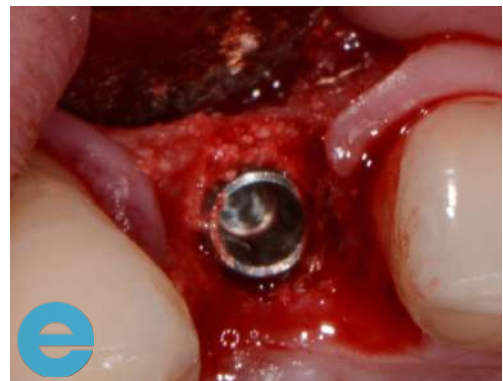2. 3 weeks post extraction, some papilla loss



3. Thin plate and bigger defect at apical area

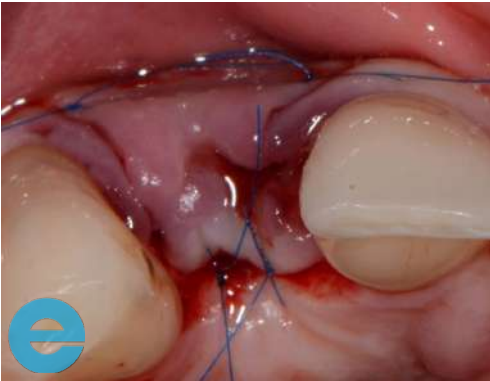


4. Osstem implant placed slightly palatally

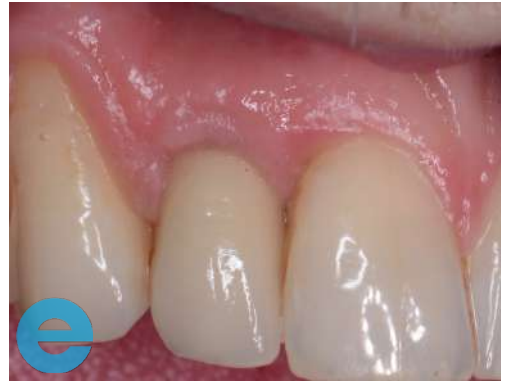

5. 'Wet' mix of EthOss placed palatally. Implant then placed followed by additional 'dry' mix buccally

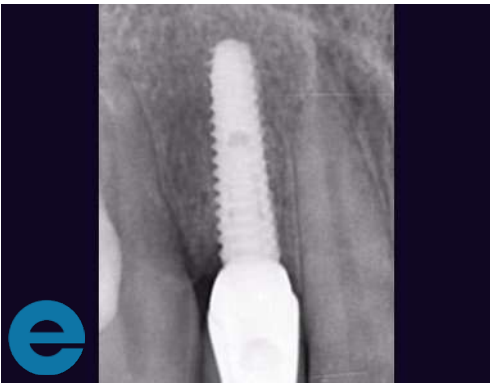UPPER RIGHT LATERAL INCISOR



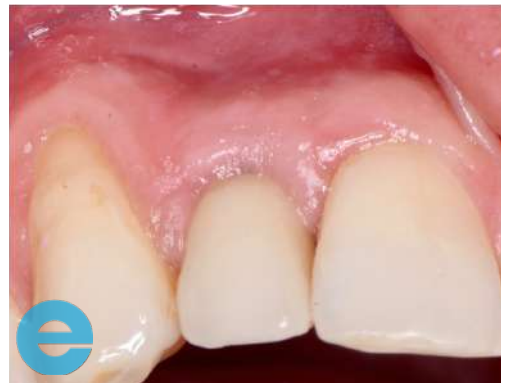6. Sutured closed



7. Loaded 3 years – nice tissue healing, although little inflammation due to loose abutment



8. Radiograph showing stable site



9. Loaded 3 years – note soft tissue healing and papilla recovery



GROW STRONGER[®]

USEFUL RESOURCES

RECOMMENDED CLINICAL PROTOCOL

Clinical study showcasing recommended clinical protocol for EthOss bone grafting material

[Download](#)

SURGICAL GUIDELINES

The official recommended guide on how to use EthOss bone grafting material

[Download](#)

HOW TO MIX ETHOSS BONE GRAFTING MATERIAL

Explainer video

[Watch](#)