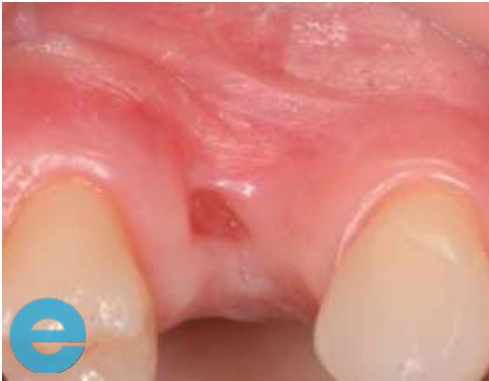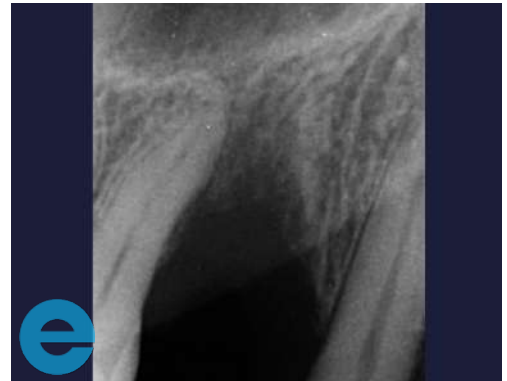


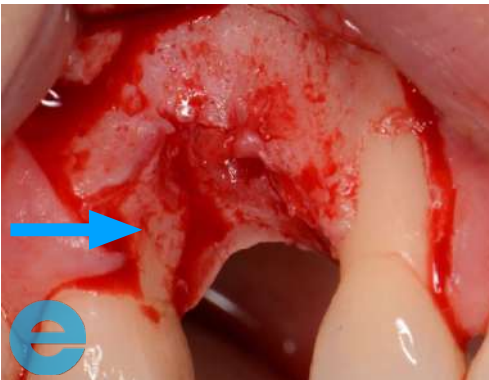
UPPER RIGHT PREMOLAR



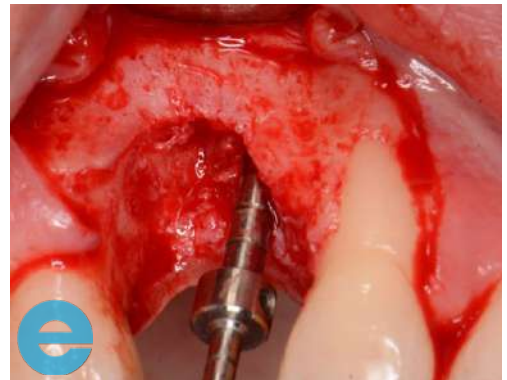1. Vertical and horizontal loss, hard and soft tissues



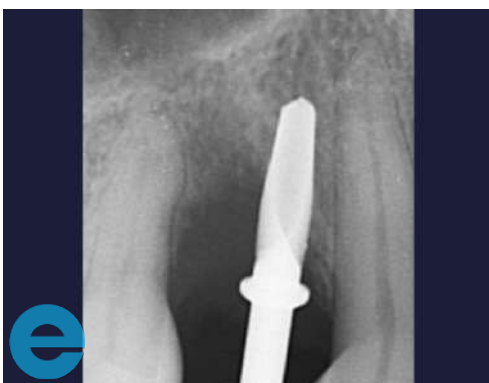2. Radiograph showing bone defect



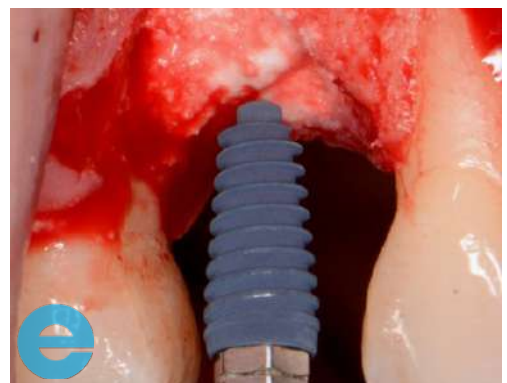3. Bigger flap required as we will also be restoring the defect on the medial of the second premolar as shown by arrow



4. Hard tissue loss on the palatal aspect - check the angle

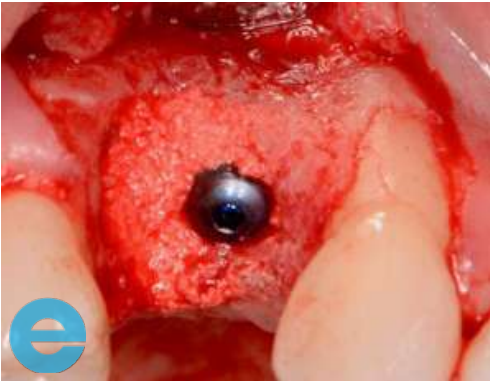


5. Radiograph showing hard tissue loss on the palatal aspect - check the angle

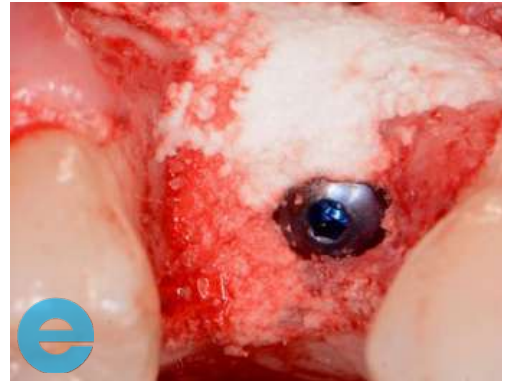


6. Palatal graft into the site and placement of 3.5 mm wide AnyRidge to the correct level (mm sub crestal)

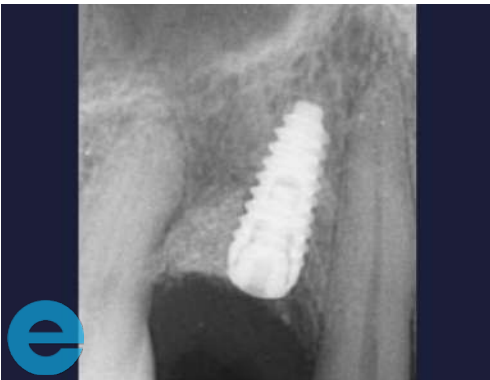UPPER RIGHT PREMOLAR



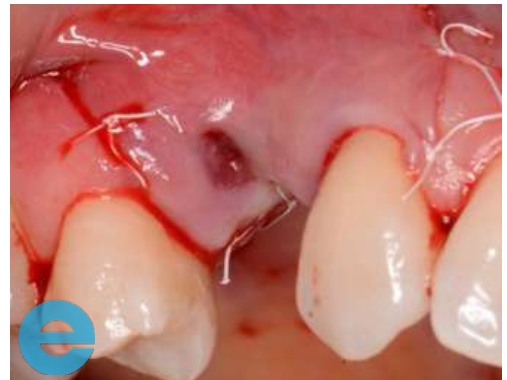7. Implant placed



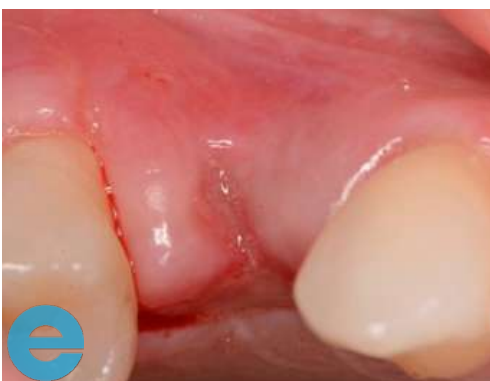8. Additional graft to the correct level and on the buccal aspect with drier mix of EthOss



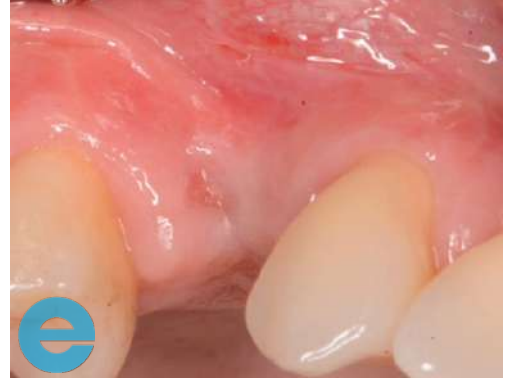9. Radiograph of implant placement



10. Passive closure using PTFE sutures. Small opening on palatal aspect

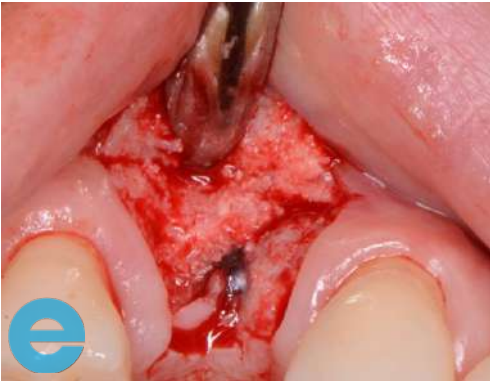

11. Sutures removed at 4 days - healing on the open palatal area by secondary intention

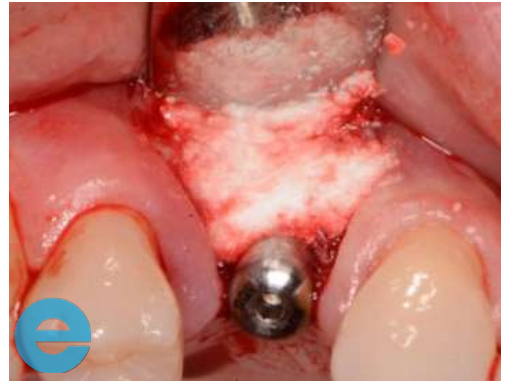

12. Healed site at 10 weeks

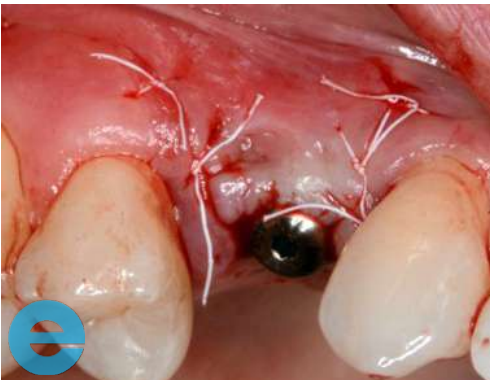UPPER RIGHT PREMOLAR



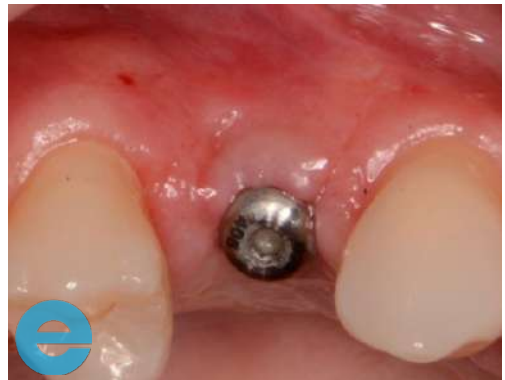13. Small additional graft with EthOss



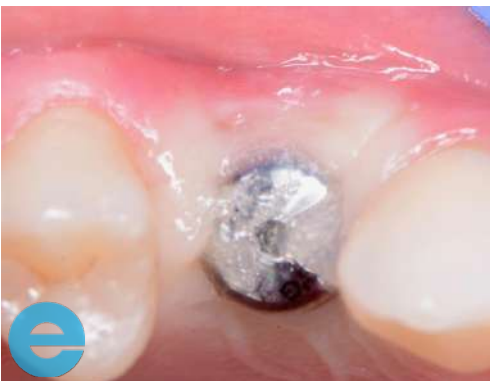14. Healing cap placed



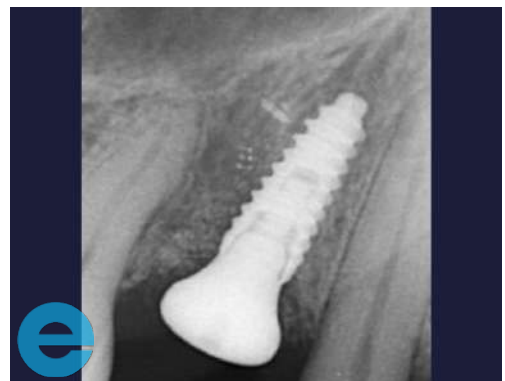15. Sutures removed again at 4 days



16. Bigger healing cap to improve emergence and Blue®M gel used for soft tissue healing

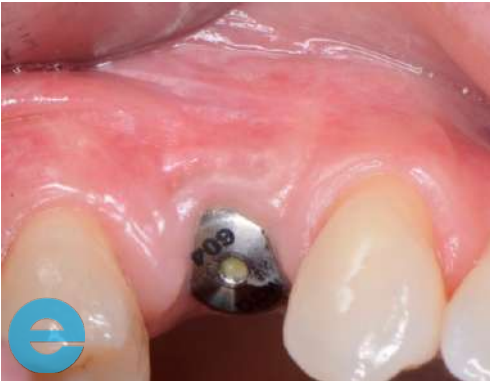


17. Radiograph showing restoration of bone on the distal premolar

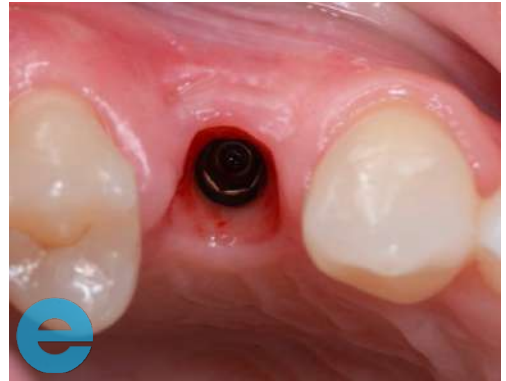

18. 2 weeks later

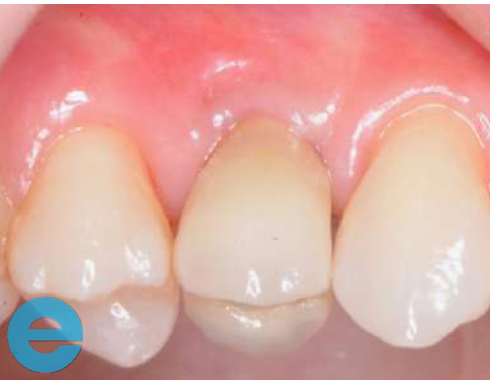UPPER RIGHT PREMOLAR



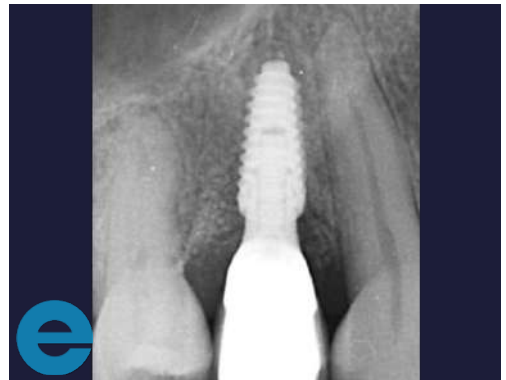19. 2 weeks later



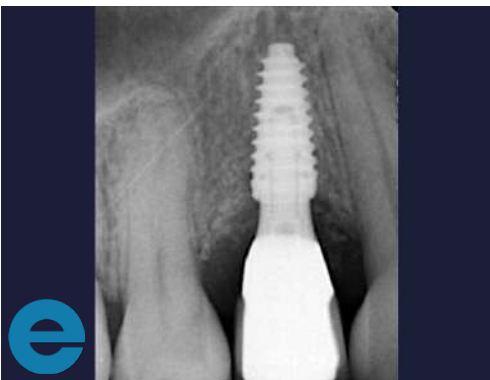20. Loaded at 14 weeks post surgery, restored papillae



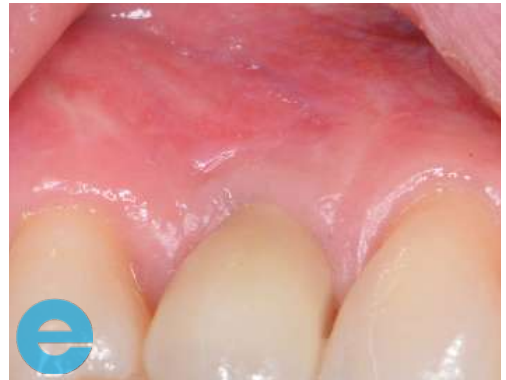21. Radiograph showing restored profile. This will improve with time and function



22. Loaded 6 months

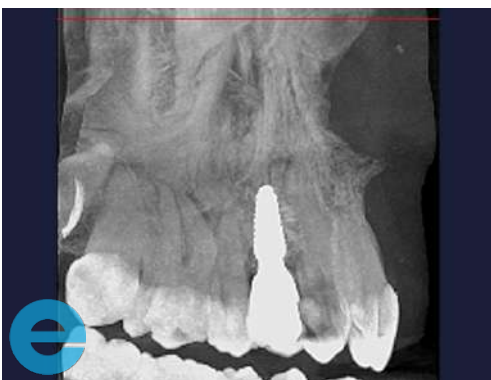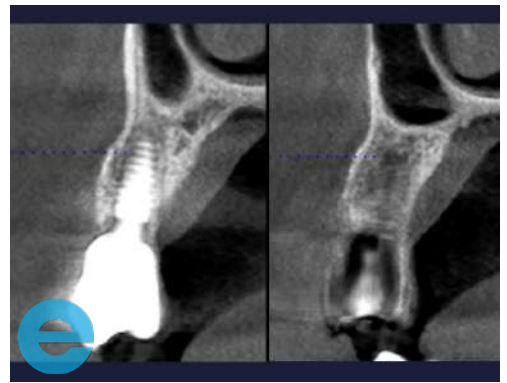
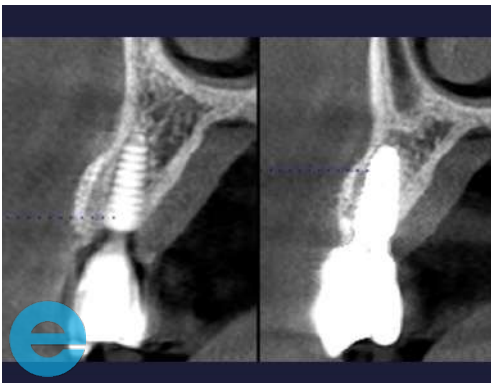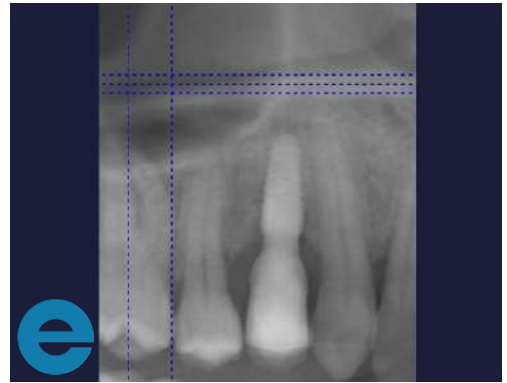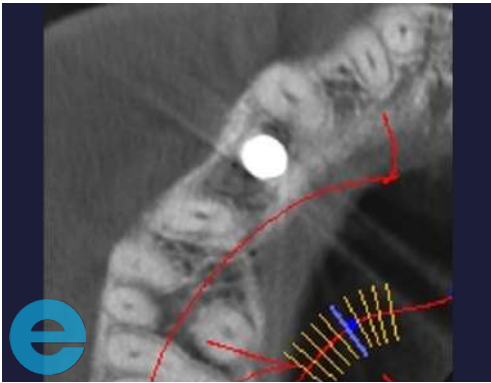


23. Loaded 6 months



UPPER RIGHT PREMOLAR

The following scans were taken at 9 months post op





GROW STRONGER

USEFUL RESOURCES

RECOMMENDED CLINICAL PROTOCOL

Clinical study showcasing recommended clinical protocol for EthOss

Download

SURGICAL GUIDELINES

The official recommended guide on how to use EthOss

Download

HOW TO MIX ETHOSS

Explainer video

Watch